

Catheter ablation of accessory pathway tachycardias in three patients with Ebstein's anomaly

Ebstein anomalisi olan üç olguda aksesuar yol taşikardisinin kateter ablasyonu

Mehmet Tugrul Inanc, M.D., Namik Kemal Eryol, M.D., Cemil Zencir, M.D.

Erciyes University, Faculty of Medicine, Department of Cardiology, Kayseri, Turkey

Ebstein's anomaly (EA) is a malformation of the tricuspid valve characterized by a downward displacement of the septal and often the posterior tricuspid valve leaflets to the atrialized right ventricle. Among all congenital anomalies EA is the most related anomaly with accessory pathways. In 5%-25% of patients with EA, accessory atrioventricular pathways may present on the surface electrocardiogram. Radiofrequency catheter ablation is the first-line treatment of EA patients with supraventricular tachyarrhythmias. The presence of a dysplastic tricuspid annulus and electrically distinguishable atrioventricular activity may complicate radiofrequency catheter ablation of accessory pathway tachycardia in these patients. We present three cases of EA in which accessory pathway tachycardias were successfully ablated, with emphasis on technical difficulties in electrophysiological diagnosis and during radiofrequency ablation.

Key words: Catheter ablation; Ebstein's anomaly/complications; electrophysiology; heart conduction system/abnormalities; tachycardia/etiology/therapy.

Ebstein's anomaly (EA) is the most related anomaly with accessory pathways among all congenital anomalies. The typical characteristic of EA is the downward displacement of the posterior tricuspid valve leaflets to the atrialized right ventricle. As a result, there is no evident tricuspid valve ring. Patients may be asymptomatic for a very long time during their life time, whereas there may also be symptomatic cases during the early stages of life from the findings of right heart failure due to tricuspid regurgitation. It may sometimes be accompanied by accessory conduction pathways with severe palpitation in the presence of other congenital anomalies (patent foramen ovale, atrial and ventricular septal de-

Ebstein anomalisi (EA) septal ve posteriyor triküspit kapakçıkların atriyalize olmuş sağ ventrikülün aşağısına doğru yerleşim göstermesidir. Doğuştan kalp anomalileri içinde aksesuar ileti yolları ile en sık ilişki gösteren anomalidir. Ebstein anomalili hastaların %5-25'inde yüzey elektrokardiyografisinde preeksitasyon saptanabilmektedir. Aksesuar yol bulunan EA'lı hastalarda supraventriküler taşikardi tedavisinde radyofrekans ablasyon ilk seçenek olarak uygulanmaktadır. Ancak, anatomik triküspit halkanın olmaması ve sadece elektriksel olarak ayrılabilen bir atriyoventriküler sınırın bulunması, aksesuar yol taşikardisi olan hastalarda elektrofizyolojik çalışmayı zorlaştıran bir durumdur. Bu yazıda, aksesuar yol taşikardisi için başarılı bir şekilde ablasyon uygulanan EA'lı üç hasta sunularak, tanısal elektrofizyolojik çalışma ve radyofrekans ablasyon tedavisi sırasında karşılaşılan güçlükler ele alındı.

Anahtar sözcükler: Kateter ablasyonu; Ebstein anomalisi/komplikasyon; elektrofizyoloji; kalp iletim sistemi/anormallik; taşikardi/etiyoloji/tedavi.

fects).^[1-3] Proximal atrioventricular tachycardia has been reported in 25-30% of patients with EA, and these supraventricular tachycardia episodes carry a risk of sudden death.^[4,5] The surface electrocardiogram (ECG) of these patients demonstrates a 5-25% rate of preexcitation. Radiofrequency ablation (RFA) is the first-line treatment of EA patients with supraventricular tachycardia.^[6] However, absence of an anatomic tricuspid ring and the presence of an atrioventricular border which can only be electrically distinguishable makes electrophysiology studies (EPS) very difficult in patients with accessory pathway tachycardias. In this paper, we present three cases of EA with symptomatic palpitation, who were diag-

Received: 07.06.2009; Accepted: 10.07.2009

Corresponding address: Dr. Mehmet Tugrul Inanc. Erciyes Üniversitesi Tıp Fakültesi, Kardiyoloji Anabilim Dalı, Talas Yolu, 38039 Kayseri, Tel: +90 – 352 – 437 49 37 / 27789, e-mail: mtinanc@msn.com

not retriggered by the test performed after ablation. The patient revisited our clinic at 3 months following discharge, due to repeated palpitations. The condition relapsed and EPS and RFA were rescheduled. RFA was performed again during tachycardia at the site previously detected with continuous activity. The patient was discharged following absence of repeated palpitations after the procedure. No palpitation episodes were reported during the 12-month follow-up period.

Case 2 – An 18-year-old man visited our emergency unit with complaints of palpitation. His ECG revealed right bundle branch block morphology and a wide-QRS tachycardia with a rate of 232 beats/min. The patient complained about experiencing similar palpitations for the past three months. Parenteral metoprolol and diltiazem were administered at the emergency unit to maintain sinus rhythm. The follow-up ECG demonstrated a short P-R interval, positive wave in the anterolateral leads, and a negative delta wave in the inferior leads. The transthoracic echocardiography demonstrated a tricuspid valve which was situated inferior to the level of the mitral valve, consistent with EA. A left-to-right atrial shunt was identified on color Doppler analysis. On the other hand, a patent foramen ovale was identified by transesophageal echocardiography at this site. The patient was referred to the cardiovascular surgery unit with the diagnosis of EA and patent foramen ovale. During surgery the patent foramen ovale was closed using the patching technique, right ventricular placcation was performed at the atrialized segment, and the tricuspid valve repaired. However, the accessory pathway could not be interrupted by surgery. The patient was scheduled for EPS due to persistent palpitation after surgery. Analysis of the patient's ECG which was performed before the EPS demonstrated a right ventricular posteroseptal localization of the accessory pathway. As a result, the ablation catheter was implanted directly in the atrioventricular ring of the tricuspid valve. Following a programmed stimulation from the right atrium, a wide-QRS supraventricular tachycardia with a cycle length of 266 ms (225 beats/min) and with right bundle branch morphology was triggered. Right ventricular pacing with entrainment and atrial advancement tests were found to be positive during tachycardia. After reverting the tachycardia to sinus rhythm by overdrive pacing, a RFA was performed at the point situated in the posteroseptal region and at the distal end from where continuous activity was observed, using a 7F ablation catheter with a 4-mm tip (Mariner RF). Continuous activity and the delta wave of surface ECG disappeared within a short period of time during ablation (Figure 2). A second tachycardia focus was not identified after the procedure following programmed stimulation from the atrium. Retrograde conduction from the ventricle to the atri-

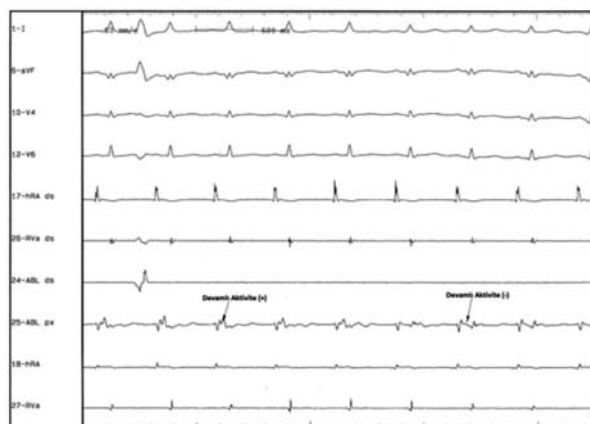


Figure 2. Termination of continuous activity and marked disappearance of the delta wave in lead D1 in the patient with visible accessory pathway during sinus rhythm.

um was observed to have disappeared. No other symptom was reported during the 13-month follow-up period.

Case 3 – A 58-year-old man presented with complaints of dyspnea and repeated palpitation. There was no related abnormality in his past and family medical histories. His blood pressure was 135/85 mmHg and the heart rate was 84 beats/min. cardiac auscultation revealed a rhythmic heart rate and a 3/6 systolic murmur. A normal sinus rhythm was observed on the ECG, with a right bundle branch block and right atrial hypertrophy. The transthoracic echocardiography demonstrated the tricuspid valve situated to the right, and a dilated and partially atrialized right ventricle, consistent with EA. A moderate tricuspid regurgitation was detected, with a pulmonary artery pressure measured as 40 mmHg. An EPS was scheduled for his palpitation. A narrow-QRS tachycardia with a cycle length of 321 ms (approx. 187 beats/min) was triggered by a programmed stimulation from the right atrium of 500, 280, 280 ms intervals, and the VA conduction interval was recorded as 175 ms. A 6F multipolar coronary sinus catheter (Bard Electrophysiology) was implanted in the coronary sinus for diagnostic purposes. The closest VA interval indicating continuous activity in these recordings was found to be on the right ventricular side. The atrial advancement and ventricular entrainment tests were found to be positive during tachycardia, and a diagnosis of AVRT associated with accessory pathway was considered. A 7F ablation catheter with a 4-mm tip (Mariner RF) was implanted in the right ventricular apex and retrieved backwardly. The continuous activity focus was then investigated. Presence of continuous activity was investigated on the posterior wall since no continuous activity observed at the septal and anterolateral wall. Despite the absence

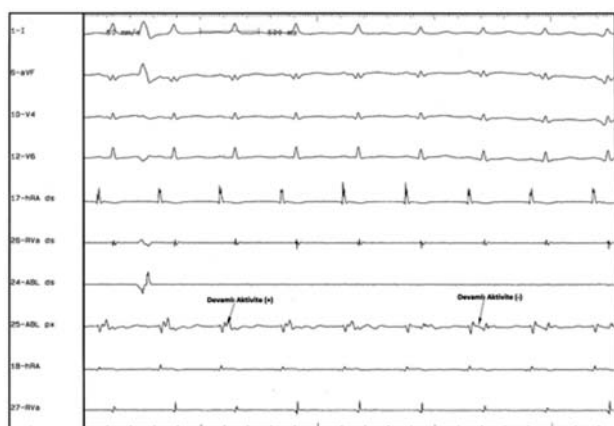


Figure 3. Observation of the ablation moment from the continuous activity focus identified at the right posteroseptal region.

of continuous activity on the posterior wall, however, the high motility of the posterior and septal leaflets and its inferior localization prevented adequate stability of the catheter tip location. Attempts were made to bring the catheter to the highest flexion position to increase tissue contact, after which the ablation procedure was initiated (Figure 3). However, the accessory pathway did not easily burn away during the procedure and reoccurred within seconds. The accessory pathway was observed to burn away successfully after repeated ablation. No retrograde conduction was observed during the follow-up test and the tachycardia was not retriggered. The patient was reported to be asymptomatic during the 12-month follow-up period.

DISCUSSION

Ebstein's anomaly was described by Wilhelm Ebstein in 1866, after an autopsy procedure.^[7] The septal and posterior tricuspid valve leaflets of this anomaly are more apically situated than the mitral valve leaflets. This condition causes atrialization of the right ventricle. Diagnosis can be made during echocardiographic evaluation in the apical four chamber view by directly according to the distance between the mitral and tricuspid rings or by dividing the distance between the mitral and tricuspid rings by the body surface area. These values are reported to be 20 mm or 8 mm/m² in adults. Etiologic factors include genetic, environmental and maternal use of lithium.

Atrial septal defect, ventricular septal defect, patent ductus arteriosus, bicuspid aorta, coarctation of the aorta, subaortic stenosis, pulmonary atresia, hypoplastic pulmonary artery, right ventricular outflow obstruction, mitral valve prolapse, noncompaction-like dysplastic changes in the left ventricle may be observed in patients with Ebstein's anomaly.^[1] Clinical

findings vary according to the accompanying congenital anomalies and the presence of an accessory conduction pathway. Patients may be asymptomatic; however, patients may present with symptoms such as syncope, cyanosis, paradoxical embolus, and findings of heart failure. Sudden death may also be observed. These disease states should be surgically treated.^[8]

Palpitation is a very important symptom which may be observed in these patients. All types of atrial and ventricular tachycardias may be observed. This condition may lead to decompensation and hypoxia in patients with heart failure. It may further exacerbate hypoxia, leading to sudden death in patients with atrioventricular shunts, through increasing left to right shunt by tachycardia.^[4] All of our patients presented with severe tachycardia. Patent foramen ovale was observed together with EA in our second case during echocardiographic evaluation and was surgically repaired. On the other hand, no symptoms of cardiac decompensation were reported during tachycardia.

Tachycardias of atrial and ventricular origin are usually caused by right atrial and ventricular dilatation. However, concomitant accessory conduction pathways also play a very important role. Accessory pathways or Mahaim type atriofascicular connections are encountered in at least 50% of patients with Ebstein's anomaly. The tricuspid valve leaflet is apically situated in patients with Ebstein's anomaly, with a disorganized integrity of fibrous skeleton at its normal location. This condition may lead to direct connection of the atrioventricular conduction system to the ventricular muscular structures, with consequent formation of a background for the development of accessory pathways and preexcitation.^[9,10] More than one accessory pathway may be observed in patients with Ebstein's anomaly and these are mostly situated around the tricuspid ring.^[11,12] Right posteroseptal invisible accessory pathways were found in two of our cases, whereas a right posteroseptal visible accessory pathway was observed in one of our patients.

RFA is currently the first-line treatment choice in patients with AVRT.^[6] However, surgical interruption of the accessory pathway is also possible in patients scheduled for surgical repair. The success rate is reported to be high and the mortality and morbidity rate are low in patients with symptomatic reentry tachycardia who undergo surgical ablation.^[13-15] Elimination of the accessory pathway by surgical intervention should also be considered in patients who underwent unsuccessful catheter ablation or in cases of recurrence. However, the accessory pathway to be eliminated should be identified by EPS prior to the surgical procedure.

Consequently, the accessory pathway can also easily be treated while performing surgical repair of the tricuspid valve and surrounding structures. Repeated supraventricular episodes may be observed during the postoperative period in association with increased catecholamine levels when the accessory pathway cannot be eliminated during the surgical procedure. This is another factor which increases postoperative morbidity and mortality.

Treatment with radiofrequency ablation is frequently used in patients with concomitant EA and Wolff-Parkinson-White syndrome. However, anatomic changes observed with the disease decrease the success of the procedure and increased the risk of complications. The success rate of catheter ablation for accessory pathway is reported to be approximately 80-85%. This result is relatively low compared to accessory pathway diseases with no structural heart disease background. On the other hand, the recurrence rate following ablation in patients with EA is reported to be 25%, a result similar to our first case.^[6] On the other hand, the atrioventricular conduction system is situated posteriorly and very close to the entrance of the coronary sinus, in patients with primum-type ASD. As a result, care should be taken and unnecessary ablation should be avoided due to the high risk of atrioventricular block of various degrees during RFA.^[16] This risk can be reduced by using cryoablation. Not even a first degree atrioventricular block was reported during RFA or later during follow-up in any of the cases presented. Dincal et al.^[17] successfully treated a 16-year-old patient with EA associated with orthodromic and antidromic supraventricular tachycardia and right-sided posteroseptal visible accessory pathway, using RFA and reported no complications.

It is not technically easy to penetrate the accessory pathway which causes tachycardia by ablation catheter in patients who undergo surgical repair and are scheduled for RFA. We observed difficulties when trying to penetrate the accessory pathway of our second patient who underwent surgical repair and concerning ablation of the region, due to the younger age of this patient, the fact that heart chambers were not yet enlarged, and also due to demonstration of a visible accessory pathway during sinus rhythm. Factors complicating catheter manipulation and reducing the success rate in patients who do not undergo surgery include absence of an anatomical tricuspid ring, dilated right heart chambers, together with a visible tricuspid regurgitation. As a result, attention should be placed more on the electrical atrioventricular ring rather than on the anatomical approach for mapping of accessory path-

ways. Factors which further complicate the ablation procedure include recording of multi-electrode low amplitude electrocardiography in the right atrium and atrialized ventricle, and the presence of more than one accessory pathway.^[18] Under such conditions, attention should be placed on the shortest atrioventricular or ventriculoatrial conduction intervals, and on the earliest retrograde and antegrade activities, when performing RFA during rest or during tachycardia.^[19] On the other hand, implantation of a multi-electrode deflatable catheter in the tricuspid ring would facilitate penetration of the accessory pathway, due to the difficulty of mapping the accessory pathway in the course of diagnosis.

On the other hand, stability of the ablation catheter would increase success rate in patients with tachycardias associated with invisible accessory pathways, since ablation would be performed during tachycardia and since treatment would involve a tricuspid ring with dilated and difficult implantable catheter, as in cases with EA. Therefore, long sheaths should be used. Success criteria for the termination of tachycardia during ablation include disappearance of continuous activity and retrograde conduction of the delta wave and intracardiac recordings on surface ECG. Repeated ablation may be necessary in patients who experience recurrence during the procedure. A long sheath was not used during the ablation procedure in our third case. As a result adequate stability of the catheter was not achieved. This led to recurrence and repeated ablations within minutes.

In conclusion, some patients with EA may experience life possible threatening supraventricular tachycardia episodes associated with accessory conduction pathways. Diagnosis is facilitated by echocardiography and electrocardiography in such cases. Despite difficulties in identifying localization of the accessory pathway associated with displacement of the right atrium, right ventricle and tricuspid ring during electrophysiology studies, successful ablation may be possible by looking patiently for the accessory pathway and attaining a stable catheter position at the continuous activity focus.

REFERENCES

1. Attenhofer Jost CH, Connolly HM, Edwards WD, Hayes D, Warnes CA, Danielson GK. Ebstein's anomaly - review of a multifaceted congenital cardiac condition. *Swiss Med Wkly* 2005;135:269-81.
2. Danielson GK, Driscoll DJ, Mair DD, Warnes CA, Oliver WC Jr. Operative treatment of Ebstein's anomaly. *J Thorac Cardiovasc Surg* 1992;104:1195-202.

3. Brickner ME, Hillis LD, Lange RA. Congenital heart disease in adults. Second of two parts. *N Engl J Med* 2000; 342:334-42.
4. Rossi L, Thiene G. Mild Ebstein's anomaly associated with supraventricular tachycardia and sudden death: clinicomorphologic features in 3 patients. *Am J Cardiol* 1984;53:332-4.
5. Kastor JA, Goldreyer BN, Josephson ME, Perloff JK, Scharf DL, Manchester JH, et al. Electrophysiologic characteristics of Ebstein's anomaly of the tricuspid valve. *Circulation* 1975;52:987-95.
6. Cappato R, Schlüter M, Weiss C, Antz M, Koschyk DH, Hofmann T, et al. Radiofrequency current catheter ablation of accessory atrioventricular pathways in Ebstein's anomaly. *Circulation* 1996;94:376-83.
7. Mann RJ, Lie JT. The life story of Wilhelm Ebstein (1836-1912) and his almost overlooked description of a congenital heart disease. *Mayo Clin Proc* 1979; 54:197-204.
8. Celermajer DS, Bull C, Till JA, Cullen S, Vassilikos VP, Sullivan ID, et al. Ebstein's anomaly: presentation and outcome from fetus to adult. *J Am Coll Cardiol* 1994; 23:170-6.
9. Frescura C, Angelini A, Daliento L, Thiene G. Morphological aspects of Ebstein's anomaly in adults. *Thorac Cardiovasc Surg* 2000;48:203-8.
10. Edwards WD. Embryology and pathologic features of Ebstein's anomaly. *Prog Pediatr Cardiol* 1993;2:5-15.
11. Smith WM, Gallagher JJ, Kerr CR, Sealy WC, Kasell JH, Benson DW Jr, et al. The electrophysiologic basis and management of symptomatic recurrent tachycardia in patients with Ebstein's anomaly of the tricuspid valve. *Am J Cardiol* 1982;49:1223-34.
12. Reich JD, Auld D, Hulse E, Sullivan K, Campbell R. The pediatric Radiofrequency Ablation Registry's experience with Ebstein's anomaly. *Pediatric Electrophysiology Society. J Cardiovasc Electrophysiol* 1998;9:1370-7.
13. Pressley JC, Wharton JM, Tang AS, Lowe JE, Gallagher JJ, Prystowsky EN. Effect of Ebstein's anomaly on short and long-term outcome of surgically treated patients with Wolff-Parkinson-White syndrome. *Circulation* 1992;86:1147-55.
14. Misaki T, Watanabe G, Iwa T, Watanabe Y, Mukai K, Takahashi M, et al. Surgical treatment of patients with Wolff-Parkinson-White syndrome and associated Ebstein's anomaly. *J Thorac Cardiovasc Surg* 1995; 110:1702-7.
15. Lazorishinets VV, Glagola MD, Stychinsky AS, Rudenko MN, Knyshev GV. Surgical treatment of Wolff-Parkinson-White syndrome during plastic operations in patients with Ebstein's anomaly. *Eur J Cardiothorac Surg* 2000;18:487-90.
16. van Hare GF. Radiofrequency ablation of accessory pathways associated with congenital heart disease. *Pacing Clin Electrophysiol* 1997;20:2077-81.
17. Dinçkal MH, Davutoğlu V, Soyduñ S, Sezen Y. Radiofrequency current catheter ablation of accessory pathway in Ebstein's anomaly and a review of the literature. *Türk Kardiyol Dern Arş* 2003;31:239-43.
18. Chugh A, Bogun F, Morady F. Catheter ablation of accessory pathways. In: Wilber DJ, Packer DL, Stevenson WG. *Catheter ablation of cardiac arrhythmias: basic concepts and clinical applications*. 3rd ed. New York: Blackwell Futura; 2008. p. 149-72.
19. Krahn AD, Klein GJ, Guiraudon G, Yee R. Ablation of posteroseptal pathways. In: Singer I, editor. *Interventional electrophysiology*. Maryland: Lippincott Williams & Wilkins; 1997. p. 207-51.