

CASE REPORT

Kounis syndrome: a paradoxal non-ST - elevation myocardial infarction case observed after triamcinolone treatment

Kounis sendromu: Triamsinolon tedavisi sonrası gözlenen paradoksal bir ST-yükselmesiz miyokart enfarktüsü olgusu

Mücahid Yılmaz, M.D.,¹ Hasan Korkmaz, M.D.²

¹Department of Cardiology, Elazığ Training and Research Hospital, Elazığ, Turkey

²Department of Cardiology, Fırat University Faculty of Medicine, Elazığ, Turkey

Summary–Kounis syndrome is defined as the clinical development of acute coronary syndrome caused by the activation of inflammatory cells due to an allergy, hypersensitivity, anaphylaxis, or anaphylactic reaction. Corticosteroids that are used in the treatment of many inflammatory conditions may paradoxically cause allergic reactions and even anaphylaxis. This article is a description of the case of a 52-year-old female patient who had a non-ST elevation myocardial infarction after the administration of triamcinolone that was relieved with antihistaminic treatment. The patient had been diagnosed with dermatitis at another medical center and injected with 40 mg/mL (intramuscular [IM]) of triamcinolone acetate and developed chest pain 15 minutes after the first dose. Despite a normal physical examination and echocardiogram, laboratory tests revealed troponin positivity and an inferolateral ST depression was present on an electrocardiogram (ECG). The ECG findings and clinical symptoms resolved completely after conservative anti-ischemic treatment and antihistaminic therapy (pheniramine maleate 45.5 mg/2 mL, Avil ampoule, IV; Sanofi-Aventis, Paris, France) and coronary angiography evaluation of the arteries was normal. The heart, and in particular the coronary arteries, are among the organs that are most damaged during hypersensitivity reactions and anaphylaxis. Although Kounis syndrome is not a rare condition, few cases have been reported in clinical practice. The failure to recognize Kounis syndrome due to inadequately defined cases may lead to unwanted medical results. Kounis syndrome should be kept in mind in order to make a rapid and accurate diagnosis.

Özet– Kounis sendromu allerji, aşırı duyarlılık, anafilaksi veya anafilaktik reaksiyonlar gibi durumlarda enflamatuvar hücrelerin aktivasyonu sonucu akut koroner sendrom tablosunun görülmesi olarak tanımlanır. Birçok enflamatuvar durumun tedavisinde kullanılan kortikosteroidler paradoksal olarak allerjik reaksiyonlara hatta anafilaksiye sebep olabilirler. Bu yazıda triamsinolon kullanımı sonrası ST yükselmesiz miyokart enfarktüsü meydana gelen ve antihistaminik tedavi ile düzelen 52 yaşında bir kadın hasta sunuldu. Başka bir merkezde dermatit tanısıyla, triamsinolon asetonid 40 mg/ml (im) enjekte edilen ve tedavinin ilk dozundan yaklaşık 15 dakika sonra göğüs ağrısı başlayan hastanın fizik muayanesi ve transtorasik ekokardiyografisi (EKO) normal olmasına karşın laboratuvar incelemelerinde troponin pozitifliği ve EKG’inde (elektrokardiyografi) inferolateral derivasyonlarda ST çökmesi mevcuttu. Konservatif amaçlı antiiskemik tedavi başlanıp antihistaminik (45.5 mg/2 mL i.v, feniramin maleat -Avil amp-) tedavi uygulandıktan sonra EKG bulguları ve kliniği tamamen düzelen olguya yapılan koroner anjiyografide koroner arterler normal olarak değerlendirildi. Kalp - özellikle koroner arterler- aşırı duyarlılık reaksiyonları ve anafilaksiye en fazla hasar gören organlardan biridir. Bu nedenle Kounis sendromu nadir görülen bir durum değildir; ancak klinik pratikte oldukça az sayıda gözlemlendiği bildirilmektedir. Doğru tanımlanamayan olgular nedeni ile Kounis sendromunun atlanması, istenmeyen tıbbi sonuçlara yol açabilir. Hızlı ve doğru teşhis için Kounis sendromu akılda tutulmalıdır.

As is known in cases of hypersensitivity including allergy or anaphylaxis/anaphylactic reaction, acute cardiovascular events related to activation

of mast cells may be experienced. In the year 1991, Kounis and Zarvas^[1] published a case with chest pain developed after an allergic reaction with the concept

Received: March 13, 2017 Accepted: October 02, 2017

Correspondence: Dr. Mücahid Yılmaz. Elazığ Eğitim ve Araştırma Hastanesi, Kardiyoloji Kliniği, Elazığ, Turkey.

Tel: +90 424 - 238 10 00 e-mail: mucahid.yilmaz@myynet.com

© 2018 Turkish Society of Cardiology



of “allergic angina., and in the year 1995, Constantinides reported that even allergic reactions may induce plaque rupture, and myocardial infarction (MI).^[2] In the year 1998, Braunwald^[3] continued this debate further, and pointed out that histamine, and leukotriene discharge observed during allergic reactions may effect vascular smooth muscles of coronary arteries.

Abbreviations:

CAG Coronary angiography
ECG Electrocardiography
ECHO Echocardiography
MI Myocardial infarction

Three types of the disease are known. Type 1 refers to occurrence of coronary spasms following allergic reactions in patients without cardiac risk factors (if it does not last longer, cardiac enzyme, and troponin levels may be within normal limits). In Type 2, allergic reaction developing on the background of the preexisting atheromatous plaque erodes or ruptures the plaque leading to acute myocardial infarction. Type 3 is defined as stent thrombosis infiltrated by eosinophils or mast cells.^[4,5] Corticosteroids, and antihistaminics resolve the vasospasm, and a clinical response can be obtained.

In this article a case of Kounis syndrome (non-ST-elevation MI) developed after use of a corticosteroid namely triamcinolone was presented.

CASE REPORT

A 52-year-old female patient who consulted emergency clinic of another hospital because of angina was referred to cardiology clinic of our hospital with the diagnosis of non-ST -elevation MI. The patient whose family history was unremarkable consulted a dermatology clinic with rashes, and itching of her scalp. As a result of evaluation by a dermatologist, she was prescribed 40 mg/ml IM doses of triamcinolone acetone (Kenacort-A Retard IM ampule). Nearly 15 minutes after the first dose of the treatment she consulted emergency clinic with complaint of severe retrosternal chest pain, and she was referred to our hospital upon detection of prominent ST depression on her electrocardiogram (ECG) at DII, DIII, aVF, and V3-V6 leads. Severity of her pain decreased greatly on her first evaluation in the emergency service, however variations on her EKG still persisted (Fig. 1).

Laboratory values of the patient with normal physical examination, and echocardiographic findings apart from troponin positivity (TnI: 0.98 ng/mL).

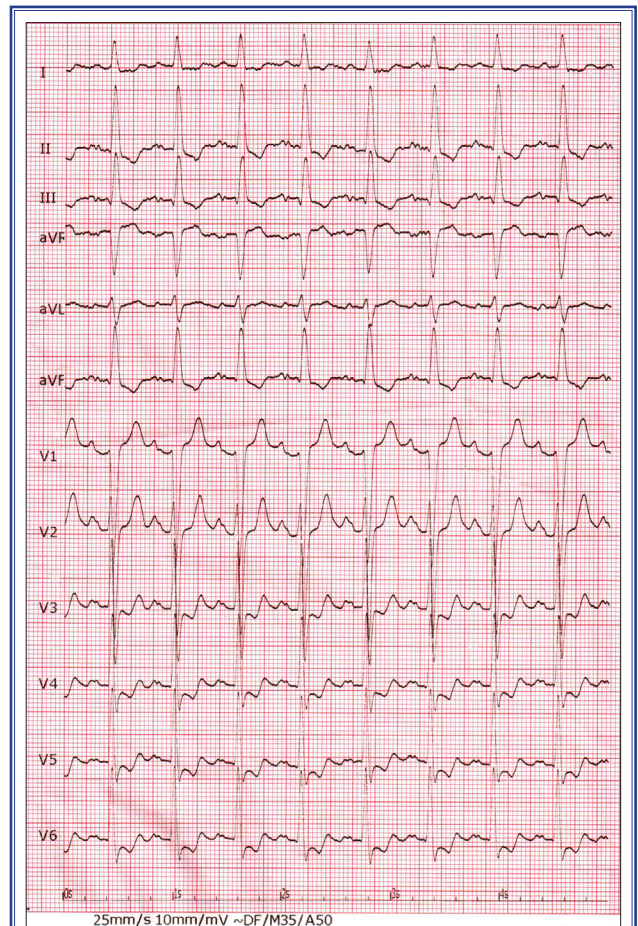
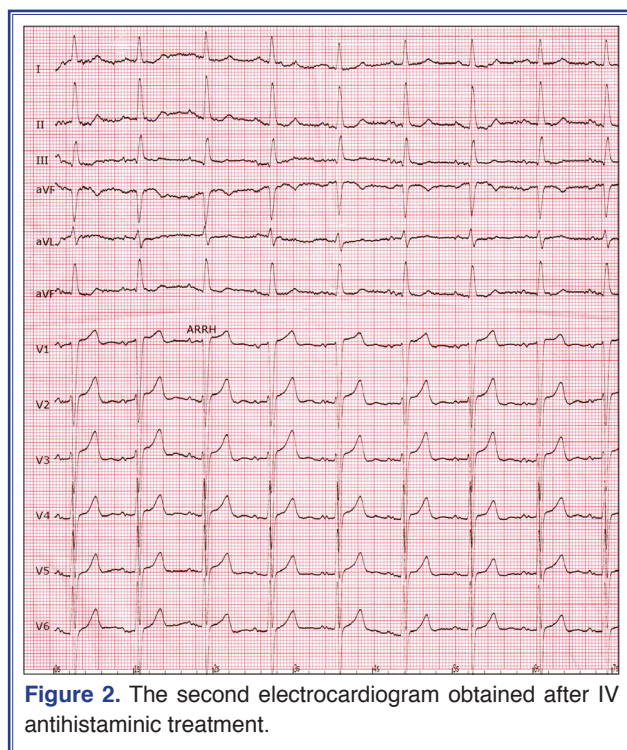


Figure 1. The first electrocardiogram of the patient obtained at her admission

Since pain of the patient started following intramuscular treatment with triamcinolone, we suspected of allergic vasospasm, so one ampoule of IV antihistaminic (pheniramine maleate 45. 5 mg/2 mL, Avil amp) was injected. Though pain of the patient was completely resolved, and her ECG findings of the patient normalized, anti-ischemic treatment was started, and she was brought in coronary angiography laboratory (CAG) On CAG, coronary arteries were normal (Figs. 2 and 3). Despite inability to perform necessary diagnostic laboratory tests to establish Kounis syndrome including serum histamine, tryptase, specific IgE antibodies, complement proteins (C4, and C1 – esterase inhibitors) at weekends, and the patient did not give her informed consent for allergy stimulation test, in consideration of patient’s history, ECG, and CAG findings, and her favourable response to antihistaminic treatment diagnosis of Kounis syndrome was agreed upon. The patient was followed up without any complication for two days, and started on 100



mg oral acetylsalicylic acid. She was discharged with recommendations to consult allergy department so as to investigate other sources of her allergy.

DISCUSSION

Cardiovascular symptoms associated with allergy, hypersensitivity, anaphylaxis or anaphylactic reactions have been cited in the English, German, and Austrian medical literature for 70 years.^[4] The first case report from our country was submitted by Biteker et al.^[6] in the year 2009. The first case report of urticaria-related MI was about a 49-year-old male patient who had been receiving daily doses of 300,000 U penicilline treatment. This patient had been treated successfully

with dicumarol, papaverine, morphine, and diphenhydramine.^[7] However detailed description of allergic angina syndrome which presents with microvascular angina or endothelial dysfunction was not made till the year 1991.^[1]

Kounis syndrome is defined as acute coronary syndrome seen as an activation of mast cells, and other inflammatory cells in conditions of allergy, hypersensitivity, anaphylaxis or anaphylactic reactions.^[8] Neutral proteases which also include tryptase, and chymase, arachidonic acid products, histamine, platelet-activating factor, and a series of inflammatory mediators as various chemokines, and cytokines secreted during activation process lead to the development of Kounis syndrome via inducing coronary vasospasm or occlusion. Platelets together with FcεRI, and FcεRII receptors accompany in this cascade of events.^[8] Exposure to environmental factors, use of many drugs including angiotensin-converting enzyme inhibitors, antibiotics, analgesics, anesthetic agents, contrast agents, and coronary stents, and also bee stings, and insect bites, some food products, vaccines, coronary allograft vasculopathy, Takotsubo cardiomyopathy (broken heart syndrome) seem to be related to Kounis syndrome.^[4,8] It has been reported that the film artist Christopher Reeve who was famous as a movie character “superman” died following an injection of amoxycillin used as antibiotherapy, and renown pop star Michael Jackson also lost his life due to recurrent injections of propofol, an anesthetic agent with known antigenic characteristics because of Kounis syndrome.^[4]

Kounis syndrome is not a rarely seen entity, however only small number of cases have been reported in the literature, and clinical practice which may be

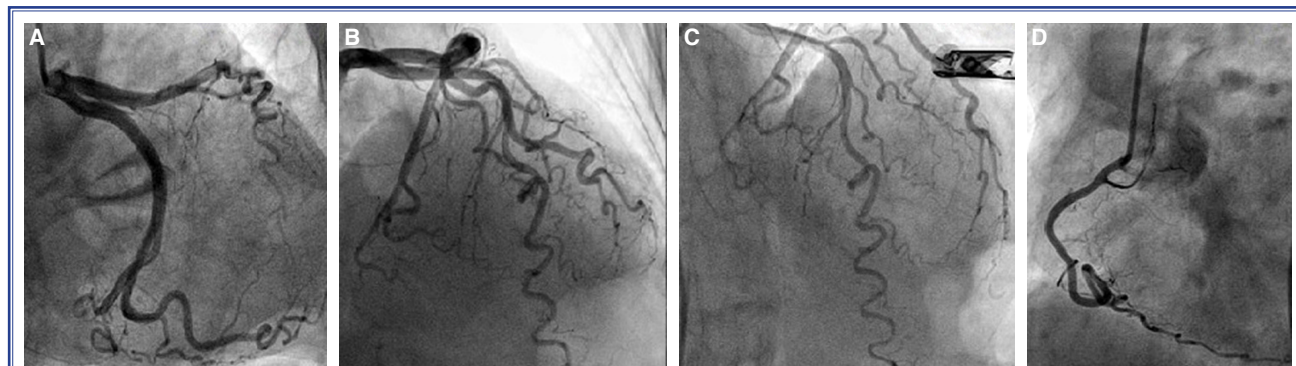


Figure 3. (A-D) Coronary angiograms of the patient.

related to inaccurate diagnoses or undiagnosed cases. In a study performed in a tertiary hospital in Turkey, Kounis syndrome was reported in 8 (0.2%) out of 3876 patients who had undergone coronary angiographic examinations because of acute coronary syndrome.^[9]

Kounis NG, firstly in the year 2006, attracted attention to potential link between components of coronary stent and hypersensitivity reaction in cases of drug-eluting coronary stent thrombosis. The first pediatric case of allergic MI was reported in the year 2009, and finally in the year 2015, Lippi et al.^[12] observed higher levels of TnI which are specific to myocardial injury in patients who consulted emergency service because of anaphylaxis, angioedema or urticaria-angioedema when compared with healthy controls.^[10,11] These findings indicate that heart, and especially coronary arteries are the first target anatomical structures in cases with hyperintensity reactions, and anaphylaxis.

The basic etiology of clinical manifestations observed in Kounis syndrome is coronary artery vasospasm. Activation of plaques, and systemic hypotension may contribute to the occurrence of this clinical entity. Hypotension may lead to global cardiac ischemia rather than local MI. Clinically, concomitancy of anaphylaxis, tachycardia, decreased coronary perfusion pressure, and occasionally severe hypoxia may cause acute ischemic injury.^[13] MI is observed during the process of allergic reaction, and it is rarely reported in the absence of systemic hypotension.^[14] Corticosteroids which are used in the treatment of many inflammatory conditions or even anaphylaxis may paradoxically lead to allergic reactions or even anaphylaxis. Owecki et al.^[15] indicated that corticosteroids might induce acute coronary syndrome based on their observation of this syndrome in a female patient who had been given high doses of corticosteroids (1 g/d i.v.) with the indication of active Graves ophthalmopathy. In this case severe hypertension had induced development of MI on the 5. day of treatment. Rapid parenteral administration of corticosteroids for the treatment of anaphylactic reactions may occasionally lead to cardiovascular collapse especially in patients with drug allergy. Some authors assert that acute episodes may be evoked by corticosteroids secondary to increased concentrations of epinephrine in blood, and increased sensitivity of

cardiomyocytes against catecholamines.^[16] However in our case, cardiovascular collapse was not detected. Besides the patient was not tachycardic, hypotensive or hypertensive. Therefore acute coronary syndromes caused by these conditions were excluded.

As previously reported a young patient with normal coronary arteries who had been stung by a wasp, and consulted with the manifestations of anaphylaxis experienced acute MI (Kounis syndrome) after therapeutic dose of prednisolone.^[13] However up to now, a case of Kounis syndrome caused by triamcinolone injection has not been published. Ours is the first case report in the literature about triamcinolone as a culprit agent inducing development of Kounis syndrome.

Our patient consulted dermatology clinic because of rashes, and itching involving her scalp skin. Dermatologist made the diagnosis of dermatitis, and prescribed IM triamcinolone acetate 40 mg/mL (Kenacort-A Retard IM ampule). Nearly 15 minutes after the first dose of the treatment, she suffered from attacks of typical angina, and the first 2 distinct ECGs of this patient were consistent with acute coronary syndrome (Figs. 1 and 2). She was not tachycardic, hypotensive or hypertensive.

In patients with suggestive diagnosis of Kounis syndrome in addition to appropriate management of acute coronary syndrome, determination of serum histamine, tryptase, specific IgE antibodies, complement protein levels (C4 ve C1-esterase inhibitors), and investigation for eosinophilia aid in diagnosis. High levels of serum histamine, and tryptase levels indicate an allergic reaction, and support the diagnosis. However shorter half-lives of histamine, and tryptase (10, and 90 minutes, respectively) adversely affect the diagnostic value of these tests. Therefore, normal tryptase levels do not exclude the diagnosis.^[17] In our case, analysis for histamine, and tryptase levels could not be made because of delayed admission at weekend, and among tests performed under emergency conditions only TnI levels were increased, while levels of white blood cells, and their subtypes were within normal limits. Following intramuscular injection of triamcinolone acetate (40 mg/mL), symptoms of acute coronary syndrome were observed in the patient with increased TnI values who was brought into catheterization laboratory for coronary angiographic examination which revealed presence of normal coronary arteries. Despite lack of allergic

signs, and symptoms (rashes, pruritus etc.) or findings suggestive of anaphylaxis (cardiovascular collapse, tachycardia, hypotension etc), and inability to analyze serum histamine, tryptase, specific IgE antibodies, complement proteins (C4 and C1-esterase inhibitors), resolution of her pain, and abnormal ECG findings of the patient with antihistaminic treatment suggested the presence of Kounis syndrome (Fig. 3).

In conclusion, Kounis sendrom is a clinical entity with widespread etiological spectrum which may effect both male, and female population of different ages, ethnicities, coming from every geographic region. Accurate diagnosis, and appropriate treatment in cases involving heart, and coronary arteries which mostly affected by allergic reactions or similar anaphylactic reactions carry vital importance. Within this context, detailed, and accurate anamnesis obtained before physical examination should be taken as seriously as diagnosis, and treatment. However, it should not be forgotten that even if the anamnesis does not reveal any evidence of responsiveness to corticosteroids, therapeutic use of corticosteroids in such cases may cause Kounis syndrome. Therefore extreme care should be exerted during its use, and the patients should be carefully followed up from their hospitalization up to the completion of their treatment.

Peer-review: Externally peer-reviewed.

Conflict-of-interest: None.

Informed Consent: Written informed consent was obtained from the patient for the publication of the case report and the accompanying images.

Authorship contributions: Concept: H.K.; Design: M.Y.; Supervision: M.Y.; Materials: H.K.; Data collection: H.K.; Literature search: M.Y.; Writing: M.Y.; Critical review: M.Y., H.K.

REFERENCES

1. Kounis NG, Zavras GM. Histamine-induced coronary artery spasm: the concept of allergic angina. *Br J Clin Pract* 1991;45:121–8.
2. Constantinides P. Infiltrates of activated mast cells at the site of coronary atheromatous erosion or rupture in myocardial infarction. *Circulation* 1995;92:1083.
3. Braunwald E. Unstable angina: an etiologic approach to management. *Circulation* 1998;98:2219–22.
4. Kounis NG. Kounis syndrome: an update on epidemiology, pathogenesis, diagnosis and therapeutic management. *Clin Chem Lab Med* 2016;54:1545–59.
5. Biteker M. A new classification of Kounis syndrome. *Int J Cardiol* 2010;145:553.
6. Biteker M, Duran NE, Biteker F, Civan HA, Gündüz S, Gökdenez T, et al. Kounis syndrome: first series in Turkish patients. *Anadolu Kardiyol Derg* 2009;9:59–60.
7. Pfister CW, Plice SG. Acute myocardial infarction during a prolonged allergic reaction to penicillin. *Am Heart J* 1950;40:945–7.
8. Kounis NG, Mazarakis A, Tsigkas G, Giannopoulos S, Goudevenos J. Kounis syndrome: a new twist on an old disease. *Future Cardiol* 2011;7:805–24.
9. Biteker M. Current understanding of Kounis syndrome. *Expert Rev Clin Immunol* 2010;6:777–88.
10. Kounis NG, Kounis GN, Kouni SN, Soufras GD, Niarchos C, Mazarakis A. Allergic reactions following implantation of drug-eluting stents: a manifestation of Kounis syndrome? *J Am Coll Cardiol* 2006;48:592–3.
11. Biteker M, Duran NE, Biteker FS, Civan HA, Kaya H, Gökdenez T, et al. Allergic myocardial infarction in childhood: Kounis syndrome. *Eur J Pediatr* 2010;169:27–9.
12. Lippi G, Buonocore R, Schirosa F, Cervellin G. Cardiac troponin I is increased in patients admitted to the emergency department with severe allergic reactions. A case-control study. *Int J Cardiol* 2015;194:68–9.
13. Arslan Z, Iyisoy A, Tavlasoglu M. Acute myocardial infarction after prednisolone administration for the treatment of anaphylaxis caused by a wasp sting. *Cardiovasc J Afr* 2013;24:e4–6.
14. Gupta MK, Gupta P, Rezai F. Histamine-can it cause an acute coronary event? *Clin Cardiol* 2001;24:258–9.
15. Owecki M, Sowiński J. Acute myocardial infarction during high-dose methylprednisolone therapy for Graves' ophthalmopathy. *Pharm World Sci* 2006;28:73–5.
16. Takagi S, Miyazaki S, Fujii T, Daikoku S, Sutani Y, Morii I, et al. Dexamethasone-induced cardiogenic shock rescued by percutaneous cardiopulmonary support (PCPS) in a patient with pheochromocytoma. *Jpn Circ J* 2000;64:785–8.
17. Tok D, Ozcan F, Sentürk B, Gölbaşı Z. A case of acute coronary syndrome following the use of parenteral penicillin: Kounis syndrome. *Türk Kardiyol Dern Ars* 2012;40:615–9.

Keywords: Hypersensitivity; Kounis syndrome; non-ST elevation myocardial infarction.

Anahtar sözcükler: Aşırı duyarlılık; Kounis sendromu; ST-yükselmesi miyokart enfarktüsü.