

Dev disekan aort anevrizmasına bağlı Ortner sendromu Ortner's syndrome caused by dissecting aortic aneurysm

Dr. Ferhat Özyurtlu, Dr. Halit Acet,# Dr. Mehmet Zihni Bilik,

*** Dr. Abdurrahman Tasa†**

Clinics of Cardiology, Private Sada Hospital, İzmir;

Clinics of Cardiology, Private Özel Memorial Hospital, Diyarbakır;

*Dicle Üniversitesi Tıp Fakültesi Kardiyoloji Anabilim Dalı, Diyarbakır;

†Bezmialem Üniversitesi Tıp Fakültesi Kardiyoloji Anabilim Dalı, İstanbul

Özet– Ortner sendromu kardiyovasküler nedenlerle oluşan sol larenjeal reküren sinir basısına bağlı ses kısıklığıdır. Kardiyovasküler nedenler, kalp kapak hastalıkları, torasik aort anevrizması, doğuştan kalp hastalıkları gibi geniş bir yelpazeye sahiptir. Bu yazıda, literatürde daha önce bildirilmemiş büyüklükte bir çapa (120 mm) ulaşan dev disekan aort anevrizmasına bağlı olarak gelişen Ortner sendromu olgusu sunuldu. Yetmiş bir yaşındaki erkek hasta efor dispnesi, halsizlik ve ses kısıklığı yakınmaları ile başvurdu. İndirekt laringoskopik bakıda sol ses teli felci görülen hastanın göğüs radyografisinde sol üst zonu dolduran 120 mm'ye ulaşan kitle saptandı. Toraksın bilgisayarlı tomografisinde aort yayı düzeyinde çapı 120 mm'ye ulaşan diseksiyon gelişmiş aort anevrizması vardı. Önerilen cerrahi tedaviyi kabul etmeyen hasta izlemin 4. ayında kaybedildi.

Summary– Ortner's syndrome is type of hoarseness caused by compression on the left laryngeal recurrent nerve as a result of cardiovascular pathology. A wide range of cardiovascular etiologies such as valvular heart disease, thoracic aortic aneurysm and congenital heart disease may result in Ortner's syndrome. We present a case of Ortner's syndrome caused by a large diameter (120 mm) aneurysm, previously unreported in the literature. A male patient aged 71 years was admitted to our clinic because of exertional dyspnea, asthenia and hoarseness. In the indirect laryngoscopic examination, left vocal cord paralysis of the patient was observed and his chest X-ray revealed a mass with a diameter of 120 mm that filled the left upper zone. On the thoracic CT, a dissecting aortic aneurysm 120 mm in diameter was seen on the level of the aortic arch. Surgical treatment was suggested, but the patient refused treatment and died at the 4th month of the follow-up period.

Geliş tarihi: 29.05.2012 Kabul tarihi: 02.08.2012

Yazışma adresi: Dr. Ferhat Özyurtlu. Özel Sada Hastanesi, İzmir Çanakkale Asfaltı Üzeri, Menemen, İzmir.

Tel: +90 232 - 832 99 00 e-posta: fozyurtlu@yahoo.com

Submitted on: 05.29. 2012 Accepted for publication on: 08.02. 2012

Address of correspondence: Dr. Ferhat Özyurtlu. Özel Sada Hastanesi, İzmir Çanakkale Asfaltı Üzeri, Menemen, İzmir.

Phone: +90 232 - 832 99 00 e-mail: fozyurtlu@yahoo.com

Abbreviation:

CT *Computed tomography*

In 1897, Norbert Ortner defined the Ortner's syndrome which develops secondary to cardiovascular etiologies, and compresses the left laryngeal recurrent nerve leading to hoarseness.[1] This syndrome has been also termed as cardiocaval syndrome. This syndrome has a wide spectrum of cardiovascular etiologies as thoracic aortic aneurysm, congenital heart diseases, and valvular diseases.

In this paper we present a case with Ortner's syndrome caused by a giant dissecting aortic aneurysm with a large diameter not reported previously in the literature.

CASE PRESENTATION

A 71-year-old male patient who referred to our out-patient clinics with complaints of fatigue, exertional dyspnea, and hoarseness. He had been operated 6 years ago for aortic aneurysm. Thorax CT performed lastly 2 years ago had revealed an aortic diameter within normal limits. He had experienced hypotensive attacks during hemodialysis sessions for his chronic renal failure. On physical examination coarse pulmonary sounds were heard, and indirect laryngoscopic examination detected left vocal cord paralysis. Other laryngeal structures were normal. During cardiac auscultation, a 2/6 systolic murmur over mitral, and a 1 / 4 diastolic murmur over the aortic valves were heard. Electrocardiogram demonstrated a sinus rhythm. Chest X-ray revealed a mass with a smooth border, and a diameter of 120 mm which filled the upper zone completely. (Figure 1). On echocardiograms, left atrial dilation, left

ventricular hypertrophy, a mild degree of global left ventricular hypokinesia, enlargement of ascending aorta with its largest diameter of 42 cm, moderate mitral, and aortic regurgitation, mild-moderate tricuspid regurgitation, moderate pulmonary hypertension were detected, and ejection fraction was measured as 45 percent. Suprasternal area could not be evaluated clearly because of superimposed echogenicity. Contrast-enhanced thorax CT detected an aortic aneurysm involving only aortic arch with a diameter approaching to 120 mm at the level of aortic arch. (Figure 2). Patent true lumen was nearly 80 mm in diameter. However on the lateral aspect, non-calcified heterogeneous atheromatous plaques, and on the periphery alterations consistent with a hematoma were seen (Figure 2). Aneurysm filled all apicoposterior region of the left upper lobe. However, any pathology was not detected in lungs, and mediastinum. Referral of the patient to another center was planned for surgical evaluation, but the patient rejected, and thus included in the medical follow-up protocol. At 4.th month of the follow-up period he died.

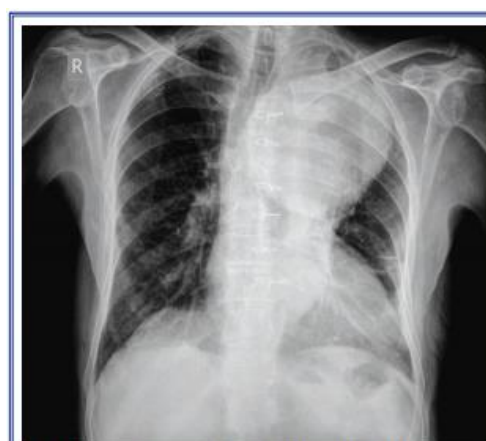

Figure 1. Anteroposterior chest radiogram: a mass lesion with smooth contours, and largest diameter approaching 120 mm which filled up left upper zone completely

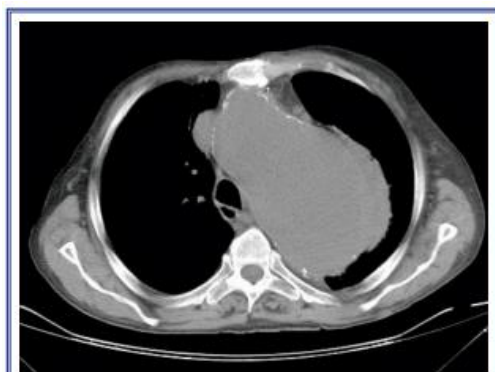


Figure 2. Contrast-enhanced thorax CT: an aortic aneurysm with its largest diameter approaching 120 mm situated on the aortic arch with heterogeneous non-calcific atheromatous plaques on the lateral aspect, and a peripheral mass consistent with a hematoma

DISCUSSION

Vocal cord paralysis can be related to laryngeal mass lesions, but it can also manifest as a result of impairment of nervous innervation because of thyroidal, and neck masses, and abnormal intrathoracic formations.[2] A few studies have indicated that left vocal cord paralysis is more frequently seen than the right side.[3] The most prevalent causes of unilateral vocal cord paralysis are tumors (32 %), followed by surgical interventions (30 %).[2] Vocal cord paralysis developed secondary to aortic aneurysm is seen less frequently. Hoarseness can be the first symptom in some cases of aortic aneurysms. Some of these cases are potentially life-threatening dissecting aortic aneurysms [4] Hoarseness caused by compression on the left laryngeal recurrent nerve as a result of pathologies involving heart, and great intrathoracic vessels is termed as Ortner's syndrome.[5] The most frequent cause of Ortner's syndrome is left atrial enlargement due to mitral stenosis as was seen in the firstly defined case.[6] Subsequently, cases with

Ortner's syndrome due to mitral valve prolapse, aortic aneurysm, and dissection, septal defect [7] ventricular aneurysm [8] and cor pulmonale [9] have been described. To our knowledge, our case is the largest recurrent dissecting aortic aneurysm in the literature which caused development of Ortner's syndrome. An individual with a history of an aortic aneurysm and/or dissection carries higher risk of developing aneurysm at another aortic segment which necessitates closer postoperative follow-up of these patients. Our patient had attended his control visit lastly 2 years ago. Imaging modalities have a critically important place in the diagnostic algorithms of vocal cord paralysis. Especially in patients with a cardiovascular disease their role is more crucial. Special diagnostic value of CT has been demonstrated in the detection of aortic, and pulmonary abnormalities.[10]

Ortner's syndrome should be suspected in patients presented with hoarseness, whose indirect laryngoscopic examinations could not detect any abnormality. Considering that hoarseness can be an outcome of aortic aneurysm, and it can develop because of other cardiac etiologies which might lead to Ortner's syndrome, necessary examinations should be conducted.

Conflict of interest: None declared.

REFERENCES

1. Ortner NI. Recurrenslahmung bei mitral stenose. Wiener Klinische Wochenschrift 1897;10:753-5.
2. Yamada M, Hirano M, Ohkubo H. Recurrent laryngeal nerve paralysis. A 10-year review of 564 patients. Auris Nasus Larynx 1983;10:1-15.
3. Glazer HS, Aronberg DJ, Lee JK, Sagel SS. Extralaryngeal causes of vocal cord paralysis: CT evaluation. AJR Am J Roentgenol 1983;141:527-31.

4. Foster PK, Astor FC. Vocal fold paralysis in painless aortic dissection (Ortner's syndrome). *Ear Nose Throat J* 2001;80:784.
5. Thirlwall AS. Ortner's syndrome: a centenary review of unilateral recurrent laryngeal nerve palsy secondary to cardiothoracic disease. *J Laryngol Otol* 1997;111:869-71.
6. Annema JT, Brahim JJ, Rabe KF. A rare cause of Ortner's syndrome (cardiovocal hoarseness). *Thorax* 2004;59:636.
7. Kishan CV, Wongpraparut N, Adeleke K, Frechie P, Kotler MN. Ortner's syndrome in association with mitral valve prolapse. *Clin Cardiol* 2000;23:295-7.
8. Eng J, Nair KK. Giant left ventricular aneurysm. *J Cardiovasc Surg (Torino)* 1993;34:85-6.
9. Soliman MS. Hoarseness in schistosomal cor pulmonale. *Chest* 1997;112:1150.

10. Gosling JA, Harris PF, Humpherson JR, Whitmore I, Willan PLT. *Human anatomy: colour atlas and text*. 3rd ed. London: Mosby-Wolfe; 1996.

Anahtar sözcükler: Aort anevrizması, torasik/komplikasyonlar; ses kısıklığı/etyoloji; Ortner sendromu; yineleyen laringeal sinir; ses teli felci.

Key words: Aortic aneurysm, thoracic/complications; hoarseness/etiology; Ortner's syndrome; recurrent laryngeal nerve; vocal cord paralysis.