

CASE REPORT

Transcatheter closure of atrial septal defect with atrial septal occluder in a patient with nickel allergy

Nikel allerjisi olan hastada atriyal septal defektin kapama cihazı ile perkütan kapatılması

Hasan Arı, M.D., Selma Arı, M.D., Ahmet Tütüncü, M.D., Alper Karakuş, M.D., Mehmet Melek, M.D.

Department of Cardiology, Bursa Yüksek İhtisas Training and Research Hospital, Bursa, Turkey

Summary– Presently described is transcatheter closure of atrial septal defect with atrial septal occluder (ASO) device in a patient with nickel allergy. Patients with metal allergy who will undergo nitinol device implantation should be tested for possible nickel hypersensitivity. ASO device and treatment strategy (percutaneous or surgical) should be selected according to allergy test result.

Özet– Kapama cihazı ile perkütan olarak kapattığımız nikel allerjisi olan atriyal septal defektli hastayı sunduk. Metal allerjisi olan ve nitinol içeren cihaz implantasyonu yapılacak hasta nikel aşırı duyarlılığı açısından değerlendirilmelidir. Kullanılacak olan kapama cihazı veya tedavi stratejisi (perkütan veya cerrahi) allerji testi sonucuna göre seçilmelidir.

Transcatheter closure of atrial septal defect (ASD) with atrial septal occluder (ASO) is an alternative to surgical closure. There are many different ASO devices available for ASD closure. At this time, great majority of ASO devices include components made of nitinol, which is an alloy of 55% nickel and 45% titanium.^[1] In this report, ASO implantation in a patient with nickel allergy is described and rational approach to these patients is discussed.

CASE REPORT

A 28-year-old woman was referred to our clinic for transcatheter closure of secundum ASD. Transesophageal images revealed 2 cm secundum ASD without anterior superior rim. Other rims were sufficient for percutaneous closure (Figure 1). The patient had nickel allergy history. Due to potential ASO device allergy, patch test was performed with 2 different ASO devices: Amplatzer ASO device (St. Jude Medical Inc., St. Paul, MN, USA) and Lifetech Cera ASO device (Lifetech Scientific Corp., Shenzhen, China). After 48 hours, cutaneous erythema and slight swelling developed at site of Amplatzer ASO device, while no cuta-

neous reaction occurred at site of Lifetech Cera ASO device (Figure 2). Stretched diameter of ASD was determined to be 26 mm with sizing balloon (Figure 3a). Defect was successfully closed with 30 mm Lifetech Cera ASO device under antihistaminic and steroid premedication (Figure 3b). One day later, transthoracic echocardiography indicated ASD had been successfully closed with ASO device (Figure 3c, d). The patient was discharged with aspirin 100 mg and clopidogrel 75 mg treatment for 6 months. At 1-year follow-up, the patient remained symptom-free.

Abbreviations:

ASD Atrial septal defect
ASO Atrial septal occluder

DISCUSSION

Most of the devices used in cardiac interventional procedures contain various metals and alloys. Nickel, in particular, is one of the most widely used metals. Some 8% to 10% of women and 1% to 2% of men have nickel allergy.^[2] Type IV or cell-mediated hypersensitivity reactions are the most common reactions associated with cardiac implants.^[3] Hypersensitivity to nickel may include localized and systemic reac-

Received: August 18, 2016 Accepted: December 01, 2016

Correspondence: Dr. Hasan Arı. Bursa Yüksek İhtisas Eğitim ve Araştırma Hastanesi, 1. Kardiyoloji Kliniği, Yıldırım, 16320 Bursa, Turkey.

Tel: +90 224 - 360 50 50 e-mail: hasanari03@yahoo.com

© 2017 Turkish Society of Cardiology



tions. Direct cutaneous exposure can cause localized erythematous, pruritic, vesicular, scaly patches. Ingestion of nickel may cause systemic hypersensitivity, and reaction can include hand dermatitis or generalized eczematous reactions. Direct exposure to nickel through nitinol-containing prosthetic cardiac implants can cause systemic reactions. Systemic

nickel hypersensitivity may become manifest with numerous clinical symptoms, including palpitations, shortness of breath, chest discomfort, back pain, migraine attack, rash/urticaria, pericardial effusion, and angioedema.^[4] Reaction can occur from 2 days up to 1 month after implantation. Serum nickel concentration has been evaluated after ASO implantation and it was found that mean serum nickel concentration rose to a peak at 1 month post implantation and then returned to baseline 12 months later.^[5]

Patch test is a method used to determine whether a specific substance causes allergic inflammation of a patient's skin. Patch test relies on the principle of type IV hypersensitivity reaction and may be used to determine allergy to many metals. Recently, 2 studies found that positive cutaneous nickel patch test before device implantation was related to allergic symptoms after device implantation.^[4,6] However, according to another study, allergic symptoms after device implantation were similar between nickel-allergic and non-nickel-allergic groups.^[7] But negative trial was a retrospective analysis and number of patients was inadequate.

According to the Congenital Cardiovascular Interventional Study Consortium, nickel allergy incidence was 2.06% (33 of 1600 device implantations) after closure of congenital heart defects with nitinol-containing devices.^[8] Manufacturer and User Facility Device Experience database indicated that ASO device allergic reaction rate was 1.4% (10 of 705 ASO implantations).^[9] Most allergic reactions can be relieved with medical therapy. However, after percutaneous ASO implantation, respiratory distress due to allergic reaction that could not be relieved with medical therapy has been reported in some cases and device had to be removed surgically.^[10,11]

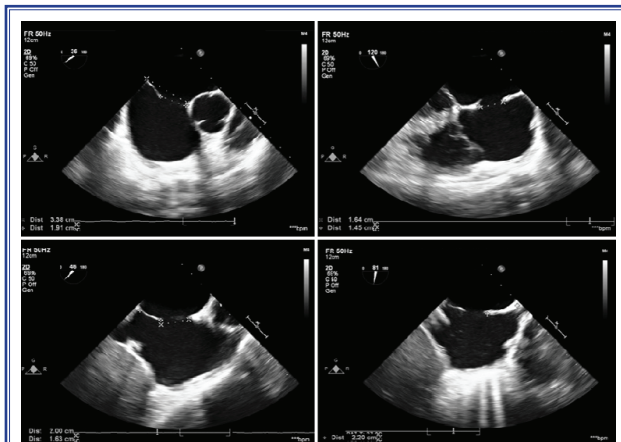


Figure 1. Transesophageal images of the atrial septal defect and rims.

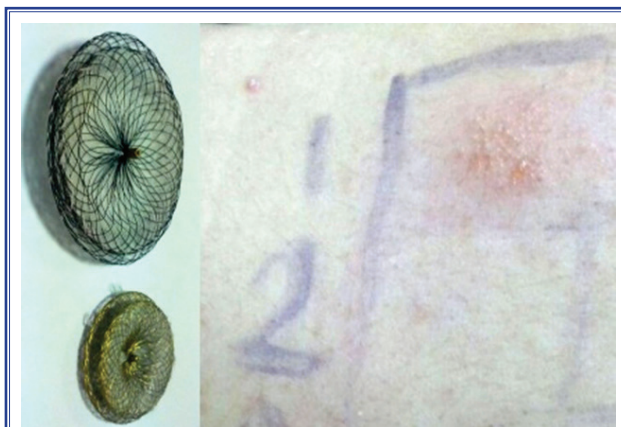

Figure 2. The patch test result of 2 different atrial septal occluder devices.

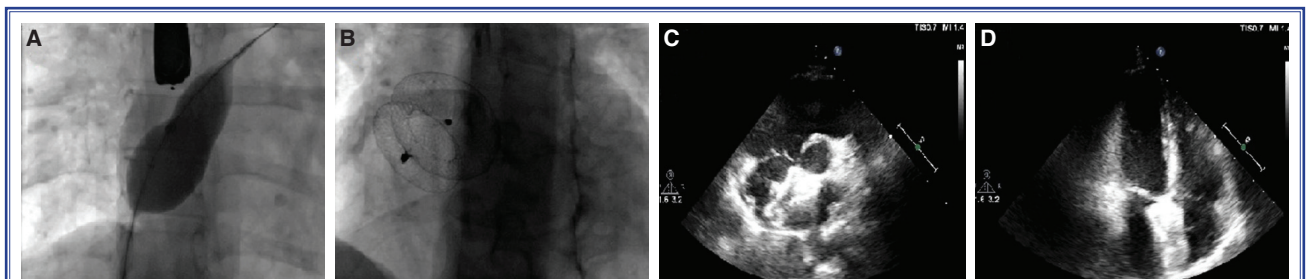


Figure 3. (A) Fluoroscopic view of the sizing balloon. (B) Fluoroscopic view of the atrial septal occluder device. (C, D) Transthoracic parasternal short and apical long axis view of the atrial septal occluder device.

Surface of the Lifetech Cera device is covered with TiN (titanium nitride, ceramic); therefore, nickel release to plasma and contact allergic reaction were reduced. Similarly, nickel release and contact allergic reaction may be less frequent with platinum-covered Cocoon septal occluder (Vascular Innovations Inc., Pleasanton, CA, USA) and expanded polytetrafluoroethylene-covered Gore Helex septal occluder (WL Gore & Associates, Inc., Newark, DE, USA).^[12] These devices could be considered treatment option for patients with ASD and nickel allergy.

In summary, we recommend that patients be questioned about potential nickel allergy before transcatheter ASO implantation for ASD.

Acknowledgments

This case was presented as an oral presentation at the Conference of Cases and Solutions in Current Cardiology Practice, Girne, Cyprus, on October 2–4, 2015 and was selected as the second best case presentation.

Conflict-of-interest: None declared.

REFERENCES

1. Ferreira MA, Luersen MA, Borges PC. Nickel-titanium alloys: A systematic review. *Dental Press J Orthod* 2012;17:71–82. [\[CrossRef\]](#)
2. Sunderman F, Oskarson A. Nickel. In: Marian E. (ed). *Metals and their compounds in the environment: Occurrence, analysis and biologic relevance*. New York: VCH, 1991; p. 1101–25.
3. Honari G, Ellis SG, Wilkoff BL, Aronica MA, Svensson LG, Taylor JS. Hypersensitivity reactions associated with endovascular devices. *Contact Dermatitis* 2008;59:7–22. [\[CrossRef\]](#)
4. Wertman B, Azarbal B, Riedl M, Tobis J. Adverse events associated with nickel allergy in patients undergoing percutaneous atrial septal defect or patent foramen ovale closure. *J Am Coll Cardiol* 2006;47:1226–7. [\[CrossRef\]](#)
5. Ries MW, Kampmann C, Rupprecht HJ, Hintereder G, Hafner G, Meyer J. Nickel release after implantation of the Amplatzer occluder. *Am Heart J* 2003;145:737–41. [\[CrossRef\]](#)
6. Rigatelli G, Cardaioli P, Giordan M, Aggio S, Chinaglia M, Braggion G, et al. Nickel allergy in interatrial shunt device-based closure patients. *Congenit Heart Dis* 2007;2:416–20.
7. Kim HJ, Shin JU, Lee J, Lee H, Jin S, Kim SH, et al. Positive reactions to nickel on a patch test do not predict clinical outcome of nickel alloy-based atrial septal defect occluder implantation. *Dermatology* 2015;230:184–8. [\[CrossRef\]](#)
8. Gordon BM, Moore JW. Nickel for your thoughts: Survey of the Congenital Cardiovascular Interventional Study Consortium (CCISC) for nickel allergy. *J Invasive Cardiol* 2009;21:326–9.
9. Moore J, Hegde S, El-Said H, Beekman R 3rd, Benson L, Bergersen L, et al. Transcatheter device closure of atrial septal defects: a safety review. *JACC Cardiovasc Interv* 2013;6:433–42. [\[CrossRef\]](#)
10. Rabkin DG, Whitehead KJ, Michaels AD, Powell DL, Karwande SV. Unusual presentation of nickel allergy requiring explantation of an Amplatzer atrial septal occluder device. *Clin Cardiol* 2009;32:55–7. [\[CrossRef\]](#)
11. Uğuz E, Erdoğan K, Sener E. Explantation of an atrial septal occluder device in a patient with nickel hypersensitivity. *Anadolu Kardiyol Derg* 2014;14:402–3. [\[CrossRef\]](#)
12. Chamie F, Chamie D, Simoes L, Mattos R. Transcatheter occlusion of secundum atrial septal defects with latest generation coated nitinol wire devices. *Revista Brasileira de Cardiologia Invasiva* 2014;22:41–7. [\[CrossRef\]](#)

Keywords: Atrial septal defect; nickel allergy; septal occluder device.

Anahtar sözcükler: Atrial septal defekt; nikel allerjisi; septal kapama cihazı.