

**Sub-chronic toxicity assessment of orally administered methanol (70%) seed extract of *Abrus precatorius* L. in Wistar albino rats**

**Shazia Tabasum<sup>\*1</sup>, Swati Khare<sup>2</sup>, Kirti Jain<sup>1</sup>,**

<sup>1</sup>Department of Botany, Govt. Science and Commerce College, Benazeer, Bhopal,  
Madya Pradesh, India.

<sup>2</sup>Department of Botany, Govt. MLB Girls PG Autonomous College, Bhopal, Madya  
Pradesh, India.

Running title: Sub-chronic toxicity study of *Abrus precatorius* L. seeds

Corresponding author's name: Shazia Tabasum

Address: C/O: A-M-Nadvi, 29, Jinsi Road, Jahingirabad, Bhopal, M.P., 462008, India.

Email: shaziatabasum49@gmail.com

Phone: +91 7006354561

## ABSTRACT

**Objectives:** *Abrus precatorius* L. is a famous medicinal plant of family Fabaceae and is widely used in traditional medicine for the treatment of various ailments. However, there is little toxicological data available regarding its safety following repeated exposure; therefore, the present study was designed to evaluate the 28 days sub-chronic toxicity of methanol (70%) crude extract of *A. precatorius* seeds in adult Wistar albino rats.

**Materials and Methods:** Sub-chronic toxicity experiment was conducted by oral administration of graded doses (200 mg/kg and 400 mg/kg) of test extract daily for 28 days. Signs of toxicity, food and water consumption, body weight, gross pathology as well as relative organ weight were evaluated. The toxic effects were also assessed using hematological and biochemical data followed by histopathological examination of various internal organs. All data collected were expressed as mean  $\pm$  standard deviation (SD). The One Way Analysis of Variance (ANOVA) followed by Bonferroni test was used for data interpretation and  $p < 0.05$  was considered as significant.

**Results:** No deaths or evident toxic signs were found throughout the experimental period. There were no significant change in body weight, gross pathology, organ weight or food and water consumption between control and the treated groups. There were no treatment related differences in haematological and biochemical indices. Also, no gross abnormalities or histological alterations were observed.

**Conclusion:** The methanol extract of *A. precatorius* seeds was found non-toxic in sub-chronic intake at the dosages tested. Thus, this study is expected to be beneficial for clinical and traditional applications for safe consumption and to utilize *A. precatorius* as a remedy at a recommended dosage.

**Key words:** *Abrus precatorius*, sub-chronic toxicity, haematology, histopathology, biochemical indices

## INTRODUCTION

Medicinal plants offer numerous opportunities for the development of new drugs, either as extract, pure compound or as a derivative. The natural origin however, does

not guarantee their safety as medicinal purposes. Most of the herbal products used in folk remedy have strong scientific evidences regarding their biological activities. However, the main obstruction to the use of herbal preparations is the lack of scientific and clinical data in support of better understanding of the efficacy and safety of the drugs. Different toxicological studies data like acute, sub-chronic etc. on medicinal plant or their preparations should be obtained in order to increase the assurance of their safety to humans, particularly for use in the development of pharmaceuticals.<sup>1, 2</sup>

*A. precatorius* L. (Family: Fabaceae) locally known as Gunja or Rati is indigenous to India and is found in other tropical and subtropical areas of the world. It is a beautiful, perennial, deciduous, twining woody vine with herbaceous branches and pinnate leaves. The flowers are short stalked, white to pink and are borne in clusters. Fruits are oblong pods that contain characteristics red seeds with black mark at hilum/base. After maturation, these open before falling and curls back to reveal seeds. Seeds are of uniform weight ( $\frac{1}{10^{th}}$  of a gram), therefore were used earlier as standard weighing units by jewellers for weighing silver and gold.<sup>3, 4</sup> These are poisonous when taken internally and therefore are used after mitigation.<sup>5, 6</sup> A number of biochemical constituents have been reported from *A. precatorius* seeds. These are found to be rich in amino acids like serine, alanine, valine, choline, methyl ester; proteins- abrin, Abrus precatorius agglutinin (APA); carbohydrates- galactose, arabinose, xylose; flavonoids- abectorin, dimethoxycentaureidin-7-o-rutinoside, precatorin I, II and III; anthocyanins- delphinindin, pelargonindin, cyaniding; and alkaloids- dimethyl tryptophan, methocation, picatorine, abrine, hypaphorine, choline, trigonelline. The seed proteins are rich in most of the essential amino acids, and they are deficient only in cystine and threonine. Moreover, various triterpenoids, steroids, and fatty acids have also been isolated from *A. precatorius* seeds.<sup>7-11</sup> The principle poisonous component of the seed is abrin, an albumotoxin.<sup>12</sup> The plant has been used for therapeutic purposes since ancient times. The most widespread use of *A. precatorius* seeds is in the treatment of eye infections and as a potential contraceptive.<sup>4</sup> Dry seeds are powdered and taken one teaspoonful once a day for two days to cure worm infection. Seeds are considered purgative, emetic, aphrodisiac, diuretic, expectorant, refrigerant, vermifuge, febrifuge, laxative and abortifacient. These are commonly used to cure leprosy, dysentery, jaundice, fainting, arthritis, paralysis,

nervous disorders, ulcer, stiffness of the shoulder joints, tuberculosis, headache, diarrhoea, sciatica, tetanus, rabies, convulsions, fever, cold, gastritis, snakebite, conjunctivitis, inflammations and leucoderma in traditional and folk medicines. Hot water extract of seeds is taken orally to cure malaria. Seeds are nutritious as boiled seeds are eaten in certain parts of India. Various African tribes use powdered seeds as oral contraceptives.<sup>8, 13-18</sup> Seeds of this plant are also used to lower high blood pressure and relieve painful swellings. In veterinary medicine, seeds are used in the treatment of fractures.<sup>8, 10</sup> *A. precatorius* seeds are also reported for anticancer,<sup>19</sup> antifertility,<sup>4</sup> antitumor, antispermatogenic, antibacterial,<sup>20, 21</sup> antidiabetic,<sup>22</sup> antioxidant,<sup>23</sup> nephroprotective,<sup>24</sup> antiarthritic,<sup>25</sup> antimicrobial<sup>19</sup> and antimalarial activities.<sup>26</sup> Despite its popularity in folk medicine, the toxicity profile has not been yet explored. The present study is thus based on the sub-chronic toxicity of the methanol (70%) extract of *A. precatorius* seeds in Wistar albino rats. Sub-chronic toxicity tests are designed to examine the effects resulting from repeated exposure over a portion of average life span of an experimental animal.

## **MATERIALS AND METHODS**

### **Seed collection and authentication:**

Seeds of *A. precatorius* were collected from local market of Bhopal, Madhya Pradesh, India. The seeds were authenticated by Dr. Zia-Ul-Hassan, Head of the Department, Govt. Saifia Science College, Bhopal and voucher specimen (reference No. 520/Bot/Saifia/2015) was deposited there for future reference. The seeds were cleaned and washed with distilled water in order to remove the impurities and were shade dried. The seeds were then coarsely powdered in a mixer grinder.

### **Preparation of methanol (70%) seed extract:**

Dried and coarsely powder of *A. precatorius* seeds (250 g) was defatted with petroleum ether and the marc remaining was extracted successively by methanol (70%) using cold maceration method. Filtrate obtained was evaporated in rotary evaporator under reduced pressure and was vacuum dried. The dried extract was packed in air tight container, labelled and stored in a refrigerator (2-4 °C) until needed for the experimental purpose.

### **Ethical Approval**

The use of animals for the present study was reviewed and approved with approval reference no. PBRI/IAEC/PN-412 by the Institutional Animal Ethical Committee of Pinnacle Biomedical Research Institute (PBRI) Bhopal, Madhya Pradesh (Reg. No. 1283/PO/c/09/CPCSEA) and maintained as per the guidelines of Committee for the Purpose of Control and Supervision of Experiments on Animals (CPCSEA) India.

### **Selection of animals**

For the purpose of sub-chronic toxicity studies, adult Wistar albino rats weighing about 94-178 g of both the sexes were used and animals were obtained from animal house of Pinnacle Biomedical Research Institute Bhopal (PBRI), Madhya Pradesh, India.

### **Maintenance of experimental animals**

The animals were kept in properly numbered large polypropylene cages with stainless steel top grill. These were maintained under standard laboratory conditions ( $24 \pm 2$  °C;  $50 \pm 5\%$  humidity; 12 hours light/12 hours dark cycle) with standard diet (Hindustan Lever, Mumbai, India) and water *ad libitum* and were acclimatized to the laboratory conditions for a week before starting the experiment. Paddy husk was used as bedding material and was changed twice a week.

### **Preparation of test sample**

A suspension was made in 0.1% carboxymethyl cellulose (CMC) solution and administered orally to animals. The administration was done by straight type oral feeding needle. Individual doses were calculated on the basis of animal weight.

### **Sub-chronic toxicity study**

#### **Experimental setup:**

In order to investigate the adverse effects of repeated daily exposure of methanol (70%) crude extract of *A. precatorius* seeds, sub-chronic toxicity study was carried out as per Organisation for Economic Co-operation and Development guidelines (OECD) 407.<sup>27</sup> To determine the dose-related toxic effects, doses of 200 mg/kg/day and 400 mg/kg/day body weight of crude seed extract of *A. precatorius* were administered for the experimental period of 28 days. Eighteen (18) rats of each sex

were randomized into three groups of six animals each. The animals were marked to permit individual identification. Group 1 was control group and received orally normal saline. Group 2 and Group 3 were orally administered with 200 mg/kg/day and 400 mg/kg/day body weight of crude methanol seed extract of *A. precatorius* respectively.

#### **Clinical signs and mortality:**

During the 28 days of experimental period, all the animals were observed once daily for toxicity signs and mortality immediately after dosing and up to 4 hours after dosing.

#### **Weekly body weight:**

Individual body weights of rats were recorded initially and every week and the individual doses were adjusted for the body weight to maintain the target dose level for all experimental animals.

#### **Weekly food and water consumption:**

Food and water consumption parameters were also taken into consideration during the study. Measurement of food and water consumption was performed initially and weekly for each rat.

#### **Blood sample collection:**

After the termination of experimental period, blood samples were collected under diethyl ether anaesthesia from all the animals through retro-orbital plexus puncture using capillary tubes on 29<sup>th</sup> day. The blood from each animal collected in EDTA (ethylenediaminetetraacetic acid) and non-EDTA tubes to determine haematological and biochemical parameters respectively. For Biochemical analysis, the blood samples were allowed to coagulate for 30 minutes and the clear serum was separated by centrifuging at 3000-4000 rpm using cooling micro-centrifuge for 15 minutes. The serum was introduced into new tubes and stored at -20°C until analyzed.

#### **Haematological Investigations**

The blood collected in EDTA containing tubes were taken immediately for haematological investigation. The blood or haematological parameters were

analyzed using automated haematology analyzer (Procan Electronics, Model PE6800). The parameters included: haemoglobin (HGB), red blood cell count (RBC), haematocrit (HCT), red blood cell distribution width (RDW), mean cell volume (MCV), mean cell haemoglobin concentration (MCHC), white blood cell count (WBC), lymphocytes (LYM), granulocytes (GRAN), platelets (PLT), platelet distribution width (PDW), mean platelet volume (MPV), and platelet large cell ratio (P-LCR).

### **Biochemical Estimations**

The effect of seed extract of *A. precatorius* on the activity on the serum biochemical enzymes was estimated calorimetrically. All the biochemical investigations were performed on automated biochemical analyzer (Rapid, Model Star 21). Biochemical estimations evaluated were:-

- a) Kidney function tests: blood urea nitrogen (BUN), creatinine (Cr), uric acid (UA)
- b) Liver function tests: total bilirubin (T-BIL), aspartate aminotransferase (AST), alanine aminotransferase (ALT), alkaline phosphatase (ALP), total proteins (TP)
- c) Lipid Profile: total cholesterol (TC), triglycerides (TG), high density lipoproteins (HDL), low density lipoproteins (LDL)

### **Gross pathology and relative organ weight**

Following blood collection, the animals were anesthetized and dissected out. Immediately liver, kidney, heart, spleen, stomach, adrenal, duodenum, brain, colon, and lungs were excised, freed of fat, washed in cold saline, blotted with clean tissue paper, and observed for gross pathological changes. Then, the organs were weighed in grams using calibrated balance. The relative organ weight of each animal was then calculated as follows:

$$\text{Relative organ weight} = \frac{\text{Absolute organ weight}}{\text{Body weight of rat on sacrifice day}} \times 100$$

### **Histopathological examination**

Defined samples of liver, heart, kidney, spleen, lungs, brain, stomach and duodenum were collected for histological studies. The tissues were fixed immediately in 10% formalin for at least 24 hours, dehydrated through a series of ethanol solutions and

embedded in paraffin. 4-5  $\mu$ m thick sections were cut in a rotary microtome and were stained with hematoxylin and eosin for photo-microscopic observation. All histopathological changes were examined by the pathologist. The microscopic features of the organs of both the treated groups were then compared with the control group.

### **Statistical analysis**

All the experimental data collected from various sub-chronic parameters were statistically analyzed by using SIGMA STAT-3.5 software and expressed as mean  $\pm$  SD. The One Way Analysis of Variance (ANOVA) followed by Bonferroni test was used for interpretation of data. The  $P < 0.05$  was considered as significant.

## **RESULTS**

### **Clinical changes and mortality**

Daily administration of methanol (70%) seed extract of *A. precatorius* at both 200 mg/kg and 400 mg/kg for 28 days did not induce any evident symptom of toxicity in rats of both sexes. No deaths or evident clinical signs were found in any groups throughout the study period.

### **Body weight changes**

Oral administration of *A. precatorius* seed extract in experimental animals for 28 successive days had no statistically significant changes on body weight as compared to the control group (**Figure 1**).

### **Food and water consumption changes**

Oral administration of extract at 200 and 400 mg/kg body weight for a period of 28 days caused no significant alterations in both these indices as compared to the control group (**Figure 2 and 3**).

### **Haematological effects**

The seed extract at both the investigated dose levels had a good haematological tolerance. Haematological parameters of extract treated rats were not significantly



different from those of the control group. Haematological parameters of test groups and the control group are presented in **Table 1**.

### **Biochemical changes**

A study of biochemical parameters showed that the seed extract of *A. precatorius* did not induce any harmful biochemical effects on the experimental animals. No significant alterations were observed in the serum concentrations of renal markers; hepatic markers and lipid profile of extract treated animals. The results of biochemical analysis are summarized in **Table 2**.

### **Gross pathology and relative organ weight changes**

Gross pathology of liver, kidney, heart, spleen, stomach, adrenal, duodenum, brain, colon and lungs of treated rats did not show abnormalities in case of colour and texture as compared to the controls. In this study, the relative organ weight of each organ recorded in the treatment groups did not show a significant difference compared to the controls. Relative organ weights of all the three groups are shown in **Table 3**.

### **Histopathological changes**

The light microscopy examinations of the selected organs (heart, liver, lungs, kidney, spleen, stomach, intestine and brain) of extract treated groups and the control group are shown in **Figure 4**. Histopathological examination showed normal cytoarchitecture and absence of any gross pathological lesion in organs of control as well as extract treated rats.

## **DISCUSSION**

Plants provide a wide variety of biochemical components useful to mankind. These substances can be extracted and used in the preparation of drug, or the plant itself can be used directly as a medication.<sup>28</sup> However, the main obstacle in the use of traditional herbal plants is the lack of proper clinical and scientific data in support of safety of drug. The plants have some toxic substances in them and it is better to evaluate them according to standard procedures and their effects on different parameters in order to establish the safety of plant.<sup>29</sup> Toxicity tests are carried out effectively either on rat or mice due to their availability, low cost and the wealth of

toxicology data in the literature already available for these species.<sup>30</sup> Considering the numerous reported therapeutic potentials of *A. precatorius* seeds as an alternative medicine effective for various diseases, a safety profile was established through sub-chronic toxicity study, as a guide for the management of its application and usage in herbal preparations. This study will serve to prevent exposing humans to potential toxicity related health risks while using *A. precatorius* seeds.

Sub-chronic toxicity was conducted with repeated administration of 200 mg/kg body weight and 400 mg/kg bodyweight of methanol (70%) seed extract of *A. precatorius* and its effects in terms of clinical signs; bodyweight; food and water consumption; gross pathology and organ weight; haematological and biochemical parameters; and histopathology.

Mortality, behavioural signs, body weight and food consumption are very sensitive indicators to assess the toxicity of a substance.<sup>31</sup> In present study, all the test animals were physically active during the test period. There were no signs of toxicity or mortality in rats treated with the extract. No significant changes in body weight, food intake and water consumption of the treated animals also signify the non-toxicity of the extract.

According to early report, the hematopoietic system is one of the most sensitive targets for toxic substances.<sup>32</sup> Haematological analysis easily detects the abnormalities in body metabolic processes and also reveals very important information about the response of the body to injury, deprivation and/or stress.<sup>30</sup> However, in this study the mean value of each parameter was within the normal limits and this further supports the nontoxic nature of the extract.

Biochemical investigation showed that no significant modifications of assessed parameters occurred in rats. The levels of enzymes in the liver and kidney of all groups of rats were maintained within normal ranges, which demonstrate that the test extract had no membrane labializing effect on these organs. Enzyme activities in the tissues are mostly employed as marker to ascertain early toxic effects of administered substances to experimental animals. Alterations of the lipid profile also shows the efficacy and safety of plant extract. Any deviation in the concentration of lipids can provide information on the status of lipid metabolism as well as predisposition of the animals to atherosclerosis.<sup>33</sup> Cholesterol and triglycerides are

the lipid parameters associated with coronary artery diseases and are usually used to ascertain hyperlipidemic conditions.<sup>34</sup> In present study, the normal restoration of lipid parameters in the serum levels of extract treated rats not only indicate the nontoxic nature of the extract, but also implies that the tested extract may not dispose the animals to cardiovascular risk.

Analysis of organ weight in toxicology studies is an important endpoint for identification of potentially harmful effects of chemicals. A main requirement in toxicological experiments is the ability to assess the effects of xenobiotics on specific organs.<sup>35</sup> In this study, no changes were observed in gross examination of the organs of treated animals when compared to control group. The relative organ weight of the liver, kidney, heart, spleen, stomach, adrenal, duodenum, brain, colon and lungs recorded in the treatment groups did not show a significant difference as compared to the control group. This may imply that the extract did not alter the secretory ability of the organs. It is also possible that the extract did not cause any cellular constriction or inflammation of the organs which would have resulted in decrease or increase in their weight respectively.

Histopathological examination of the selected organs provide information to strengthen the findings of haematological and biochemical parameters. Microscopic examinations of sections of heart, liver, lungs, kidney, spleen, stomach, intestine and brain of all groups revealed no detectable abnormalities.

## **CONCLUSION:**

In conclusion, following sub-chronic treatment, the methanol (70%) seed extract of *A. precatorius* was well tolerated and produced no toxicity signs, lethality, impairments in body and organ weights or changes in food and water consumption. The extract also neither produced any signs of hepato-toxicity, nephro-toxicity or haemato-toxicity nor detectable abnormalities in lipid profile and histology of internal organs. Generally, all the values remained within the normal limits and did not suggest toxic effects in sub-chronic treatment. The present study, therefore, demonstrates the non-toxic nature of the test extract and thus, the 200 and 400 mg/kg doses may be used in phytomedical formulations with a low risk of adverse effects. However, further investigations like to determine its effect in pregnant animals as well as trial in other

animals towards the development of drugs from *A. precatorius* should be performed for its claimed traditional therapeutic values.

## CONFLICT OF INTEREST

Authors have no conflict of interest.

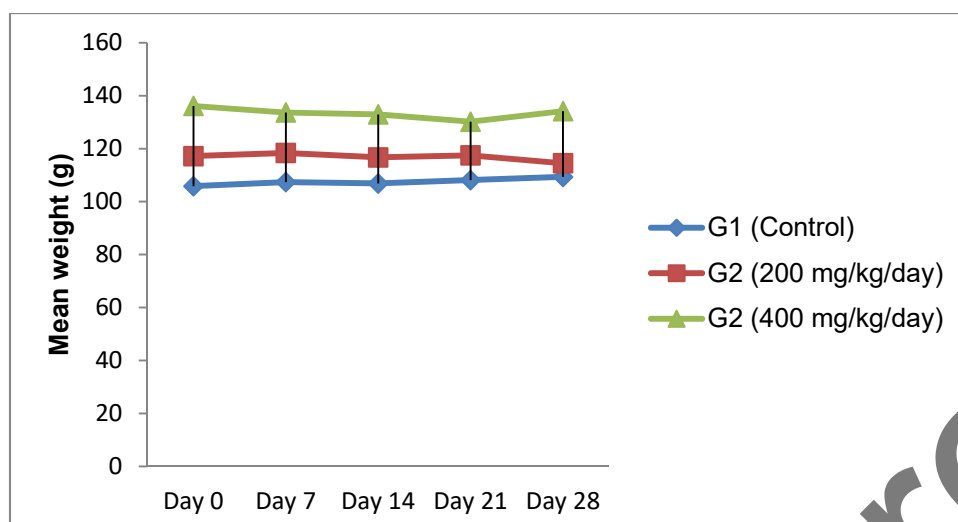
## REFERENCES:

1. Ping KW, Darah I, Chen Y, Sreeramanan S, Sasidharan S. Acute and sub-chronic toxicity study of *Euphorbia hirta* methanolic extract in rats. *BioMed Res Int*. 2013;2013:1-14.
2. Sathya M, Kokilavani R, Ananta TKS. Acute and sub-acute toxicity studies of ethanolic extract of *Acalypha indica* Linn. in male Wistar albino rats. *Asian J Pharm Clin Res*. 2012;5:97-100.
3. Shourie A, Kalra K. Analysis of phytochemical constituents and pharmacological properties of *Abrus precatorius* L. *Int J Pharma Bio Sci*. 2013;4:91-101.
4. Jahan S, Saeed N, Ijlal F, Khan MA, Ahmad M, Zafar M, Abbasi AM. Histomorphological study to evaluate anti-fertility effect of *Abrus precatorius* L. in adult male mice. *J Med Plants Res*. 2009;3:1021-028.
5. Acharya R, Roy S. A review on therapeutic utilities and purificatory procedure of Gunja (*Abrus precatorius* Linn.) as described in Ayurveda. *J AYUSH*. 2013; 2:1-11.
6. Chowdhury SR, Sharmin T, Hoque M, Sumsujjaman, Das M, Nahar F. Evaluation of Thrombolytic and membrane stabilizing activities of four medicinal plants of Bangladesh. *Int J Pharm Sci Res*. 2013;4:4223-4227.
7. Tilwari A, Shukla NP, Pathirissery UD. Immunomodulatory activity of the aqueous extract of seeds of *Abrus precatorius* Linn (Jequirity) in mice. *Iran J Immunol*. 2011;8:96-103.
8. Bhatia M, Siddiqui NA, Gupta S. *Abrus precatorius* (L.): An evaluation of traditional herb. *Indo American J Pharm Res*. 2013;3:3295-3315.

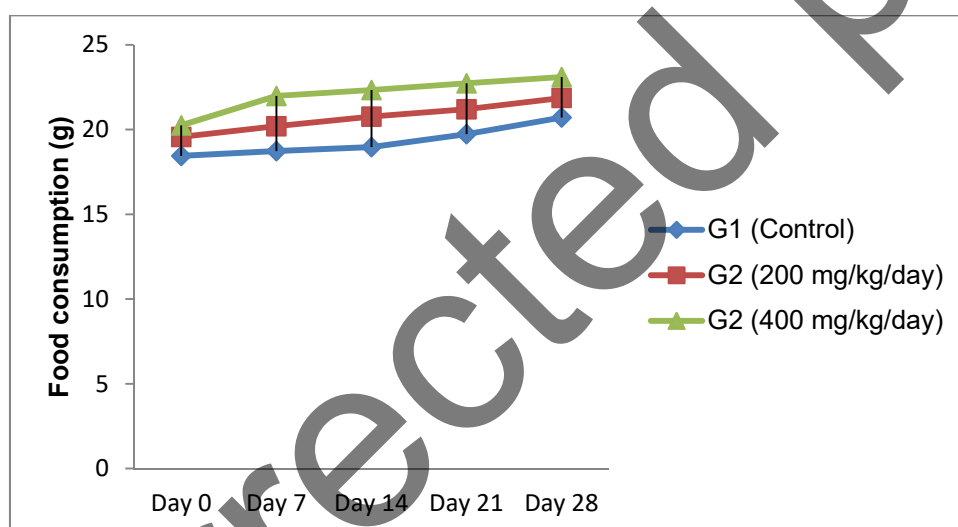
9. Garaniya N, Bapodra A. Ethano-botanical and phytopharmacological potential of *Abrus precatorius* L.: A review. Asian Pac J Trop Biomed. 2014;4:27-34.
10. Patil A, Vadera K, Patil D, Phatak A, Chandra N. Phytochemical analysis, *in-vitro* anticancer activity and HPTLC fingerprint profile of seeds of *Abrus precatorius* L. Int J Pharm Sci Rev Res. 2015;33:262-269.
11. Tabasum S, Khare S, Jain K. Spectrophotometric quantification of total phenolic, flavonoid and alkaloid contents of *Abrus precatorius* L. seeds. Asian J Pharm Clin Res. 2016;9:371-374.
12. Arora A. Anti-oogenic evaluation of seed extract of *Abrus precatorius* L. in swiss albino mice. Int Res J Biol Sci. 2013;2:27-30.
13. Singh RB, Shelly. Polysaccharide structure of degraded glucomannan from *Abrus precatorius* Linn. seeds. J Environ Biol. 2007;28:46-464.
14. Upadhyay S, Ghosh AK, Singh V. Anti-lice activity of *Abrus precatorius* Linn (FAM-Fabaceae) seed oil. Egypt Dermatol Online J. 2011;7:4.
15. Verma D, Tiwari SS, Srivastava S, Rawat AKS. Pharmacognostical evaluation and phytochemical standardization of *Abrus precatorius* L. seeds. Nat Prod Sci. 2011;17:51-57.
16. Chaudhari KS, Sharma R, Pawar PS, Kashikar VA. Pharmacological activities of *Abrus precatorius* Linn.- A review. Int J Ayur Herb Med. 2012; 2:336-348.
17. Rajani A, Hemamalini K, Begum SKA, Spandana KVLD, Parvathalu, Gowtham B. Antimicrobial activity and phytochemical study of ethanolic seed extract of *Abrus precatorius* Linn. J Biol Today's world. 2012;1:23-28.
18. Sivakumar R, Ravikumar K. Wound healing activity of two different forms of *Abrus precatorius* L. Int J Res Eng Biosci. 2013;1:39-53.
19. Anbu J, Ravichandiran V, Sumithra M, Chowdary BS, Kumar SKSLVSN, Kannadhasan R, Kumar S. Anticancer activity of petroleum ether extract of *Abrus precatorius* on Ehrlich Ascitis carcinoma in mice. Int J Pharm Bio Sci. 2011;2:24-31.

20. Mistry K, Mehta M, Mendpara N, Gamit S, Shah S. Determination of antibacterial activity and MIC of crude extract of *Abrus precatorius* L. Adv Biotech. 2010;10:25-27.
21. BobbaralaV, Vadlapudi V. *Abrus precatorius* L. seed extracts antimicrobial properties against clinically important bacteria. Int J PharmTech Res. 2009;1:1115-1118.
22. Monago CC, Alumanah EO. Antidiabetic effect of chloroform-methanol extract of *Abrus precatorius* Linn. seed in Alloxan diabetic rabbit. J Appl Sci Environ Manage. 2005;9:85-88.
23. Pal RS, Ariharashivakumar G, Girhepunje K, Upadhyay A. *In-vitro* antioxidative activity of phenolic and flavonoid compounds extracted from seeds of *Abrus precatorius*. Int J Pharm Pharm sci. 2009;1:136-140.
24. Ligha A, Jaja B, Numbere NF. Protective effect of *Abrus precatorius* L. seed extract following alcohol induced renal damage. Eur J Sci Res. 2009;25:428-436.
25. Sudaroli M, Chatterjee TK. Evaluation of red and white seed extracts of *Abrus precatorius* Linn. against Freund's complete adjuvant induced arthritis in rats. J Med Plants Res. 2010;1:86-94.
26. Saganuwan SA, Onyeyili PA, Ameh EG, Udok E. *In-vivo* antiplasmodial activity by aqueous extract of *Abrus precatorius* in mice. Rev Latinoamer Quim. 2011;39:32-44.
27. OECD, 2008. Guidelines for testing of chemicals/No. 407: Repeated dose oral toxicity test method, Organization for Economic Co-operation and Development, Paris, France.
28. Tabasum S, Khare S. Safety of medicinal plants: An important concern. Int J Pharma Bio Sci. 2016;7:237-243.
29. Shafi S, Tabassum N. Hepatic and hematological activities of hydro-alcoholic extract of *Eriobotrya japonica* fruits in Swiss albino mice. Int J Pharma Bio Sci. 2015;6:643-654.

30. Tan PV, Mezui C, Enow-Orock G, Njikam N, Dimo T, Bitolog P. Teratogenic effects, acute and sub-chronic toxicity of the leaf aqueous extract of *Ocimum suave* wild (Lamiaceae) in rats. J Ethnopharmacol. 2008;115:232-237.
31. Kebede S, Afework M, Debella A, Ergete W, Makonnen E. Toxicological study of the butanol fractionated root extract of *Asparagus africanus* Lam., on some blood parameter and histopathology of liver and kidney in mice. BMC Res Notes. 2016;9:49.
32. Goudah A, Abo-El-Sooud, Yousef MA. Acute and sub-chronic toxicity assessment model of *Ferula ass-foetida* gum in rodents. Vet World. 2015;8:584-589.
33. Sairam K, Priyambada S, Aryya NC, Goel RK. Gastroduodenal ulcer protective activity of *Asparagus racemosus*: an experimental, biochemical and histological study. J Ethnopharmacol. 2003;86:1-10.
34. Saibu S, Ashafa OTA. Toxicological implications and laxative potential of ethanol root extract of *Morella serrata* in loperamide-induced constipated Wistar rats. Pharm Biol. 2016;54:2901-2908.
35. Umana UE, Timbuak JA, Musa SA, Asala S, Hambolu J, Anuka JA. Acute and chronic hepatotoxicity and nephrotoxicity study of orally administered chloroform extract of *Carica papaya* seeds in adult Wistar rats. Int J Sci Res Publ. 2013;3(4):1-8.

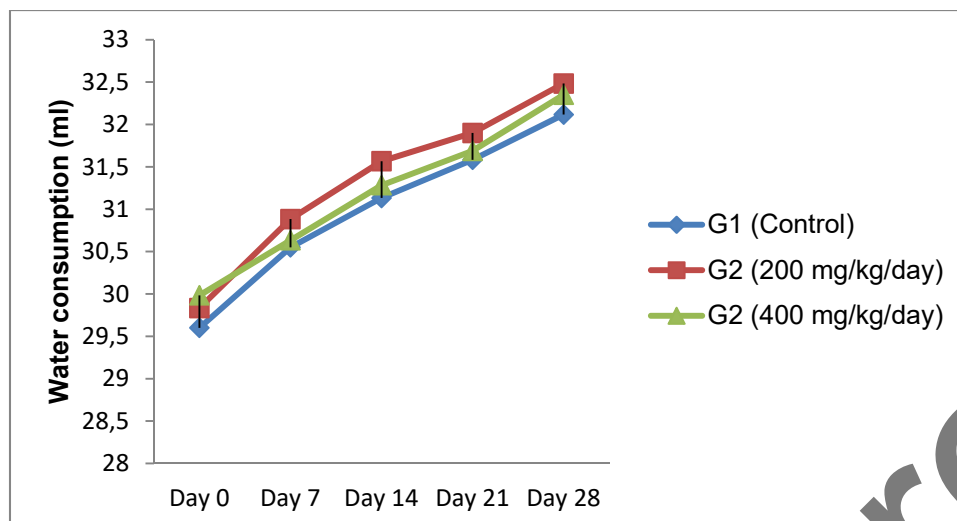


**Figure 1.** Changes in body weight of rats during sub-chronic toxicity study



**Figure 2.** Changes in food consumption of rats during sub-chronic toxicity study of methanol (70%) seed extract of *A. precatorius*





**Figure 3.** Changes in water consumption of rats during sub-chronic toxicity study of methanol (70%) seed extract of *A. precatorius*

**Table 1.** Effect on haematological parameters of rats administered with methanol (70%) seed extract of *A. precatorius*

Haematological Parameters	Group 1 (Control)	Group 2 (200 mg/kg/day)	Group 3 (400 mg/kg/day)
<b>A. Erythrocyte indices</b>			
HGB g/dL	11.6833±0.99401	11.4167±0.78191	10.8067±0.50006
RBC( ×10/ $\mu$ L)	6.495±0.34827	6.135±0.59779	5.73833±0.87959
HCT (%)	33.0333±11.56484	24.2667±6.294619	20.63333±7.247912
RDW(fL)	39.16667±2.361967	34.8333±4.399021	35.4±4.642916
MCV(fL)	59.6±2.442676	55.06667±4.454461	55.13333±1.966949
MCHC(g/dL)	30.73333±4.006106	37.23333±2.910708	36.69833±5.43031
<b>B. Thrombocyte indices</b>			
PLT( ×10/ $\mu$ L)	164.666±30.4119	249.666±127.853	279.5±146.459
PDW (%)	9.066667±0.827983	9.23333±0.696818	8.7±1.001665
MPV(fL)	9.716667±1.439232	9.716667±0.982203	8.28333±1.166786
P-LCR(%)	20.03333±5.948856	20.68333±2.319064	18.46667±2.1723
<b>C. Leucocyte indices</b>			

WBC( $\times 10/\mu\text{L}$ )	4.71666 $\pm$ 3.92785	3.21666 $\pm$ 1.66675	5.69833 $\pm$ 2.40555
LYM( $\times 10/\mu\text{L}$ )	3.1 $\pm$ 2.20605	1.71666 $\pm$ 0.43365	3.05 $\pm$ 1.16868
LYM(%)	71.2 $\pm$ 13.27717	61.23333 $\pm$ 15.20961	55.05 $\pm$ 8.147137

Values are expressed as mean  $\pm$  SD of six animals

**Table 2.** Effect on serum biochemical parameters of rats administered with methanol (70%) seed extract of *A. precatorius*

Parameter	Group 1 (Control)	Group2 (200 mg/kg/day)	Group 3 (400 mg/kg/day)
<b>A. Renal markers</b>			
BUN( mg/dl)	15.07667 $\pm$ 2.22464	14.38183 $\pm$ 6.688322	15.72833 $\pm$ 3.02106 2
Creatinine (mg/dl)	0.72533 $\pm$ 0.15052	0.73833 $\pm$ 0.18193	0.7675 $\pm$ 0.114176
Uric acid (mg/dl)	2.461833 $\pm$ 0.42735 3	3.426167 $\pm$ 1.670978	3.0385 $\pm$ 1.280693
<b>B. Hepatic markers</b>			
Total protein (g/dl)	5.509667 $\pm$ 0.50066 6	7.0215 $\pm$ 1.125476	6.672 $\pm$ 2.130268
Total Bilirubin (mg/dl)	0.23645 $\pm$ 0.64627	0.26395 $\pm$ 0.17536	0.29115 $\pm$ 0.088835
ALP (IU /l)	157.6767 $\pm$ 33.2871	168.4167 $\pm$ 3108203	165.5667 $\pm$ 209538 7
AST (IU /l)	167.1333 $\pm$ 31.3437 2	172.6322 $\pm$ 23.588	164 $\pm$ 1346601
ALT (IU /l)	39.673 $\pm$ 9803	47.595 $\pm$ 9.872	51.55333 $\pm$ 10.4776 1
<b>C. Lipid profile</b>			
Total cholesterol (mg/dl)	44.09667 $\pm$ 7.44965 2	49.15833 $\pm$ 12.1925	42.51333 $\pm$ 4.35354 9
Triglycerides (mg/dl)	52.765 $\pm$ 54.1075	58.12833 $\pm$ 8.903721	50.46 $\pm$ 10.90015

HDL (mg/dl)	48.59333±5.75348 5	49.58±12.66136	43.44±10.9195
LDL (mg/dl)	22.3919±5.490329	21.6345±5.390373	20.42133±6.25787 1

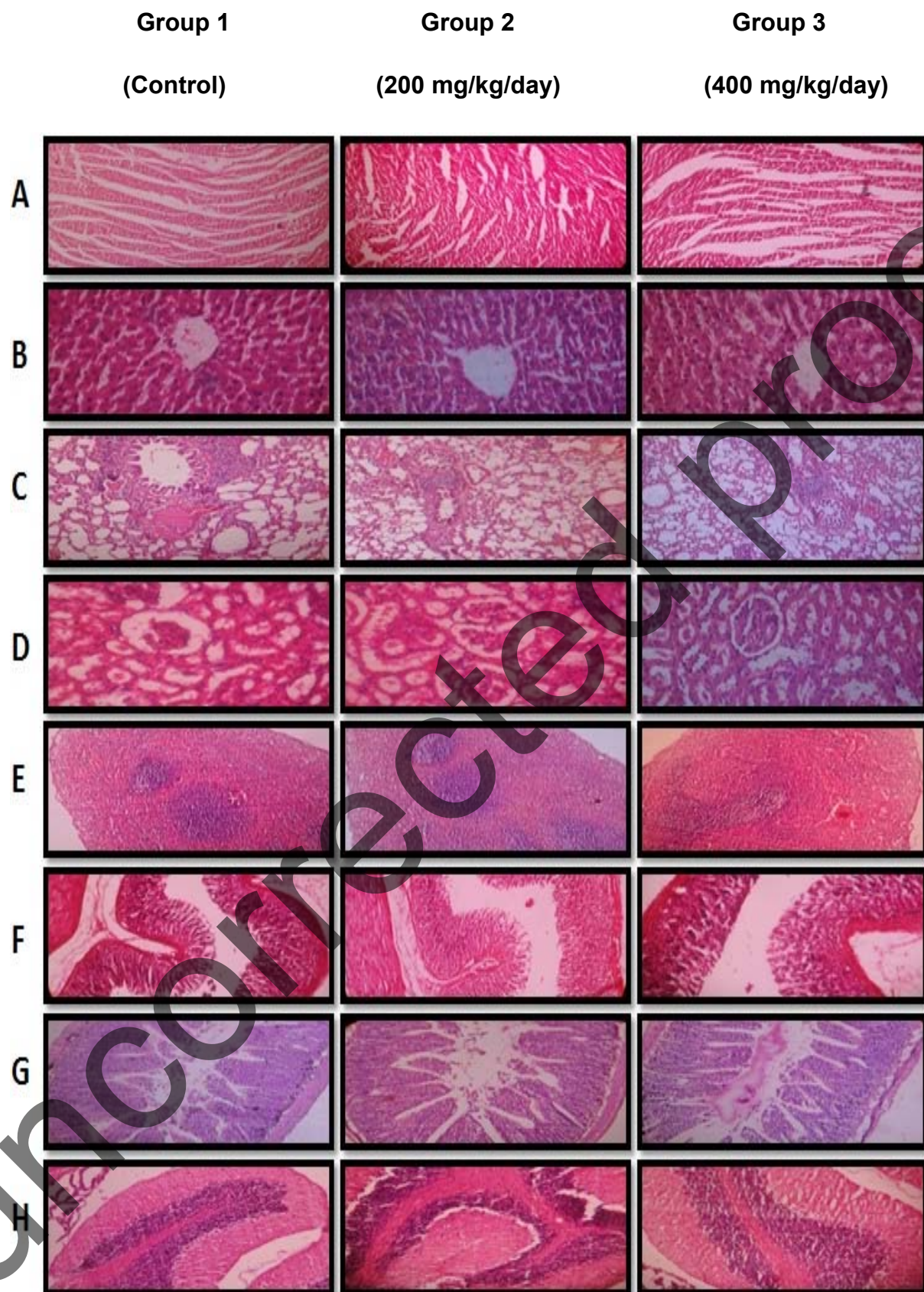
Values are expressed as mean ± SD of six animals

**Table 3.** Effect on relative organ weight of rats administered with methanol (70%) seed extract of *A. precatorius*

Organ name	Control	200mg/kg/day	400mg/kg/day
<b>Liver</b>	3.360333 ±0.202464	3.342167 ±0.160833	3.601167 ±0.22121
<b>R. Kidney</b>	0.5415 ±0.031154	0.530833 ±0.042148	0.524167 ±0.035611
<b>L. Kidney</b>	0.511667 ±0.018696	0.500333 ±0.034238	0.524167 ±0.035611
<b>Heart</b>	0.425333 ±0.055733	0.473333 ±0.052908	0.482667 ±0.074033
<b>Spleen</b>	0.437167 ±0.054066	0.374333 ±0.072304	0.497667 ±0.047971
<b>Stomach</b>	1.135333 ±0.083194	1.010333 ±0.136626	0.963833 ±0.145387
<b>Adrenal</b>	0.0375 ±0.007588	0.033 ±0.00611	0.0295 ±0.006922
<b>Duodenum</b>	0.8595 ±0.211821	0.9065 ±0.111439	0.754333 ±0.125298
<b>Brain</b>	1.293 ±0.192562	1.3015 ±0.125279	1.127333 ±0.071818
<b>Colon</b>	0.4825 ±0.179648	0.635833 ±0.151786	0.657333 ±0.082265
<b>Lungs</b>	1.074167 ±0.070416	1.0225 ±0.21034	1.040333 ±0.181494

Values are expressed as mean ± SD of six animals

Uncorrected proof



**Figure 4:** Effect of methanol (70%) seed extract of *A. precatorius* on various rat organ histomorphologies in sub-chronic toxicity study. [A: heart, B: liver, C: lungs, D: kidney, E: spleen, F: stomach, G: intestine, H: brain]

Uncorrected proof