



Case Report

Penetrating Trauma to the Parotid Region

Nurullah Seyhun, Aslı Batur Çalış, Suat Turgut

Department of Otorhinolaryngology Head and Neck Surgery, Sisli Hamidiye Etfal Training and Research Hospital, Istanbul, Turkey

Abstract

Penetrating trauma to the parotid gland is a rare condition. Mostly, gunshot wounds to the parotid area are seen. Facial paralysis and sialocele formation are particular concerns and may cause significant morbidities. Early diagnosis and early exploration are crucial in the setting of facial paralysis following penetrating trauma. Sialocele formation and fistulas can be managed conservatively or surgically.

Keywords: Bullet; parotid gland; parotid trauma.

Please cite this article as "Seyhun N, Batur Çalış A, Turgut S. Penetrating Trauma to the Parotid Region. Med Bull Sisli Etfal Hosp 2019;53(3):310–313".

Penetrating trauma to the parotid region is a rare condition and usually occurs after a gunshot injury, but can also be seen as a result of occupational accidents. Parotid tissue together with surrounding tissues, parotid duct, facial nerve, mandibular bone, and other adjacent structures may be damaged depending on the severity of penetrating trauma. Early diagnosis and intervention are important in minimizing complications. In this study, the diagnosis and treatment options are discussed in two different cases with penetrating trauma to the parotid region treated in our clinic.

Case Report

Case 1 – A 20-year-old male patient with a history of gunshot injury to his face happened a week ago was admitted to our clinic in March 2017 with the complaint of restricted mouth opening. On examination, vital signs were stable, left maxillary, the infraorbital lesion on the maxillary bone, consistent with the bullet entry hole, and a skin burn

measuring 1x1 cm were observed. Mouth opening was restricted and widespread tenderness and oedema were detected by palpation on the left temporomandibular joint and left maxillary region. The functions of the facial nerve of the patient were intact. The patient's brain and maxillo-facial tomography showed multiple segmental fracture lines in the anterior and lateral walls of the maxillary sinus, in the zygomatic process, in the mandible and the pterygoid process.

Diffuse air images and areas of hematoma were observed in the adjacent soft tissue. At the same time, a metallic foreign body image with a diameter of 1 cm was seen in the subcutaneous fatty tissues in the posterior neighborhood of the mandible on the left side (Fig. 1). The patient was evaluated by neurosurgery for cranial pathologies, and any pathological condition was not observed. To evaluate the patient as for orbital pathologies, consultation from the Department of Ophthalmology was requested and left orbital floor fracture and minimal bleeding in the left intraor-

Address for correspondence: Nurullah Seyhun, MD. Sisli Hamidiye Etfal Egitim ve Arastirma Hastanesi, Kulak Burun Boğaz ve Baş Boyun Cerrahisi Anabilim Dalı, Istanbul, Turkey

Phone: +90 212 373 50 00 **E-mail:** seyhun90@hotmail.com

Submitted Date: November 05, 2017 **Accepted Date:** November 16, 2017 **Available Online Date:** August 22, 2019

©Copyright 2019 by The Medical Bulletin of Sisli Etfal Hospital - Available online at www.sislietfaltip.org

OPEN ACCESS This is an open access article under the CC BY-NC license (<http://creativecommons.org/licenses/by-nc/4.0/>).



bital region were observed by the consultant ophthalmologist, and application of cold compresses and conservative approach were recommended. To remove the foreign body in the left parotid region, the patient underwent exploration of the left parotid region under general anesthesia. The foreign body was palpated in parotid tissue after application of modified Blair incision.

After identification of the main truncus of the facial nerve, its branches were followed and preserved. The bullet was not associated with the facial nerve, and it was confined to the superficial lobe (Fig. 2). After the bullet was removed from the superficial lobe, the drain was placed, and any perioperative complications were not observed. In the postoperative period, facial nerve functions were intact and the patient was discharged on the 4th day.

Case 2 – A 33-year-old male patient, who had an occupational accident as a result of metal machine tip fragmentation and had multiple penetrating traumatic lesions on his face, was admitted to the emergency department of an external center following the incident of trauma. The cut in the right preauricular region was sutured in the emergency department, and upon detection of a foreign body in the parotid region and paranasal sinuses, he was referred to our clinic in May 2017.

His physical examination revealed intact facial nerve functions and oedema in the right preauricular region and a previously sutured 2x2 cm wound site were observed. Any foreign body was not found during the examination of the nasal cavity. Examination of both ears was unremarkable, and paranasal sinus CT and temporal bone CT showed multiple metallic foreign body materials in the right parotid region and metallic foreign body materials in the ethmoid cells on the right side (Fig. 3). Any pathology was not detected in the middle and inner ear cavity. Any foreign body material was not detected in the temporal bone. It was decided that the patient's foreign body in the ethmoidal region should not be operated because of its proximity to the skull base and cribriform plate.

For the foreign body in the parotid region, the patient underwent right parotid exploration under general anesthesia. Following the modified Blair incision, the trajectory of the foreign body was seen while the flap elevation was performed in the preauricular region and the foreign body was taken over the superficial parotid lobe (Fig. 4). The main truncus and branches of the facial nerve were intact and in their normal location. The drain was inserted and any perioperative complications were not observed. Postoperative facial nerve functions were intact, and the patient was discharged on the 4th postoperative day.

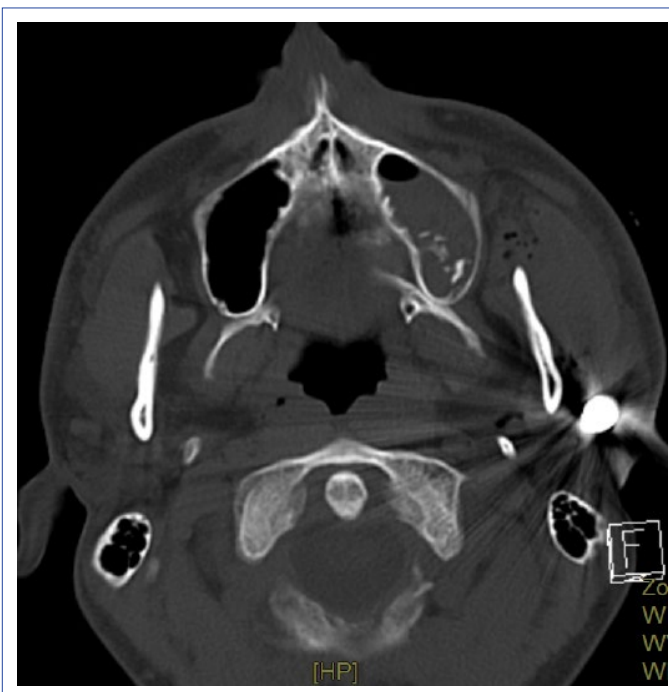


Figure 1. Foreign body image in the superficial lobe of the parotid adjacent to the posterior aspect of the left mandibular condyle on the maxillofacial tomography.

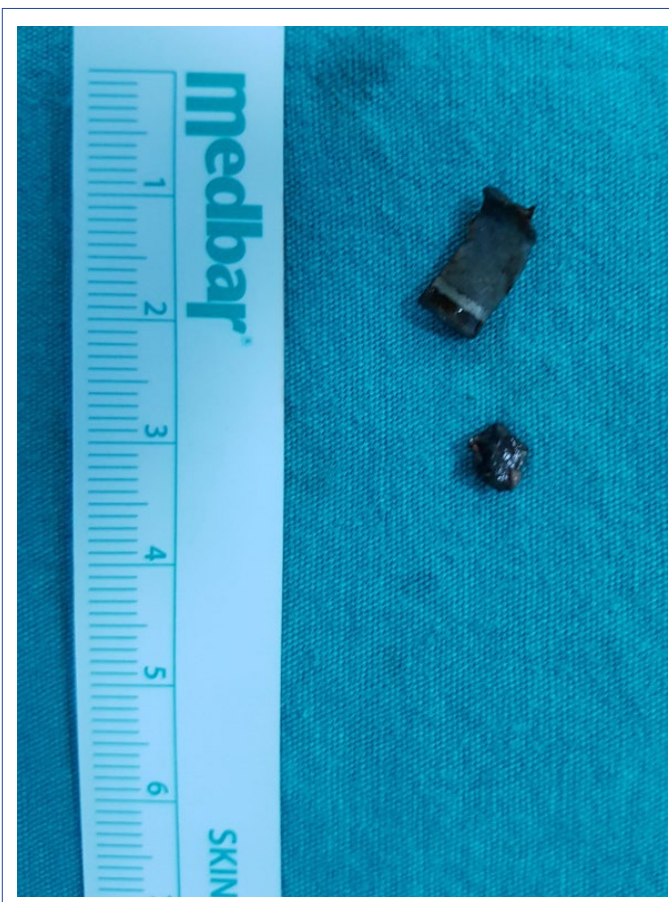

Figure 2. Bullet extracted from the superficial lobe of the left parotid.

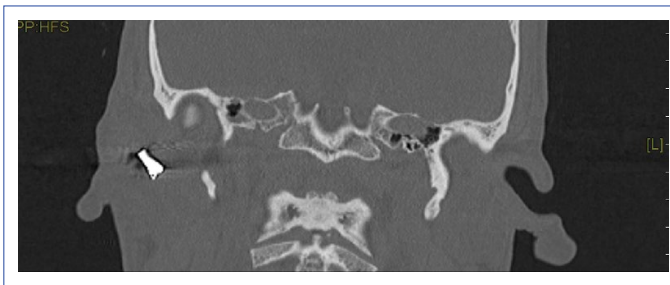


Figure 3. Image of the metallic foreign body in the right parotid region.

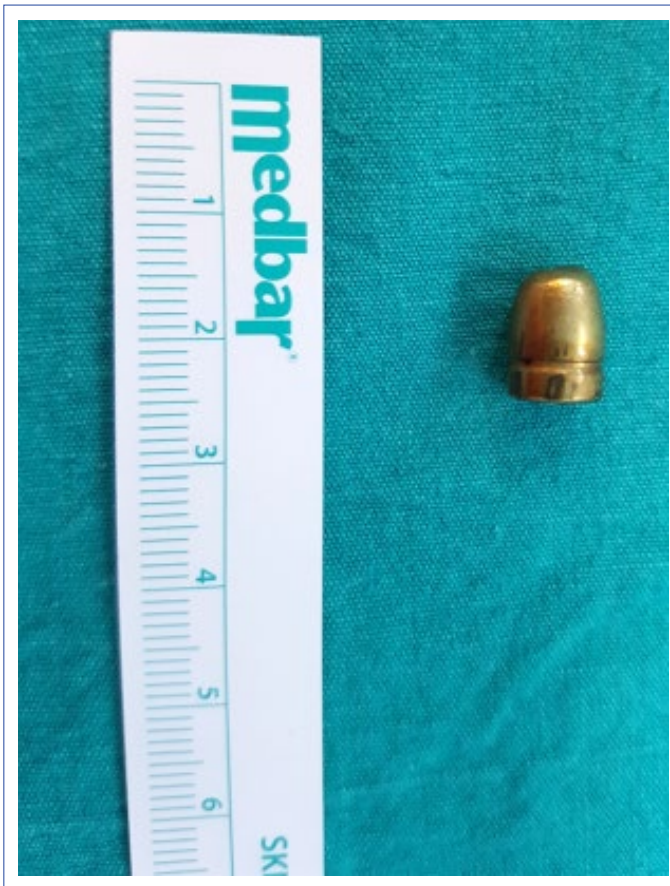

Figure 4. Bullet extracted from the superficial lobe of the right parotid gland.

Discussion

Penetrating injuries of the parotid region may cause serious morbidity due to damage to the facial nerve and Stenson canal. In gunshot wounds, necrosis and infection related to the damage caused by the bullet in the surrounding tissues may also be encountered. Early diagnosis and treatment are of considerable importance to avoid delayed reconstruction, especially in cases of facial nerve damage. In cases of suspicion of Stenson's duct damage, to assure whether the duct is damaged or not perioperatively saline or dye is injected into the duct.^[1] In cases of bleeding due to injury, since vascular structures are located close to

the facial nerve and its branches, it is not recommended to ligate or cauterize structures that are thought to be vascular structures without mastering anatomy because of the possibility of iatrogenic facial nerve damage.^[2]

According to a study by Tachmes et al.,^[3] 56 % of penetrating injuries of the parotid gland present with conditions, such as sialoceles, salivary fistula and infection, between a few days and a few weeks after the incident. Our cases presented to our clinic after one and two weeks after the trauma, but still, any sialocele or salivary fistula was not observed.

Sialocele is the collection of saliva in subcutaneous tissue, and as a result of this collection, fistulas may develop. Surgical and medical treatment approaches can be applied in penetrating traumas manifesting with salivary fistula. Generally, after assessing the extent of damage and repairing the damage in the Stenson's canal, stent placement is preferred, followed by prescription of compressive dressing and anti-sialogogue drugs.^[4] However, there are also several studies in the literature that showed that stent placement is not necessary after repairing Stenson's duct.^[5] Sialography can also be used to detect damage to the Stenson's duct. In a study by Gok et al.,^[6] it was reported that intraparenchymal Botulinum Toxin A injection was effective and more comfortable for the patient with salivary fistula. In cases where the facial nerve is damaged, early exploration and end-to-end anastomosis should be performed immediately after the patient has stabilized. Nerve monitor can be used in explorations performed within the first 72 hours, but it will be difficult to recognize the facial nerve and its branches with the nerve monitor since the amount of neurotransmitter will be depleted after this time.^[7] In cases where end-to-end anastomosis could not be performed because of severe damage and tissue loss, repair with interpositional nerve graft is recommended.^[8] Infections may occur after firearm injuries of the parotid region. Due to the necrosis of the surrounding tissues, especially the risk of anaerobic bacterial infection increases. To avoid infection, the wound should be irrigated extensively; foreign bodies should be removed, necrotic tissues should be debrided. Indeed, early treatment has been shown to be very effective in avoiding infection.^[9] Generally, infections due to gram-positive and anaerobic bacteria are seen and cefazolin, ceftriaxone and clindamycin have been reported to be effective. The use of broad-spectrum antibiotics is not recommended as it increases antibiotic resistance and they do not provide additional benefits. Perioperative prophylaxis has also been shown to reduce infection risk from 28-87% to 6-10%.^[10]

Conclusion

In conclusion, penetrating traumas of the parotid region are not very common, and the number of studies on this subject is limited. Significant morbidities may occur as a result of the facial nerve and Stenson canal injuries and severe bleeding, and early surgical exploration is necessary to prevent these morbidities. When the foreign body is removed from the parotid region, the removal of the foreign body after having fully mastered the anatomy of the facial nerve is important for preventing iatrogenic damage of the facial nerve. Facial nerve repair is required within the first 72 hours in patients with facial nerve paralysis. In this study, we present two different cases of penetrating traumas to the parotid in the late period. In this regard, larger series of research should be conducted regarding diagnosis and treatment.

Disclosures

Informed Consent: Written informed consent was obtained from the patient for the publication of the case report and the accompanying images.

Peer-review: Externally peer-reviewed.

Conflict of Interest: None declared.

Authorship Contributions: Concept – N.S., A.B.Ç.; Design – N.S., A.B.Ç.; Supervision – S.T.; Materials – N.S.; Data collection &/or processing – N.S., A.B.Ç.; Analysis and/or interpretation – A.B.Ç., S.T.; Literature search – A.B.Ç., S.T.; Writing – N.S., A.B.Ç.; Critical review – N.S., A.B.Ç., S.T.

References

1. Van Sickels JE. Management of parotid gland and duct injuries. *Oral Maxillofac Surg Clin North Am* 2009;21:243–6. [\[CrossRef\]](#)
2. Youngs RP, Walsh-Waring GP. Trauma to the parotid region. *J Laryngol Otol* 1987;101:475–9. [\[CrossRef\]](#)
3. Tachmes L, Woloszyn T, Marini C, Coons M, Eastlick L, Shaftan G, et al. Parotid gland and facial nerve trauma: a retrospective review. *J Trauma* 1990;30:1395–8. [\[CrossRef\]](#)
4. Lewkowicz AA, Hasson O, Nahlieli O. Traumatic injuries to the parotid gland and duct. *J Oral Maxillofac Surg* 2002;60:676–80.
5. Stevenson JH. Parotid duct transection associated with facial trauma: experience with 10 cases. *Br J Plast Surg* 1983;36:81–2.
6. Gok G, Michl P, Williams MD, Howlett DC. Ultrasound-guided botulinum toxin injection to treat a parotid fistula following gunshot injury. *J R Army Med Corps* 2015;161:64–6. [\[CrossRef\]](#)
7. Myckatyn TM, Mackinnon SE. The surgical management of facial nerve injury. *Clin Plast Surg* 2003;30:307–18. [\[CrossRef\]](#)
8. Davis RE, Telischi FF. Traumatic facial nerve injuries: review of diagnosis and treatment. *J Craniomaxillofac Trauma* 1995;1:30–41.
9. Remick KN, Jackson TS. Trauma evaluation of the parotid duct in an austere military environment. *Mil Med* 2010;175:539–40.
10. Gruss JS, Antonyshyn O, Phillips JH. Early definitive bone and soft-tissue reconstruction of major gunshot wounds of the face. *Plast Reconstr Surg* 1991;87:436–50. [\[CrossRef\]](#)