



Case Report

Closure of a Large Lumbosacral Defect with Reverse Turnover Latissimus Dorsi Muscle Flap and Bilateral Bipedicle Flap: A Case Report

Ali Can Gunenc,¹ Kamuran Zeynep Sevim,¹ Yunus Ertas,¹ Akif Albayrak,² Fatih Irmak¹

¹Department of Plastic, Reconstructive and Aesthetic Surgery, University of Health Sciences Turkey, Sisli Hamidiye Etfal Teaching and Research Hospital, Istanbul, Turkey

²Department of Orthopedics and Traumatology, Metin Sabancı Baltalımanlı Bone Diseases, Training and Research Hospital, Istanbul, Turkey

Abstract

Closure of tissue defects after surgical interventions applied to the lumbosacral region appears as a challenging procedure. Latissimus dorsi muscle flap is also among the frequently used flaps for lum-bosacral defects. According to the defect, the latissimus dorsi muscle can be elevated as a major pedi-cle from over the thoracodorsal artery and vein, as well as segmental pedicles from over the intercostal artery perforators. Latissimus dorsi muscle flap elevated as a segmental pedicle is not frequently used; however, it is very useful in closing lumbosacral defects that do not have many alternatives for their closure. In this study, a case of reconstruction with reverse turnover latissimus dorsi muscle flap and bilateral bipedicle skin flap of a patient, who was previously operated due to scoliosis and had tissue defect with the exposed fixator in the midline back. A 35-year-old female patient with scoliosis de-formity was previously operated due to scoliosis when she was 1-year old. About one year ago, a revision was required and new fixators were placed at an external center. Afterwards, the patient who developed tissue defect with the exposed fixator underwent debridement three times and vacuum-assisted closure (VAC) device treatment was performed. The patient, who was referred to us due to the defect which was not closing, was reconstructed with reverse turnover latissimus dorsi muscle flap and bilateral bipedicle skin flap. The procedures applied during the operation and postoperative follow-up results were examined. Latissimus dorsi flaps resting on secondary segmental vessels, which are named as "reverse" or "distal-based" latissimus dorsi flaps, were used to repair defects of spinal, lumbar and upper sacral regions. In most cases, the skin is not required and it is transferred as a muscle flap, and is performed as a transposition flap. The reverse turnover latissimus dorsi muscle flap ensures the successful repair of large defects of the lumbar region without microvascular anasto-mosis.

Keywords: Latissimus dorsi flap; lumbosacral defect; scoliosis.

Please cite this article as "Gunenc AC, Sevim KZ, Ertas Y, Albayrak A, Irmak F. Closure of a Large Lumbosacral Defect with Reverse Turnover Latissimus Dorsi Muscle Flap and Bilateral Bipedicle Flap: A Case Report. Med Bull Sisli Etfal Hosp 2020;54(3):380–383".

The repair of lumbosacral defects that occur after surgery is a challenging situation. In large lumbosacral defects, flap repair provides sufficient blood flow, fills the dead space and provides an appropriate soft tissue cover.^[1] Many

flaps have been defined according to the location of the defect, such as superior gluteal artery flap, trapezius flap, latissimus dorsi muscle flap and paraspinal muscle flaps.^[2, 3] Latissimus dorsi is a muscle responsible for extension, ad-

Address for correspondence: Ali Can Gunenc, MD. Sisli Hamidiye Etfal Egitim ve Arastirma Hastanesi, Plastik, Rekonstruktif ve Estetik Cerrahi Klinigi, Istanbul, Turkey

Phone: +90 507 707 47 38 **E-mail:** alicangunenc@gmail.com

Submitted Date: August 14, 2018 **Accepted Date:** November 09, 2018 **Available Online Date:** September 04, 2020

©Copyright 2020 by The Medical Bulletin of Sisli Etfal Hospital - Available online at www.sislietfaltip.org

OPEN ACCESS This is an open access article under the CC BY-NC license (<http://creativecommons.org/licenses/by-nc/4.0/>).



duction and internal rotation of the arm in the back region. Latissimus dorsi muscle attaches to the dorsal iliac crest, with the last six thoracic vertebrae, lumbar and sacral vertebrae via the thoracolumbar fascia. It attaches to humerus with the teres major and pectoralis muscles. It leads to the posterior axillary line with the teres major muscle. Its main pedicle is the thoracodorsal artery, which is a branch of the subscapular artery, and the pedicular flap is usually transferred over this artery.^[4] The length of the non-muscular part of the vein can vary from six to 16 cm, having an average length of 9 cm. The thoracodorsal artery mainly feeds the proximal part of the latissimus dorsi muscle, the distal part is fed by the intercostal artery perforators.^[5] In cases where the latissimus dorsi muscle is desired to close the midline defects, the latissimus dorsi turnover flap fed by intercostal artery perforators can be used according to the location of the defect.^[6, 7] Other pedicle flaps from muscle and skin tissue in the lumbar region can also be used to repair defects in this area.^[8]

In this study, the reconstruction of a patient who was previously operated due to scoliosis and who had tissue defect with exposed fixator in the back midline, with reverse turnover latissimus dorsi muscle and bilateral bipedicle fasciocutaneous flap, was presented. The patient's consent was obtained for this case study.

Case Report

A 35-year-old female patient with scoliosis deformity was previously operated due to scoliosis when she was 1-year old. Approximately one year ago, a revision was required and new fixators were placed at an external center. The patient was planned to be operated at a level between T5-S1 by ortho-pedics. Two rods of 40 cm were placed by giving the appropriate kyphosis and lordosis angle between T5 and S1. Kyphectomy was performed by applying osteotomy to T11-T12 and L1 levels and a cage was placed. Then, two more rods were added. The wound started to open in the first postoperative month. The patient was followed with a dressing application for a while. The patient underwent debridement for three times and vacuum-assisted closure (VAC) device treatment for a while, and then referred to our clinic due to the persistence of the non-closure of the defect (Fig. 1).

The skin was thin and tense due to the patient's previous operations. Also, due to the large size of the fixator placed in the previous operation and to prevent it from becoming infected, a muscle tissue with high blood flow was needed. Therefore, the latissimus dorsi muscle was chosen. If the latissimus dorsi muscle had been transferred over the major pedicle, the thoracodorsal artery and vein,

the rotation arc would have been limited and only part of the defect could have been closed. Thus, the flap was transferred from over the intercostal artery perforators, which are minor pedicles due to their convenience in terms of muscle rotation arc (Fig. 2).

Latissimus dorsi muscle was reached through the incision made from the lateral border of the latissimus dorsi muscle. The dissection was advanced and the latissimus dorsi muscle was exposed. The muscle flap was separated from the chest wall laterally. The latissimus dorsi muscle was separated from the scapular and paraspinal muscles dorsally. After the muscle flap was elevated, three veins originating from the 8th, 9th and 10th ribs were confirmed to feed the muscle 5 cm lateral to the midline. The cephalic region of the muscle origin was released about 7 cm away from the protrusion of the spinous process to perform inferior rotation. The flap was then transferred from the identified pivot line. Circulation was observed in the flap that was elevated. The flap was seen to completely cover the fixator (Fig. 3). The incision in the right posterior axillary line, which was previously performed for flap elevation, was extended and the bipedicle flap was elevated. It was elevated until the defect at the midline, including the muscle fascia with the incision planned from the posterior axillary line on the left side. As the right latissimus dorsi muscle was transferred to the defect, the bipedicle flap could be primarily sutured without any donor area tension. Partial-thickness skin graft from the left thigh was adapted to the left side bipedicle skin flap (Fig. 4).

Two negative-pressure drains were placed. The left drain was removed when the fluid level dropped below 30 cc on the 3rd postoperative day. The right drain was kept until the 10th day due to the latissimus muscle elevation, to prevent a seroma. The patient was asked to lie face down postoperatively and was not mobilized for two days. No complications were observed during the postoperative follow-up of the patient (Fig. 5).

The patient was informed at all stages and an informed consent form was obtained.

Discussion

"Reverse" or "distal-based" latissimus dorsi flap, which is elevated according to the secondary segmental vessels, has been used to repair defects of the spinal, lumbar and upper sacral regions.^[9, 10] In most cases, the skin part is not required, and it is transferred as a muscle flap and is performed by muscle transposition. This conventional reverse flap is usually designed to be transverse on a segmental pedicle because the arc of flap rotation is significantly restricted when more than two segmental pedicles are included.^[11]

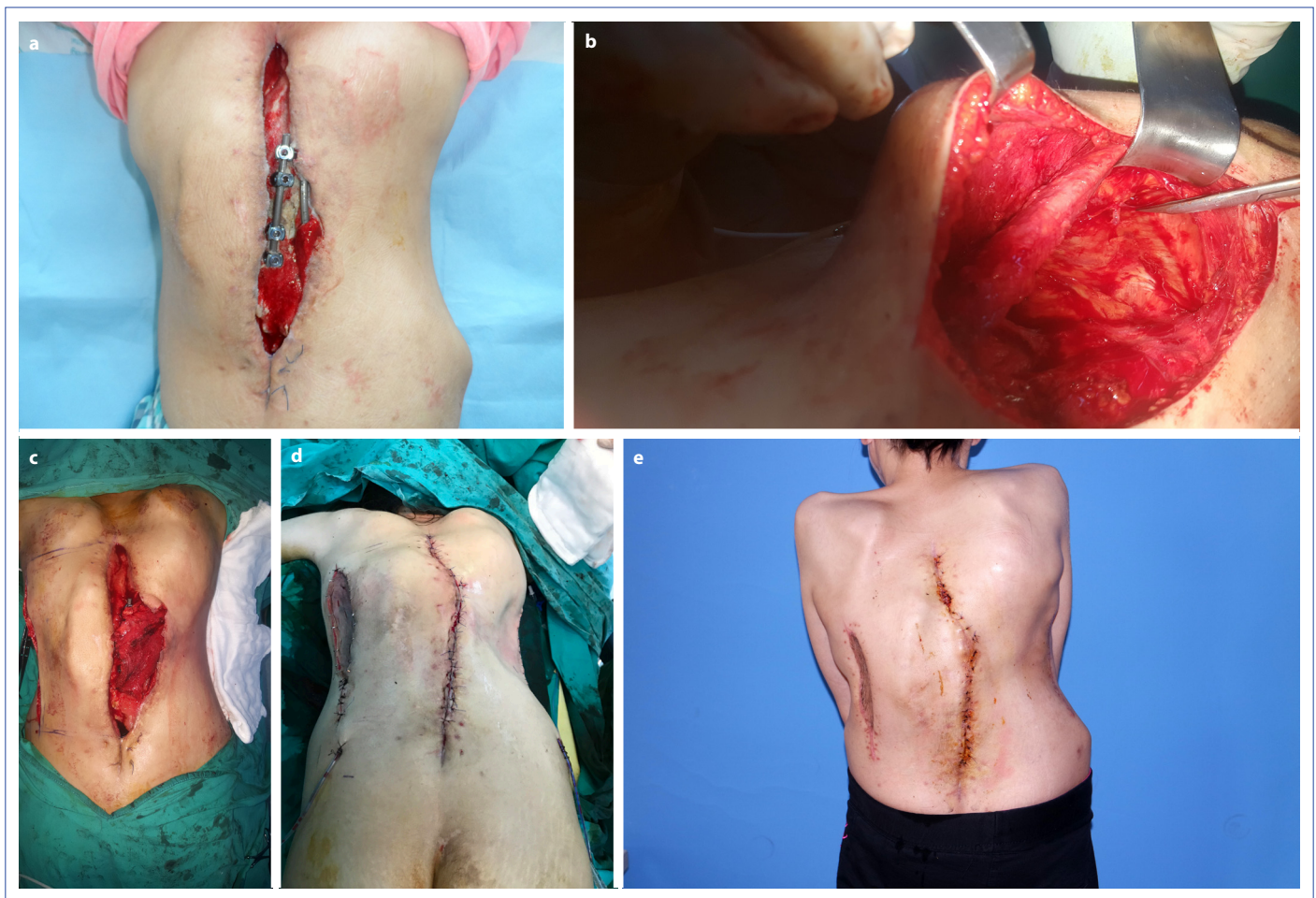


Figure 1. Preoperative image of the patient (a), Peroperative image of the patient (b), Peroperative image of the flap (c), Early postoperative image of the patient (d), Postoperative 1st-month image of the patient (e).

In our case, flap mobility was sufficient, and the flap was transferred over three segmental pedicles. An ipsilateral latissimus dorsi muscle is often sacrificed in large defects in the lumbar region. However, due to these features of the traditional latissimus dorsi flap, it is difficult to apply this flap on the midline and in closing the large defects of the contralateral side. On the other hand, when it is in the reverse latissimus dorsi muscle flap form, the defect is closed easily and reliably. Other flaps, such as gluteus maximus muscle, can also be used in this way.^[12]

Segmental perforators generally originate from the 9th, 10th and 11th in-tercostal vessels, 5 cm lateral to the midline according to Stevenson et al.,^[9] and on 7th, 9th and 11th thoracic vertebrae level according to McCraw et al.^[13] In our case, perforators were found at the 8th, 9th and 10th thoracic vertebrae level, in parallel with these studies. Watanabe et al.^[14] stated in their study that two distal-based perforators were sufficient for circulation. Hayashida et al.^[15] published a case report showing that only the flap transferred over the 10th perforator stayed alive.

Conclusion

The reverse turnover flap of the latissimus dorsi muscle ensures successful repair of a large defect of the lumbar region without microvascular anastomosis. Latissimus dorsi muscle transfer can be a very powerful and valuable method of repairing lumbar defects as long as the unilateral segmental pedicles of one side are preserved. In addition, when repairing a muscle flap, it is essential that we carefully plan our options and carefully plan our surgery, considering the possibility that the patient's defect may be reopened in the long term.

Disclosures

Informed Consent: Written informed consent was obtained from the patient for the publication of the case report and the accompanying images.

Peer-review: Externally peer-reviewed.

Conflict of Interest: None declared.

Authorship Contributions: Concept – K.Z.S., A.C.G.; Design – A.C.G.; Supervision – K.Z.S.; Materials – A.A.; Data collection &/or

processing – F.I., Y.E.; Analysis and/or interpretation – A.C.G., A.A.; Literature search – F.I., A.A.; Writing – A.C.G., Y.E.; Critical review – K.Z.S., F.I.

References

1. Söyüncü Y, Bigat Z, Söyüncü İ, Özkan Ö. Omentum and reverse turnover latissimus dorsi musculocutaneous flap for the treatment of cerebrospinal fluid fistula. *Acta Orthop Traumatol Turc* 2015;49:571–5.
2. Hochberg J, Ardenghy M, Yuen J, Gonzalez-Cruz R, Miura Y, Conrado RM, et al. Muscle and musculocutaneous flap coverage of exposed spinal fusion devices. *Plast Reconstr Surg* 1998;102:385–92.
3. de Fontaine S, Gaede F, Berthe JV. The reverse turnover latissimus dorsi flap for closure of midline lumbar defects. *J Plast Reconstr Aesthet Surg* 2008;61:917–24.
4. Bartlett SP, May JW Jr, Yaremchuk MJ. The latissimus dorsi muscle: a fresh cadaver study of the primary neurovascular pedicle. *Plast Reconstr Surg* 1981;67:631–6.
5. Fisher J, Bostwick J 3rd, Powell RW. Latissimus dorsi blood supply after thoracodorsal vessel division: the serratus collateral. *Plast Reconstr Surg* 1983;72:502–11.
6. de Fontaine S, Gaede F, Berthe JV. The reverse turnover latissimus dorsi flap for closure of midline lumbar defects. *J Plast Reconstr Aesthet Surg* 2008;61:917–24.
7. Yamamoto N, Igota S, Izaki H, Arai K. "Reverse turnover" transfer of a latissimus dorsi muscle flap to a large lumbar defect. *Plast Reconstr Surg* 2001;107:1496–9.
8. Hill C, Riaz M. A new twist to the myocutaneous turnover flap for closure of a spinal defect. *Plast Reconstr Surg* 1998;102:1167–70.
9. Stevenson TR, Rohrich RJ, Pollock RA, Dingman RO, Bostwick J 3rd. More experience with the "reverse" latissimus dorsi musculocutaneous flap: precise location of blood supply. *Plast Reconstr Surg* 1984;74:237–43.
10. Schefflan M, Mehrhof AI Jr, Ward JD. Meningomyelocele closure with distally based latissimus dorsi flap. *Plast Reconstr Surg* 1984;73:956–9.
11. Bostwick J 3rd, Schefflan M, Nahai F, Jurkiewicz MJ. The "reverse" latissimus dorsi muscle and musculocutaneous flap: anatomical and clinical considerations. *Plast Reconstr Surg* 1980;65:395–9.
12. Stallings JO, Delgado JP, Converse JM. Turnover island flap of gluteus maximus muscle for the repair of sacral decubitus ulcer. *Plast Reconstr Surg* 1974;54:52–4.
13. McCraw JB, Penix JO, Baker JW. Repair of major defects of the chest wall and spine with the latissimus dorsi myocutaneous flap. *Plast Reconstr Surg* 1978;62:197–206.
14. Watanabe K, Kiyokawa K, Rikimaru H, Koga N, Yamaki K, Saga T. Anatomical study of latissimus dorsi musculocutaneous flap vascular distribution. *J Plast Reconstr Aesthet Surg* 2010;63:1091–8.
15. Hayashida K, Endo Y, Kamebuchi K. Case report reconstruction of exposed ilium with reverse turnover latissimus dorsi muscle flap. *Eplasty* 2011;11:e17.