



Sarcoidosis Presenting with Pleural Involvement

Plevral Tutulum ile Seyreden Sarkoidoz

Hatice Kutbay Özçelik,¹ Mehmet Bayram,¹ Nur Pınar Büyükbashi,² Abdullah Kansu,¹ Muhammed Emin Akkoyunlu,¹ Murat Sezer,¹ Fatmanur Karaköse,¹ Fatih Yakar,¹ Levent Kart¹

Abstract

Sarcoidosis is a multisystemic, granulomatous disease with particular involvement in the lungs and intrathoracic lymph nodes. The prevalence of pleural fluid occurs in 0-5% of the cases in the literature. Diagnosis depends on non-caseating granulomas in biopsy and the exclusion of other possible reasons. A 26-year-old male admitted with cough and left sided chest pain. Physical examination was normal except a decrease in respiratory sounds at left hemithorax. Chest x-ray showed bilateral hilar enlargement, pleural fluid in the left hemithorax, and non-homogenous density in the left upper zone. Video-assisted thoracoscopic surgery (VATS) was performed because the patient couldn't tolerate bronchoscopy. Histopathological examination of samples reported non-necrotizing granulomatous inflammation. Methylprednisolone (0.5 mg/kg/day) was started. Regression of lymphadenopathies, pleural effusion and paranchymal opacities were present at the 5th month of therapy. This case emphasizes the possibility of sarcoidosis in patients with pleural effusion, even in places where tuberculosis prevalence is high.

Key words: Sarcoidosis, pleural effusion, video-assisted thoracoscopy.

Özet

Sarkoidoz, nedeni bilinmeyen, en sık akciğerleri ve intratorasik lenf nodlarını tutan, multisistemik, nonkazeifiye granülatöz bir hastalıktır. Literatürde plevra sıvısı görülme sıklığı %0-5 arasında bildirilmektedir. Tanı plevra biyopsisinde kazeifikasyon nekrozu içermeyen granülom gösterilmesi ve granülom yapan diğer nedenlerin dışlanması ile konulur. Kuru öksürük ve sol yan ağrısı şikâyeti ile polikliniğe başvuran 26 yaşında erkek hastanın fizik muayenesinde sol hemitoraksta solunum seslerinde azalma dışında diğer sistem muayenelerinde özellik yoktu. Akciğer grafisinde; bilateral hiler genişleme, solda plevral efüzyon ve sol üst zonda nonhomojen dansite artışı tespit edildi. Bronkoscopiye tolere edemeyen hastaya video yardımlı torakoskopi (VATS) uygulandı. Plevra ve mediastinal lenf bezi örnekleri histopatolojisi nekrozlaşmayan granülatöz iltihap, sarkoidoz ile uyumlu olarak raporlandı. Metilprednisolon (0,5 mg/kg/gün) başlanan hastanın akciğer grafisindeki lezyonlarda regresyon tespit edildi. Plörezi tespit ettiğimiz hastalarda, tüberküloz insidansı yüksek olan yerlerde bile sarkoidozun akla gelmesi açısından bu olguyu sunmayı uygun bulduk.

Anahtar Sözcükler: Sarkoidoz, plevral efüzyon, video yardımlı torakoskopi.

¹Department of Chest Diseases, Bezmialem Vakıf University, İstanbul, Turkey

²Department of Pathology, Bezmialem Vakıf University, İstanbul, Turkey

¹Bezmialem Vakıf Üniversitesi, Göğüs Hastalıkları Anabilim Dalı, İstanbul

²Bezmialem Vakıf Üniversitesi, Patoloji Anabilim Dalı, İstanbul

Submitted (Başvuru tarihi): 06.03.2013 **Accepted (Kabul tarihi):** 14.06.2013

Correspondence (İletişim): Hatice Kutbay Özçelik, Department of Chest Diseases, Bezmialem Vakıf University, İstanbul, Turkey

e-mail: hkutbay54@hotmail.com



Sarcoidosis is a multisystemic, noncaseating granulomatous disease with an unknown etiology that commonly affects the lungs and intrathoracic lymph nodes (1). Sarcoidosis is generally seen in adults between 20 and 40 years of age, with a second peak evident in women over 50 (2). Diagnosis is made by evidence of non-necrotizing granulomas histopathologically, together with clinical and radiological findings. The most frequently involved extrathoracic organs are the eyes, skin, heart, nervous system, and kidneys. Pleural involvement in sarcoidosis is rare, but pleural fluid, pneumothorax, pleural thickening and nodules, hydropneumothorax, and chylothorax may be seen (3). Clinically significant pleural involvement is found in 2-4% of the patients (4). Pleural fluid is reported as 0.7-10% (5). Sarcoidosis-related pleural fluid is rare; therefore, when pleural fluid is detected in a patient with sarcoidosis, other pleural pathologies should first be discarded. A definitive diagnosis is made by showing granuloma that does not include caseification necrosis in the pleura biopsy and excluding other reasons causing granuloma (4).

The current case is presented with pleural effusion to emphasize that in the process diagnosing a patient, sarcoidosis should also be kept in mind, even in places where tuberculosis prevalence is high.

CASE

A 26-year-old male patient presented to the polyclinic with a dry cough and left side pain. His physical examination revealed diminished lung sounds in the left hemithorax. His chest radiogram revealed bilateral hilar enlargement, pleural effusion in the left side, and an increase in non-homogenous density in the left upper zone (Figure 1). No pathological finding was disclosed by the biochemistry and complete blood count; erythrocyte sedimentation rate was 53 mm/h. His electrocardiogram showed a normal sinus rhythm and the tuberculin skin test was negative. Thoracentesis was performed. Pleural fluid biochemistry was compatible with exudative fluid and his adenosine deaminase level was 13U/l (Table 1). Cytological examination of the pleural fluid revealed lymphocyte and mesothelial cells. Generalized tree in a bud pattern at lung parenchyma, mediastinal and bilateral hilar multiple lymph nodes, and pleural effusion on the left hemithorax were seen on thoracic computed tomography (CT) (Figure 2). Video-assisted thoracoscopic surgery (VATS) was performed because the patient could not

tolerate bronchoscopy. The histopathological examination of pleura and mediastinal lymph nodes samples were reported as non-necrotizing granulomatous inflammation, compatible with sarcoidosis (Figure 3). The blood angiotensin-converting-enzyme (ACE) level was 56.63 U/l (N: 8-52), serum calcium level was 10.17 mg/dl (N: 8.6-10), and 24-hour urinary calcium was 235.82 mg/24 h (N: 42-353). Ophthalmological examination was normal. Spirometric evaluation was FEV1: 3.37 L (75%), FVC: 3.85 L (78%), FEV1/FVC: 87%, DLCO: 20.4 ml/mmHg/min (58%), and DLCO/VA: 3.91ml/mmHg/min/l (77%). Methylprednisolone (0.5 mg/kg/day) was initiated. Regression was seen on lymphadenopathies, pleural effusion and parenchymal micronodular opacities at the fifth month of corticosteroid therapy in the thorax CT.

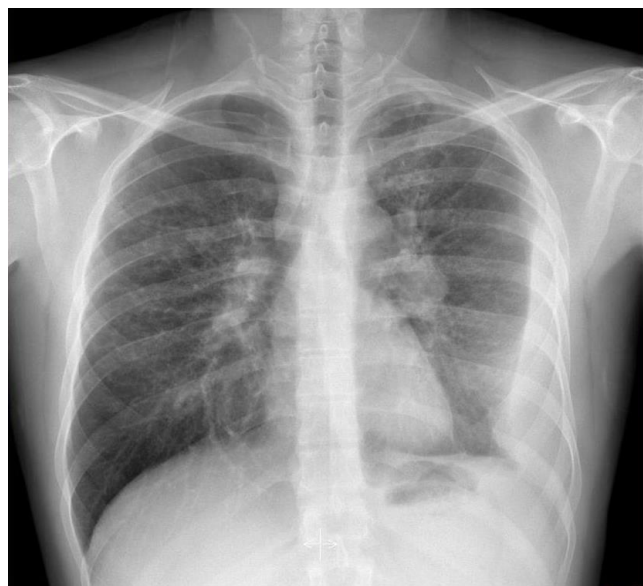


Figure 1: Posterior anterior chest X-ray revealed bilateral hilar enlargement, pleural effusion and parenchymal infiltration at the left upper zone.

DISCUSSION

Sarcoidosis is an idiopathic multisystemic granulomatous disease, which frequently involves the bilateral lymph nodes, pulmonary parenchyma, and eye and skin lesions (1). Pleural involvement is quite rare. Pleural fluid is generally asymptomatic and the effusion prevalence in plain films is about 1-3% (6-7). Pleural thickening and a small amount of fluid in the thorax CT are the more common findings (8). Pleural involvement may be seen pleural thickening, pleural nodules, pneumothorax, chylothorax, and hemothorax (9).

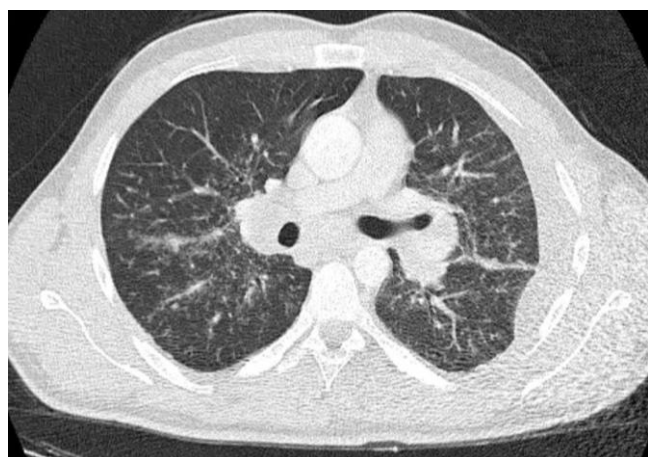


Figure 2: Thoracic CT findings.

Table 1: Biochemical parameters of serum and pleural fluid of case.

	Serum	Pleural fluid
Glucose (mg/dl)	95,9	58,8
Total protein (g/dl)	7,24	4,52
LDH (U/L)	188	102
Albumin (g/dl)	4,75	3
ADA (U/L)	NA	13 (N: 0-15)
ACE (U/L)	56,63	NA
Calcium (mg/dl)	10,17	NA
Eryocyte sedimentation rate (mm/h)	53	NA

LDH: Lactate dehydrogenase, ADA: Adenosin deaminase, ACE: Angiotensin converting enzyme, NA: not applicable

In the process of diagnosing pleural sarcoidosis, other reasons causing pleuritis should be discarded (1). In order to detect pleural fluid, Huggins et al.(5) used thoracic ultrasonography in 5 of 181 of their patient with acidosis, but sarcoidosis involvement with pleural biopsy could only be determined in 2 cases. Sarcoidosis-related pleural fluid may be completely asymptomatic; on the other hand, some patients may suffer from severe dyspnea and/or pleuritic chest pain (9). The current case's complaints were dyspnea and left-sided chest pain. In the literature, parenchymal infiltrations are reported together with a small amount of fluid mostly in the right hemithorax (10). The current case differs from those in the literature in that pleural fluid was found in left hemithorax; parenchymal infiltrations and mediastinal lymph node enlargement were also present. Sarcoidosis-related pleural effusion is slightly more common on the right side and is usually an exudate with lymphocytic predominance (11). Information in the literature is limited regarding the ACE level in sar-

coidosis-related pleural effusion (12). In the current case, as sarcoidosis was not primarily considered clinically and radiologically, the pleural ACE level was not examined; however, the pleural fluid was not only exudative, but also rich with lymphocytes.

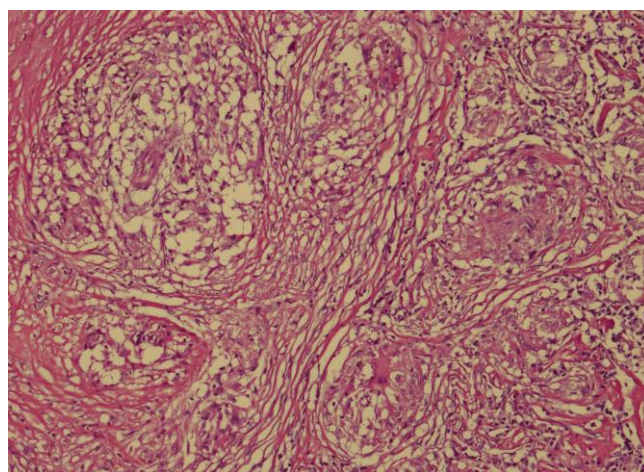


Figure 3: Presence of non-necrotizing granuloma on pleural biopsy (H&E, x100).

Pleural involvement is more frequently seen in Stage 2 and 3 sarcoidosis patients (12), but in the current case, the patient was young and had parenchymal infiltrations. Since tuberculosis and other reasons for pleuritis could not be excluded, the patient underwent VATS for diagnosis. Radiologically, the patient was at Stage 2 of the disease. He was treated with corticosteroid (0.5mg/kg/day) and by the end of five months, his pleural fluid, mediastinal LAP, and parenchymal infiltrations regressed.

The current case is presented to highlight the possibility of sarcoidosis in patients with pleural effusion. However, other pleural pathologies should be excluded and the diagnosis confirmed by biopsy.

CONFLICTS OF INTEREST

None declared.

AUTHOR CONTRIBUTIONS

Concept - H.K.Ö., M.B., N.P.B., A.K., M.E.A., M.S., F.K., F.Y., L.K.; Planning and Design - H.K.Ö., M.B., N.P.B., A.K., M.E.A., M.S., F.K., F.Y., L.K.; Supervision - H.K.Ö., M.B., N.P.B., A.K., M.E.A., M.S., F.K., F.Y., L.K.; Funding - H.K.Ö., M.B.; Materials - H.K.Ö., M.B.; Data Collection and/or Processing - H.K.Ö., A.K., N.P.B.; Analysis and/or Interpretation - H.K.Ö., M.E.A.; Literature Review - H.K.Ö., L.K.; Writing - H.K.Ö., M.S., F.Y.; Critical Review - H.K.Ö., M.B., L.K., M.E.A.

YAZAR KATKILARI

Fikir - H.K.Ö., M.B., N.P.B., A.K., M.E.A., M.S., F.K., F.Y., L.K.; Tasarım ve Dizayn - H.K.Ö., M.B., N.P.B., A.K., M.E.A., M.S., F.K., F.Y., L.K.; Denetleme - H.K.Ö., M.B., N.P.B., A.K., M.E.A., M.S., F.K., F.Y., L.K.; Kaynaklar - H.K.Ö., M.B.; Malzemeler - H.K.Ö., M.B.; Veri Toplama ve/veya İşleme - H.K.Ö., A.K., N.P.B.; Analiz ve/veya Yorum - H.K.Ö., M.E.A.; Literatür Taraması - H.K.Ö., L.K.; Yazıyı Yazan - H.K.Ö., M.S., F.Y.; Eleştirel İnceleme - H.K.Ö., M.B., L.K., M.E.A.

REFERENCES

1. Salerno D. Sarcoidosis pleural effusion: a not so common feature of a well-known pulmonary disease. *Respir Care* 2010; 55:478-80.
2. Mihailovic-Vucinic V, Jovanovic D. Pulmonary sarcoidosis. *Clin Chest Med* 2008; 29:459-73. [\[CrossRef\]](#)
3. Scadding JG, Mitchell DN. Sarcoidosis. 2nd ed. Chapman & Hall, London, 1985.
4. Lynch JP 3rd, Kazerooni EA, Gay SE. Pulmonary sarcoidosis. *Clin Chest Med* 1997; 18:755-85.
5. Huggins JT, Doelken P, Sahn SA, King L, Judson MA. Pleural effusions in a series of 181 outpatients with sarcoidosis. *Chest* 2006; 129:1599-604. [\[CrossRef\]](#)
6. Sharma OP, Gordonson J. Pleural effusion in sarcoidosis: a report of six cases. *Thorax* 1975; 30:95-101. [\[CrossRef\]](#)
7. Bes S, Gür A, Özkan G, Bakan N, Külcü A, Babalik M, et al. Sarcoidosis: a twenty year experience (abstract). *Eur Res J* 2006; (suppl):538s.
8. Çelik G, Kaya A, Numanoğlu N. Pulmoner Sarkoidoz. In: Doğanay A, Kumbasar ÖÖ, (eds). *Güncel bilgiler ışığında sarkoidoz*. 1. baskı. Ankara: Bilimsel Tıp Yayınevi; 1999:41-52.
9. Soskel NT, Sharma OP. Pleural involvement in sarcoidosis. *Curr Opin Pulm Med* 2000; 6:455-68. [\[CrossRef\]](#)
10. Costabel U, Hunninghake GW. ATS/ERS/WASOG statement on sarcoidosis. Sarcoidosis Statement Committee. American Thoracic Society. European Respiratory Society. World association for sarcoidosis and other granulomatous disorders. *Eur Respir J* 1999; 14:735-7. [\[CrossRef\]](#)
11. Nusair S, Kramer MR, Berkman N. Pleural effusion with splenic rupture as manifestations of recurrence of sarcoidosis following prolonged remission. *Respiration* 2003; 70:114-11. [\[CrossRef\]](#)
12. Bedrossian CW, Stein DA, Miller WC, Woo J. Levels of angiotensin-converting enzyme in pleural effusion. *Arch Pathol Lab Med* 1981; 105:345-6.