

Penetrating abdominal wound caused by a close-distance blank cartridge pistol shot: a case report

Yakın mesafeden kurusıkı tabanca atışına bağlı karına nafiz yaralanma:
Olgu sunumu

Zafer TEKE, Ali Özgür ATALAY, Koray TEKİN

Blank cartridge pistols, which are produced for self-defense needs and considered harmless, can be easily purchased by adults due to lack of legal regulations. We present this case because injuries caused by blank cartridge pistol shots may be fatal and are rarely encountered in emergency departments. A 15-year-old boy was brought to the emergency department with a wound on his abdomen caused by a blank cartridge pistol shot. Physical examination revealed an entrance wound, 1 cm in diameter, with a ring-shaped abrasion, 4 cm in diameter, and a surrounding area of contusion, just 2 cm caudal to the left arcus costarum on the anterior axillary line. Muscular defense and rebound tenderness were present in all quadrants of the abdomen. The patient underwent an exploratory laparotomy. At the time of surgery, a proximal jejunal perforation on the antimesenteric side, approximately 1 cm in diameter, and left-sided hematoma of the greater omentum were identified. A wedge resection of the perforated jejunal loop with end-to-end anastomosis and partial left-sided omentectomy were performed. A mass education on the dangers of these guns and the harm they can cause as well as legal regulations for their restricted use seem to be necessary. Physicians should keep in mind that blank cartridge guns can cause fatal injuries.

Key Words: Blank cartridge pistol; intestinal perforation; penetrating abdominal injury.

Kişilerin kendini savunma gerekliliği için üretilen ve zararsız olduğu düşünülen kurusıkı tabancalar ilgili yasal kuralların bulunmaması nedeniyle erişkinler tarafından kolayca satın alınabilmektedir. Kurusıkı tabancaların neden olduğu yaralanmalar ölümcül olduğu ve nadiren acil servise geldiği için bu olguyu sunuyoruz. Kurusıkı tabanca atışı ile karından yaralanan 15 yaşındaki bir erkek çocuğu acil servise getirildi. Fiziksel incelemede, sol kot kavsinin hemen 2 cm altında ön koltuk altı çizgisi üzerinde 1 cm çapında giriş yarası ve bu yaranın çevresinde 4 cm çapında halka şeklinde abrazyon ve kontüzyon alanı olduğu görüldü. Karnın tüm kadrantlarında defans muskuler ve ribaund hassasiyeti vardı. Hastaya eksploratif laparotomi yapıldı. Ameliyatta, proksimal jejunumda antimesenterik kenarda yaklaşık 1 cm çapında perforasyon ve sol tarafta büyük omentumda hematoma saptandı. Perfore jejunum ansına kama rezeksiyon ve uç uca anastomoz ve parsiyel sol omentektomi yapıldı. Bu tip silahların tehlike ve zararlarına ilişkin kitle eğitimi ve kullanımının kısıtlanmasına ilişkin yasal kuralların gerekli olduğu görünmektedir. Doktorların kurusıkı tabancaların ölümcül yaralanmalara neden olabildiğini unutmamaları gerekir.

Anahtar Sözcükler: Kurusıkı tabanca; bağırsak perforasyonu; karına nafiz yaralanma.

Blank cartridge handguns are generally underestimated in their capacity to inflict serious and potentially life-threatening injuries.

The predominant reasons for these injuries are suicide or suicide attempts, followed by accidental injuries. Penetrating blank cartridge pistol injuries to

the abdomen are the rare occurrences, with only a few cases reported in the world literature.

We herein report the case of a 15-year-old patient who sustained penetrating injury to the abdomen caused by a close-distance blank cartridge pistol shot that required surgical intervention.

CASE REPORT

A 15-year-old boy was brought to the emergency department of our hospital after being hit by a close-distance blank cartridge pistol shot. A friend of the victim had fired a shot to the abdomen during an argument. On arrival, he was hemodynamically stable, with a blood pressure of 110/60 mmHg and a heart rate of 109 beats/min. On physical examination, he presented an entrance wound, 1 cm in diameter, with a ring-shaped abrasion, 4 cm in diameter, and a surrounding area of contusion, without powder staining or burning, just 2 cm caudal to the left arcus costarum on the anterior axillary line (Fig. 1a). No exit wound was identified. Muscular defense and rebound tenderness in all quadrants of the abdomen were present. The results of routine blood examinations (cell count, blood chemistry) were in the reference range. The plain X-ray films of the thorax and abdomen showed no pathological signs. With a provisional diagnosis of gastrointestinal perforation, an explorative laparotomy was performed. At the time of surgery, a jejunal perforation on the antimesenteric side, about 1 cm in diameter and approximately 25 cm distal to the ligament of Treitz, and a left-sided hematoma of the greater omentum were identified (Fig. 1b). A small piece of plastic material, greenish in color, was also seen in the bowel lumen. A wedge resection of the injured jejunal loop with end-to-end anastomosis and a partial left-sided omentectomy were performed. No other injuries to the abdomen were found. The patient was discharged home in good condition on the fifth day after surgery and was doing well when seen during follow-up two weeks postoperatively.

DISCUSSION

We herein report the case of a 15-year-old patient who sustained penetrating injury to the abdomen caused by a close-distance blank cartridge pistol shot that required surgical intervention. Blank cartridge pistols are often bought for self-defense, but can also be used for criminal activities. This case impressively demonstrates the error of the belief that blank cartridge pistols are harmless.

Blank cartridges typically contain black powder or nitrocellulose as an explosive and a small amount of ignition material inside a metal cartridge. The explosive may be contained in a plastic capsule and a separating layer of paper or cork.^[1] Contact or very close-range shots will produce an entry wound of the skin surrounded by a punch mark of the muzzle. The punch mark is a result of the expanding gas volume inside the wound sealing the skin against the muzzle and the face of the weapon.^[2-4] The skin may rupture in a star-like pattern because of the pressure buildup. This wound morphology may also occur in gunshot injuries with live ammunition, but is more pronounced with gas weapons, because the expanding gas volume cannot follow the path of a penetrating projectile.^[5] Typically, the wound is filled with burned tissue debris and burned material from the load such as powder, paper or cork from separating materials inside the cartridge.^[6,7] The explosion temperature of nitrocellulose in a constant volume is 2,500 to 3,000°C, which results in a temperature of approximately 1,500°C at the muzzle lasting for 0.1 to 0.5 millisecond. The high temperatures of burning gas will cause formation of CO hemoglobin evident by the bright red muscle tissue.^[8] In contrast to con-

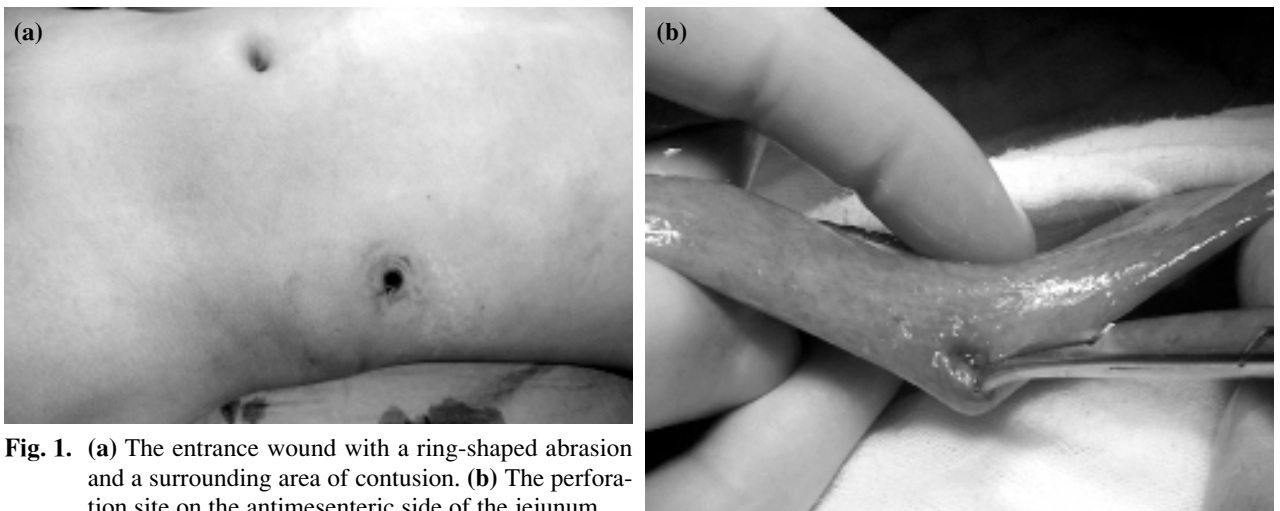


Fig. 1. (a) The entrance wound with a ring-shaped abrasion and a surrounding area of contusion. (b) The perforation site on the antimesenteric side of the jejunum.

tact shots, in close-range gunshots, the entry marks of skin burst and wound laceration are less profound; however, the ballistic of the gas jet takes on characteristics of a true projectile, resulting in elongated channel-like lesions with deeper penetration.^[5] In addition, these wounds are characterized by particles of burned powder surrounding the entry site in a variable diameter. This patient presented an entrance wound, 1 cm in diameter, with a ring-shaped abrasion, 4 cm in diameter, and a surrounding area of contusion, without powder staining or burning, just 2 cm caudal to the left arcus costarum on the anterior axillary line.

These injuries can be life-threatening, particularly when the underlying structures are soft vital organs. Abdominal injuries caused by blank cartridge pistols have been occasionally described.^[9,10] Due to the anatomical conditions, the pathways supplying vital structures are situated close together, especially in the abdomen. Fatalities caused by blank cartridges are usually the result of massive blood loss due to ruptured large blood vessels.^[11-13] In the presented case, a close-distance shot to the abdomen from a blank cartridge pistol caused an intestinal perforation and a left-sided hematoma of the greater omentum.

Blank cartridge pistols are often imitations of real handguns, which in design and function are very similar to the original weapons. Both in Turkey and in certain European countries, the purchase of “non-lethal” weapons is authorized for sale to anyone over 18 years of age. Therefore, any adult over 18 can easily purchase a handgun and ammunition, including blank cartridge pistols, tear-gas cartridges, pyrotechnics, and signalling material. In our country, the nature and extent of the use of blank cartridge pistols as well as patterns of injuries caused by blank cartridge pistol shots are not completely known. Owing to the lack of regulations on blank cartridge pistols in the current gun legislation, these handguns have recently gained in popularity among football fanatics, high school students, and youngsters, who mimic legendary film characters and even undefeated heroes of television series, as a new phenomenon in Turkey.

Although several authors have stressed the dangers of these types of weapons and their potentially lethal effects when used at close or contact range, the potential of these weapons to inflict serious and potentially lethal injuries is still grossly underestimated. It seems essential to inform the community,

especially youngsters and students as well as gun salesmen and the other possible users of these types of weapons, about their dangers. At the present time, there are immediate requirements for dissuasive laws regulating stipulations of importing, selling, purchasing, and freely carrying blank cartridge pistols. Also, the “clean screen” policy on TV should be revived for the healthy psychological development of our children.

This report corroborates the warning statements made by many criminological and medico-legal experts regarding the inherent dangers of these allegedly harmless weapons. Therefore, we call for a much stricter control of weapons of this kind. We conclude that, from a surgical point of view, this weapon is potentially harmful. Furthermore, the risks of blank cartridge pistol guns should be taken into account for the development of sublethal weapons.

REFERENCES

1. Bock G, Weigel W, Seitz G, Habersbrunner H. Handbuch der Faustfeuerwaffen. 8th eds. Melsungen: Neumann-Neudamm; 1980. 114-5, 512-5.
2. Clark MA, Micik W. Confusing wounds of entrance and exit with an unusual weapon. *Am J Forensic Med Pathol* 1984;5:75-8.
3. Pollak S. Zur Makro- und Mikromorphologie der durch Faustfeuerwaffen erzeugten Einschusswunden. *Beitr Gerichtl Med* 1982;40:493-520.
4. Pollak S, Stellwag-Carion C. Morphologische Besonderheiten bei absoluten Nahschüssen auf bekleidete oder bedeckte Körperregionen. *Beitr Gerichtl Med* 1988;46:401-7.
5. Rothschild MA. Freiverkäufliche Schreckschußwaffen: medizinische, rechtliche und kriminaltechnische Bewertung. Berg S, Brinkmann B eds. Lübeck: Schmidt-Römhild; 1999. 216.
6. Rothschild MA, Vendura K. Fatal neck injuries caused by blank cartridges. *Forensic Sci Int* 1999;101:151-9.
7. Stahl CJ, Young BC, Brown RJ, Ainsworth CA 3rd. Forensic aspects of tear-gas pen guns. *J Forensic Sci* 1968;13:442-69.
8. Rothschild MA, Karger B, Strauch H, Joachim H. Fatal wounds to the thorax caused by gunshots from blank cartridges. *Int J Legal Med* 1998;111:78-81.
9. Tsyganov KM, Vedeniopin AS, Budanov IuP. Penetrating abdominal cavity wound in a shooting by a blank cartridge from a homemade weapon. *Sud Med Ekspert* 1983;26:53-4.
10. Berlatzky Y, Katz S, Ayalon A, Abu-Dallo K. Abdominal injuries due to blank cartridges. *Injury* 1977;9:77-8.
11. Enders H. Verteidigungs-oder Mordwaffe? *Kriminalist* 1986;4:191-3.
12. Jacob B, Huckenbeck W, Daldrup T, Haarhoff K, Bonte W. Suicides by starter's pistols and air guns. *Am J Forensic Med Pathol* 1990;11:285-90.
13. Maxeiner H, Schneider V. Verletzungen und Todesfälle durch Gas-/Schreckschußwaffen. *Arch Kriminol* 1989;184:84-92.