

Traumatic abdominal hernia complicated by necrotizing fasciitis

Aleix Martínez-Pérez, M.D., Gonzalo Garrigós-Ortega, M.D., Segundo Ángel Gómez-Abril, M.D.,
Eva Martí-Martínez, M.D., Teresa Torres-Sánchez, M.D.

Department of General and Digestive Surgery, Hospital Universitario Doctor Peset, Valencia, Spain

ABSTRACT

Necrotizing fasciitis is a critical illness involving skin and soft tissues, which may develop after blunt abdominal trauma causing abdominal wall hernia and representing a great challenge for physicians. A 52-year-old man was brought to the emergency department after a road accident, presenting blunt abdominal trauma with a large non-reducible mass in the lower-right abdomen. A first, CT showed abdominal hernia without signs of complication. Three hours after ICU admission, he developed hemodynamic instability. Therefore, a new CT scan was requested, showing signs of hernia complication. He was moved to the operating room where a complete transversal section of an ileal loop was identified. Five hours after surgery, he presented a new episode of hemodynamic instability with signs of skin and soft tissue infection. Due to the high clinical suspicion of necrotizing fasciitis development, wide debridement was performed. Following traumatic abdominal wall hernia (TAWH), patients can present unsuspected injuries in abdominal organs. Helical CT can be falsely negative in the early moments, leading to misdiagnosis. Necrotizing fasciitis is a potentially fatal infection and, consequently, resuscitation measures, wide-spectrum antibiotics, and early surgical debridement are required. This type of fasciitis can develop after blunt abdominal trauma following wall hernia without skin disruption.

Key words: Abdominal trauma; necrotizing fasciitis; surgery; wall hernia.

INTRODUCTION

Traumatic abdominal wall hernia (TAWH), with a low occurrence rate, is usually caused by high-energy traumas where patients can also present unsuspected injuries in the abdominal organs.

While bowel injuries are less frequent (6%),^[1] the organs most frequently affected in blunt abdominal trauma are the spleen (30%), liver (25%), and kidney (20%).

In isolated bowel injury, sepsis originated from perforated intestinal loop is the principal severe postoperative complication and the main cause of death. Delay in presentation, di-

agnosis and treatment result in poor outcomes.^[2] Helical CT can be normal in the early moments, leading to misdiagnosis. Necrotizing fasciitis is a critical illness produced by a blunt abdominal trauma causing abdominal wall hernia.

CASE REPORT

A 52-year-old man was brought to the emergency department after a road accident (impact after crashing his motor-bike into a car), presenting blunt abdominal trauma (handlebar injury) without CET or loss of consciousness.

A preliminary examination was performed, where the patient remained stable with distended abdomen and presented a new apparition, a large non-reducible mass in the lower-right abdominal region, with eroded skin and surrounding hematoma. Early blood tests showed hemoglobin 13.2 mg/l and 21500 leukocytes with neutrophylia. A chest-abdominal CT was performed, indicating haemoperitoneum in the right hemi-abdomen and a TAWH, without signs of complication. Retroperitoneal and mesenterium hematoma compressing the vena cava were also evidenced.

The patient was admitted in the ICU, with empiric antibiotherapy; three hours later he suddenly developed hemodynamic instability. After resuscitation, a new CT scan was requested

Address for correspondence: Aleix Martínez-Pérez, M.D.
Servicio de Cirugía General y del Aparato Digestivo,
Avenida Gaspar Aguilar 90 46017 Valencia, Spain
Tel: +34 961622505 E-mail: aleix.martinez.perez@gmail.com

Quick Response Code



Ulus Travma Acil Cerrahi Derg
2014;20(6):455-458
doi: 10.5505/tjtes.2014.83031

Copyright 2014
TJTES

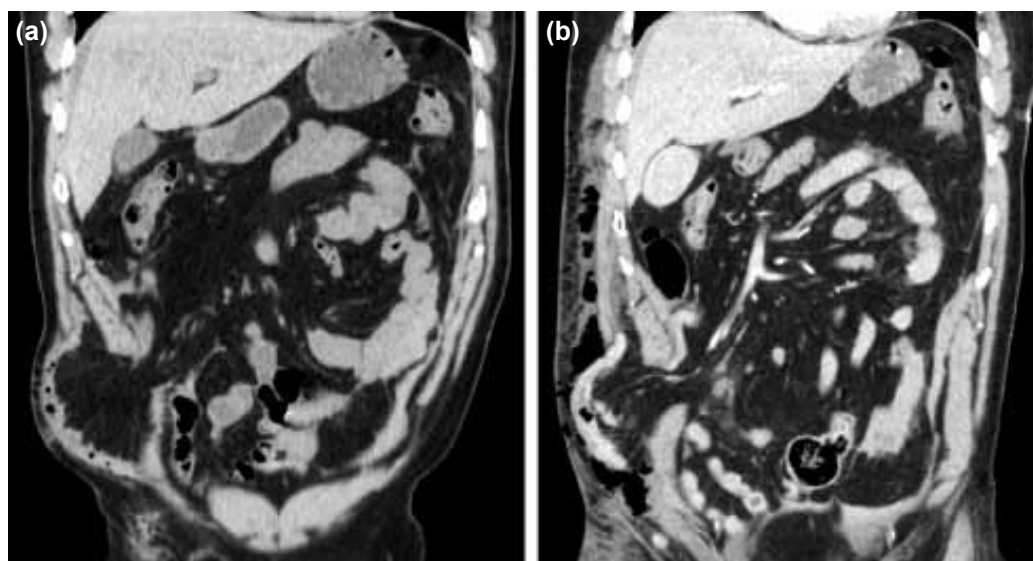


Figure 1. (a) Coronal CT scan upon admittance, showing haemoperitoneum in left abdomen and uncomplicated TAWH with small bowel loop. (b) Coronal CT three hours after ICU admission with important subcutaneous and intramuscular emphysema in the right flank and bowel wall thickening in the hernia, suggesting a bowel perforation.

showing significant changes in the hernia including subcutaneous and intramuscular emphysema, and significant bowel wall thickening (Fig. 1). Due to the suspicion of hollow viscus perforation, the patient was transferred to the operating room.

After skin incision, an important subcutaneous collection with intestinal content was appreciated; however, infectious signs in soft tissues were not evidenced. Fascia and muscle were exposed, and perforation of the peritoneum, due to trauma, was observed. A complete transversal section of an ileal loop was also identified. Lavage of abdominal cavity and a manual terminal ileal anastomosis by suturing the mesenteric defect were performed, and the skin remained open.

Five hours after the procedure, the patient suddenly

developed a new episode of hemodynamic instability and physical examination revealed induration of surgical wound with dark fluid flowing from it. Crepitation in adjacent skin was appreciated and was also noted in the thorax and right thigh. Due to the clinical suspicion of necrotizing fasciitis, the patient was immediately transferred to the operating room, where wide debridement was performed by excising necrotized tissues and through lavage using H₂O (Fig. 2).

The patient was re-admitted in the ICU, where his critical management continued with wide-spectrum antibiotics (meropenem, linezolid and fluconazole). A microbiological test of wound liquid indicated growth of *E. coli*, *Enterococcus faecalis*, and *Streptococcus mitis* (Fig. 3). He had a slow recovery consisting continued washing of the wound and decreased

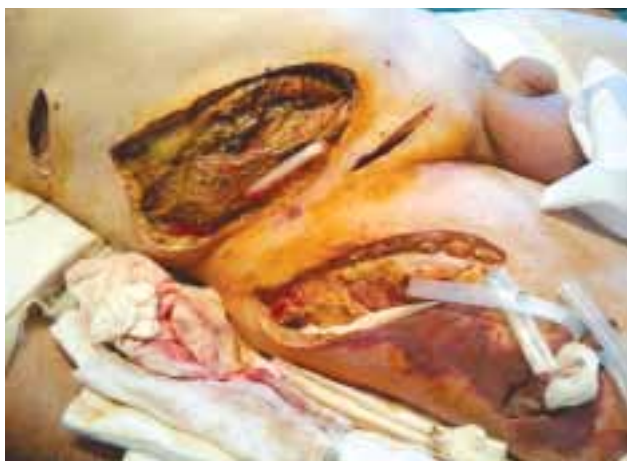

Figure 2. Day 5: Necrotizing fasciitis affecting the lower anterior abdominal wall and right thigh after wide surgical debridement. Penrose drainages were placed in order to prevent retention of secretions and facilitate subsequent washing.

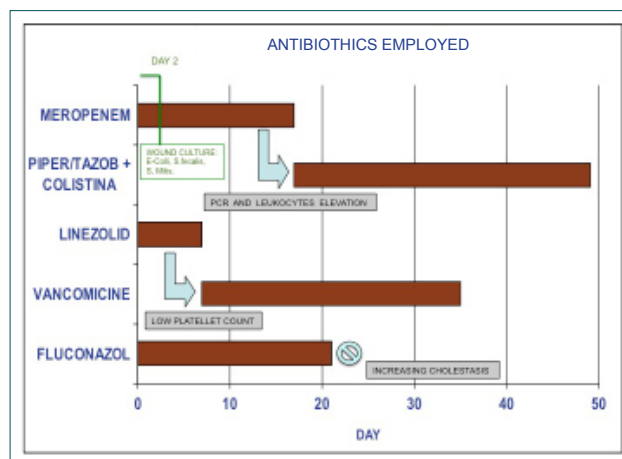


Figure 3. Antibiotics employed: Day 18: Meropenem was changed with the combination of Piperaziline-Tazobactam + Colistine due to cholestasis. Day 8: Linezolid was changed to Vancomycin for thrombocytopenia.

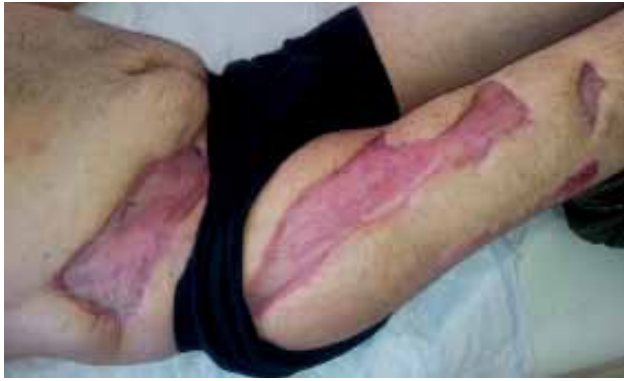

Figure 4. Three months after surgery, showing wound healing.

dosages of drugs. Ventilatory support was discontinued 25 days after the trauma. Three days later, oral intake was initiated and well-tolerated. On the 52nd day, the patient was discharged and remitted to the plastic surgery unit, where his wound continues to be treated to date (Fig. 4).

DISCUSSION

Since the first case of TAWH reported in 1906 by Selby, there have not been many cases published or clinical guidelines validated for its management. This kind of injury is usually produced by high-energy blunt trauma; however, in our case a low-energy impact (handlebar injury) was the origin. Increase in abdominal pressure associated with a combined tangential force was hypothesized to be the cause of muscle and fascial disruption.^[2]

Principal CT bowel perforation signs include bowel wall thickening, bowel wall discontinuity, and presence of extra-luminal air.^[3] There are studies on CT effectiveness in hollow viscus perforation in blunt abdominal trauma with 26.3% false negatives in the first CT, which decreases when repeated after 24-72h.^[4] As observed, in case of high clinical suspicion of bowel perforation with negative CT, a new CT scan is required.

The infection was considered to have developed before the surgery, due to the presence of subcutaneous and intramuscular emphysema in the preoperative CT scan and the presence of intestinal microflora with absence of skin germs in the culture. It is possible that an earlier radical surgery would have improved the patient's outcome, but the first intervention revealed no signs of infection, and thus, did not result in a more aggressive management. However, early intervention in TAWH without delayed diagnosis and intervention leads to a significantly better outcome.^[5]

Necrotizing fasciitis (NF), not causing mionecrosis, is a potentially fatal infection involving skin, subcutaneous tissue and muscle. *Streptococcus* group A and *Staphylococcus aureus* (alone or in synergism) are usually considered the initial infecting bacteria shortly after the start of the onset of the disease contamination with their own aerobic and anaerobic microflora.

Regarding microbiological findings, the patient presented NF type I, the most frequent type (70-80%), caused by polymicrobial symbiosis and synergism.^[6]

Generally agreed NF therapeutic algorithm include patient's resuscitation, broad spectrum antibiotics, which must later be adjusted to adequately cover organisms obtained in the initial culture, and early debridement of all dead tissue, which should be repeated every 24-48 hours, obtaining gram stain and culture from the wound. Other measures such as hyperbaric oxygen therapy can be considered in the hemodynamically stable patient, if available.

Antibiotherapy alone is not an option since, among other things, tissue hypoxia and ischemia do not permit an adequate delivery of antibiotics to the tissue. The combination of antibiotics should cover a broad spectrum of anaerobes and aerobes, gram-positive and gram-negative. A combination covering all was used in this patient including meropenem-linezolid-fluconazole; however, others such as penicillin, g-clindamycin-gentamicin have also been used with positive results. Due to the increasing number of MRSA infections, daptomycin or linezolid should be used until the infection is excluded (vancomycin is in use, but it has no effect on exotoxin damage).^[7]

It is important to remember that in the case of a high suspicion of bowel perforation in a TAWH with negative CT, it should be repeated. Furthermore, if the second CT scan is also negative and there is still high clinical suspicion of bowel perforation, surgical exploration is mandatory.

There are cases reported in the literature linking NF after abdominal surgery procedures, such as inguinal hernia repair^[8] or strangulated umbilical^[9] and inguinal^[10] hernia. However, we did not find previous reports of NF caused by traumatic abdominal wall hernia.

Conflict of interest: None declared.

REFERENCES

1. Meneu JC, Manrique A, Moreno A. Evaluación de los traumatismos contusos del abdomen. Capítulo 5-4, Madrid; Jarpoy Ed; 2005. p. 359-70.
2. Guly HR, Stewart IP. Traumatic hernia. *J Trauma* 1983;23:250-2. [CrossRef](#)
3. Breen DJ, Janzen DL, Zwirewich CV, Nagy AG. Blunt bowel and mesenteric injury: diagnostic performance of CT signs. *J Comput Assist Tomogr* 1997;21:706-12. [CrossRef](#)
4. Nicolau AE, Merlan V, Dinescu G, Crăciun M, Kitkani A, Beuran M. Perforation of hollow organs in the abdominal contusion: diagnostic features and prognostic factors of death. [Article in Romanian] *Chirurgia (Bucur)* 2012;107:162-8. [Abstract]
5. Gupta S, Dalal U, Sharma R, Dalal A, Attri AK. Traumatic abdominal wall hernia. *Ulus Travma Acil Cerrahi Derg* 2011;17:493-6. [CrossRef](#)
6. Morgan MS. Diagnosis and management of necrotising fasciitis: a multi-parametric approach. *J Hosp Infect* 2010;75:249-57. [CrossRef](#)
7. Roje Z, Roje Z, Matic D, Librenjak D, Dokuzović S, Varvodić J. Necrotizing fasciitis: literature review of contemporary strategies for diagnosing

- and management with three case reports: torso, abdominal wall, upper and lower limbs. *World J Emerg Surg* 2011;6:46. [CrossRef](#)
8. Georgiev-Hristov T, Álvarez-Gallego M, Juliá JB, Redondo MG, Verón A, Castell-Gómez JT. Necrotising fasciitis of the lower limb due to perforated inguinal hernia. *Hernia* 2011;15:571-3. [CrossRef](#)
 9. Coyle P, Jaber S, Smith J, Grace PA. Damage control apronectomy for necrotising fasciitis and strangulated umbilical hernia. *Ir J Med Sci* 2010;179:607-8. [CrossRef](#)
 10. Sistla SC, Sankar G, Sistla S. Fatal necrotizing fasciitis following elective inguinal hernia repair. *Hernia* 2011;15:75-7. [CrossRef](#)

OLGU SUNUMU - ÖZET

Nekrotizan fasiit ile komplike travmatik abdominal herni

Dr. Aleix Martínez-Pérez, Dr. Gonzalo Garrigós-Ortega, Dr. Segundo Ángel Gómez-Abril, Dr. Eva Martí-Martínez, Dr. Teresa Torres-Sánchez

Genel ve Sindirim Cerrahisi Servisi, Doktor Peset Üniversite Hastanesi, Valensiya, İspanya

Nekrotizan fasiit deri ve yumuşak dokuları etkileyen, künt karın travmasından sonra gelişebilen, karın duvarı hernisine neden olan ve doktorlar için büyük bir sorun oluşturan kritik önemde bir hastalıktır. Elli iki yaşındaki erkek bir trafik kazası ardından acil servise künt karın travmasına bağlı sağ alt karın bölgesinde redükte edilemeyen büyük bir kitle ile getirildi. İlk BT herhangi bir komplikasyon bulgusu olmayan bir abdominal herniyi göstermişti. Yoğun bakım ünitesine kabulden üç saat sonra, hastada hemodinamik instabilite geliştiğinden yeniden bir BT taraması istendi. Ameliyathaneye getirildi ve ameliyatta ileal bağırsak segmentinin tümüyle enine yarılmış olduğu saptandı. Cerrahiden beş saat sonra deri ve yumuşak doku enfeksiyonu belirtileriyle birlikte yeni bir hemodinamik instabilite atağı geçirdi. Yüksek bir klinik nekrotizan fasiit gelişme kuşkusu nedeniyle geniş bir debridman yapıldı. Karın duvarı hernisi ardından hastalar karın organlarında kuşku lanılmaayan yaralanmalarla gelebilir. İlk dakikalarda çekilen spiral BT yalnızca negatif sonuçlara ve neticede yanlış tanıya yol açabilir. Nekrotizan fasiit ölümcül olabilen bir enfeksiyon olduğundan sonuçta resüsitasyon önlemleri, geniş spektrumlu antibiyotikler ve erken dönemde cerrahi debridman gerekir. Bu tip fasiit künt karın travmasına bağlı deri bütünlüğünün bozulmadığı karın duvarı hernisi sonrası bu tip fasiit gelişebilir.

Anahtar sözcükler: Abdominal travma; cerrahi; duvar hernisi; nekrotizan fasiit.

Ulus Travma Acil Cerrahi Derg 2014;20(6):455-458 doi: 10.5505/tjtes.2014. 83031