



## Post-traumatic sagittal sinus thrombosis: case report

### Posttravmatik sagittal sinüs trombozu: Olgu sunumu

Nayil KHURSHEED, Ramzan ALTAF, Nizami FURQAN, Abrar WANI, Ashish JAIN, Yawar ALI

Post-traumatic superior sagittal sinus thrombosis is rare. The usual presentation is raised intracranial pressure symptoms. We report a case of post-traumatic superior sagittal sinus thrombosis in which the computed tomography (CT) scan revealed depressed fracture of the vertex with parasagittal contusions. Despite surgical elevation of the fracture and repair of the superior sagittal sinus, the patient developed thrombosis of the anterior half of the superior sagittal sinus with bilateral hemorrhagic infarcts in the motor strip. This case is reported for its rarity and to highlight the importance of careful postoperative observation of such patients. In such settings, timely diagnosis and anticoagulant therapy are rewarding.

**Key Words:** Head injury; sagittal sinus thrombosis; magnetic resonance venogram.

Posttravmatik süperior sagittal sinüs trombozu nadiren görülmektedir. Olağan belirtileri kafa içi basınç semptomlarının ortaya çıkmasıdır. Bu yazıda, bilgisayarlı tomografi taramasının parasagittal kontüzyonlarla birlikte vertekste çökme kırığını gösterdiği bir posttravmatik superior sagittal tromboz olgusu sunuldu. Çökme kırığının cerrahi yolla elevasyonu ve superior sagittal sinüsün onarımına rağmen hastada motor segmentte çift taraflı hemorajik infarktlarla birlikte superior sagittal sinüsün ön yarısında tromboz gelişti. Bu olgu seyrek görülmesi ve bu hastalarda dikkatli ameliyat sonrası gözlemin önemini vurgulamak için sunuldu. Bu ortamlarda zamanında tanı ve antikoagülan tedavi yürüldürücüdür.

**Anahtar Sözcükler:** Kafa travması; sagittal sinüs trombozu; manyetik rezonans venogram.

Post-traumatic superior sagittal sinus thrombosis is rare. A depressed skull fracture overlying a major venous sinus in the brain may result in sinus injury and consequent venous thrombosis.<sup>[1]</sup> Various mechanisms have been postulated.<sup>[2]</sup> The diagnosis can be overlooked, especially in the setting of concomitant parasagittal contusions, which can lead to a delay in the diagnosis.

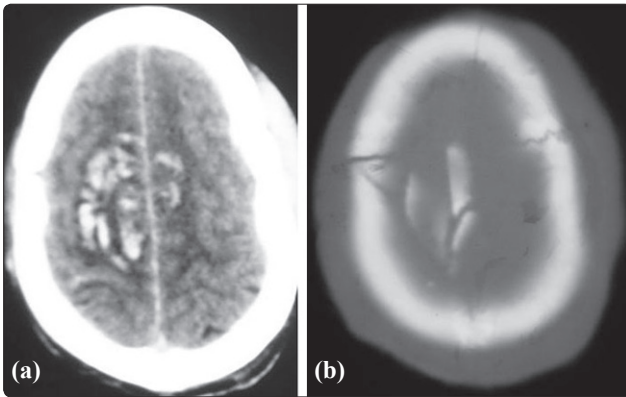
We report a case of vertex fracture with parasagittal contusions superimposed by superior sagittal sinus thrombosis.

### CASE REPORT

A 20-year-old male reported to our hospital within 2 hours of head injury with a history of weakness of both lower limbs. On examination, there was a lacerated wound at the vertex with underlying depressed fracture. His Glasgow Coma Scale (GCS) score at admission was 13/15. The power in the upper limbs was

normal and in the lower limbs was 2/5.

Plain computed tomography (CT) of the head showed a comminuted depressed fracture of the vertex with bilateral mid-parasagittal hyperdensities, which were thought to be hemorrhagic contusions (Fig. 1a, b). Intraoperatively, a 7 cm x 5 cm comminuted depressed fragment of bone at the vertex and a partial tear in the sagittal sinus were seen. The depressed fragments were elevated and the tear was sealed with gelatin foam. The patient was maintained on decongestants, anticonvulsants and antibiotics. The GCS was 13/15, and he continued to have paraparesis, but on the 5th postoperative day, his GCS score dropped to 10/15. Plain CT scan of the head showed an increase in the size of the mid-parasagittal hemorrhagic lesions with perilesional edema (Fig. 2a). We reviewed our diagnosis, and the possibility of superior sagittal sinus thrombosis was considered. Brain magnetic resonance imaging (MRI) revealed non-visualization of the an-



**Fig. 1.** (a) Plain CT scan showing bilateral parasagittal posterior frontal hemorrhagic contusions and (b) comminuted depressed fracture of the vertex.

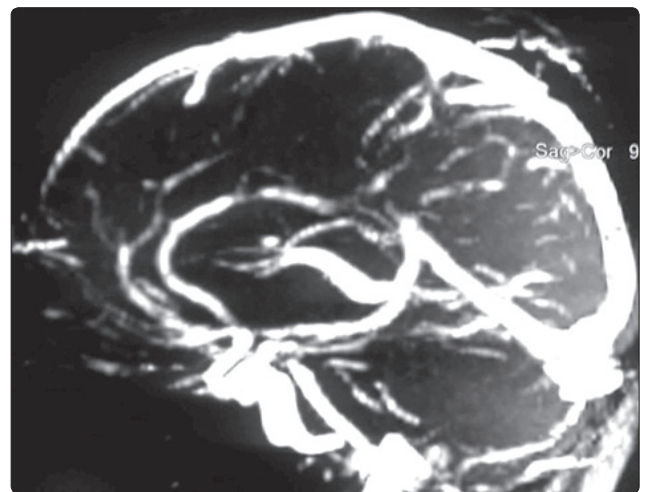
terior half of the superior sagittal sinus with features of hemorrhagic infarcts in bilateral medial motor areas (Fig. 2b, c). Systemic anticoagulation was started with heparin on the 5th postoperative day. Complete blood counts revealed mild leukocytosis. The erythrocyte sedimentation rate (ESR) was raised (15 mm 1st hour). Blood cultures were negative. The patient was monitored with serial coagulograms. By the 3rd postoperative week, the GCS of the patient had improved to 15/15, with no improvement in power. He was discharged on anticoagulants and anti-epileptics. At the 8th-month follow-up, power in the lower limbs had improved to 3-4/5. The brain MRI showed recanalization of the superior sagittal sinus (Fig. 3).

### DISCUSSION

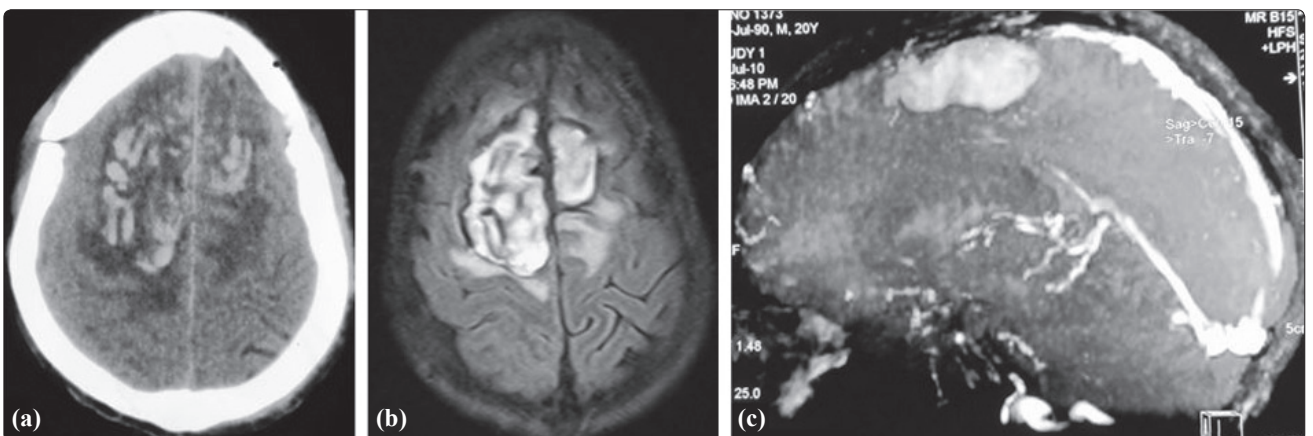
The first case of traumatic sagittal sinus thrombosis was reported by Ecker.<sup>[3]</sup> The incidence of post-traumatic sinus thrombosis is 4% in penetrating head injury.<sup>[4]</sup> The pathogenesis is: (a) abnormal clotting mechanism, (b) disturbance of blood flow, and (c) endothelial injury.<sup>[2]</sup> The most common symptoms are altered sensorium, headache and seizures.<sup>[5]</sup> Plain X-

ray lateral view of the skull may reveal a double density of the fractured region.<sup>[6]</sup> Non-contrast CT scan may reveal hyperdensity of the sinus.<sup>[7]</sup> This was not seen in our patient as the CT scan was done within 2 hours of injury, which is too early, and the sagittal sinus thrombosis might have supervened later. MR venogram is the gold standard for diagnosis. It shows non-visualization of the sinus.<sup>[8]</sup> Multi-detector CT venography is another useful modality in the detection of sinus thrombus.<sup>[9]</sup> Sinus thrombosis may cause increased levels of fibrinogen degradation products in the serum.<sup>[10]</sup>

Untreated depressed fractures of the vertex have been mentioned for their delayed presentation of severe raised intracranial pressure features.<sup>[11]</sup> Interestingly, even a delayed effort of surgical debridement and subsequent release of the compression on the sagittal sinus has been rewarding. However, this entire scenario has been reported thus far in fractures of the vertex causing direct mechanical obstruction of the sinus without inducing sagittal sinus thrombosis.<sup>[1,12-14]</sup>



**Fig. 3.** MRV on follow-up showing restoration of the patency of the sinus.



**Fig. 2.** (a) Repeat CT scan and (b) MRI show increase in the size of the hemorrhagic contusions, with (c) MR venogram showing obliteration of the anterior half of the sagittal sinus.

Once thrombosis has occurred, the recovery may not be dramatically fast.<sup>[15,16]</sup> Our case deviated slightly from the historical examples. Our patient was hit on the vertex by a stone, and the CT scan done within 2 hours of injury revealed bilateral mid-parasagittal contusions in addition to vertex fracture. Most such fractures, which have been managed conservatively in the past for fear of exsanguination during surgery, ultimately had to be treated surgically to alleviate the symptoms of raised intracranial pressure;<sup>[12,13,17]</sup> thus, we decided to surgically address the fracture without resorting to the conservative management. Surgery was done within 4 hours of injury. The wound was relatively clean and all the bone fragments were removed. However, even then, the patient developed sinus thrombosis possibly because of the endothelial injury to the sinus walls. Various methods to deal with the tear in the sagittal sinus have been mentioned, namely: temporalis muscle and fascia graft, direct repair, saphenous vein graft, and silicone tube interposition.<sup>[18-20]</sup> In view of the small tear in the sinus of our patient, we could manage it successfully using a gelatin sponge as a sealant. Post-infectious superior sagittal sinus thrombosis can also occur; however, in our case, the wound was relatively clean. Different modalities of treatment have been outlined for the treatment of sinus thrombosis, namely: stents, catheter delivery of thrombolytic agents, and systemic heparin. Urokinase has been infused into the sinus via a jugular catheter combined with mechanical thrombus disruption or removal with a balloon catheter in patients with superior sagittal sinus thrombosis.<sup>[21,22]</sup> Stent angioplasty for the thrombotic stenosed sagittal sinus has also been tried.<sup>[23]</sup> In our case, we started heparin on the 5th postoperative day when the patient deteriorated, and the imaging performed revealed sagittal sinus thrombosis. In the past, the role of heparin in post-traumatic sagittal sinus thrombosis was thought to be hazardous, in view of concomitant hemorrhagic lesions, which may worsen after heparin therapy; however, recent literature supports its use as it inhibits the extension of the thrombosis into adjoining sinuses and cortical veins,<sup>[8,24]</sup> and a MR venogram, especially in the late phase, usually shows restoration of the patency of the sinus in the follow-up.

In conclusion, even after prompt surgical elevation of depressed fractures of the vertex, possibility of a delayed superior sagittal sinus thrombosis should always be considered.

*Conflict-of-interest issues regarding the authorship or article: None declared.*

## REFERENCES

1. du Plessis JJ. Depressed skull fracture involving the superior sagittal sinus as a cause of persistent raised intracranial pressure: a case report. *J Trauma* 1993;34:290-2.
2. Carrie AW, Jaffe FA. Thrombosis of superior sagittal sinus caused by trauma without penetrating injury. *J Neurosurg* 1954;11:173-82.
3. Becker G, Bogdahn U, Gehlberg C, Fröhlich T, Hofmann E, Schliep MD. Transcranial color-coded real-time sonography of intracranial veins. Normal values of blood flow velocities and findings in superior sagittal sinus thrombosis. *J Neuroimaging* 1995;5:87-94.
4. Ochagavia AR, Boque MC, Torre C, Alonso S, Sirvent JJ. Dural venous sinus thrombosis due to cranial trauma. *Lancet* 1996;347:1564.
5. Hesselbrock R, Sawaya R, Tomsick T, Wadhwa S. Superior sagittal sinus thrombosis after closed head injury. *Neurosurgery* 1985;16:825-8.
6. Reilly HP Jr, Erbeni A, Sachs E Jr, Dyke JR. Penetration of the sagittal sinus by a depressed skull fracture. Roentgenographic diagnosis in an asymptomatic boy. *JAMA* 1967;202:841-2.
7. Rao KC, Knipp HC, Wagner EJ. Computed tomographic findings in cerebral sinus and venous thrombosis. *Radiology* 1981;140:391-8.
8. Bousser MG, Chiras J, Bories J, Castaigne P. Cerebral venous thrombosis-a review of 38 cases. *Stroke* 1985;16:199-213.
9. Delgado Almandoz JE, Kelly HR, Schaefer PW, Lev MH, Gonzalez RG, Romero JM. Prevalence of traumatic dural venous sinus thrombosis in high-risk acute blunt head trauma patients evaluated with multidetector CT venography. *Radiology* 2010;255:570-7.
10. Misra UK, Kalita J, Bansal V. D-dimer is useful in the diagnosis of cortical venous sinus thrombosis. *Neurol India* 2009;57:50-4.
11. Yokata H, Kurowa A, Otsuka T. Significance of MRI in acute head injury. *J Trauma* 1991;1:351-7.
12. Meltzer H, LoSasso B, Sobo EJ. Depressed occipital skull fracture with associated sagittal sinus occlusion. *J Trauma* 2000;49:981.
13. Uzan M, Ciplak N, Dashti SG, Bozkus H, Erdinçler P, Akman C. Depressed skull fracture overlying the superior sagittal sinus as a cause of benign intracranial hypertension. Case report. *J Neurosurg* 1998;88:598-600.
14. van den Brink WA, Pieterman H, Avezaat CJ. Sagittal sinus occlusion, caused by an overlying depressed cranial fracture, presenting with late signs and symptoms of intracranial hypertension: case report. *Neurosurgery* 1996;38:1044-6.
15. de Bruijn SF, de Haan RJ, Stam J. Clinical features and prognostic factors of cerebral venous sinus thrombosis in a prospective series of 59 patients. For The Cerebral Venous Sinus Thrombosis Study Group. *J Neurol Neurosurg Psychiatry* 2001;70:105-8.
16. Stiefel D, Eich G, Sacher P. Posttraumatic dural sinus thrombosis in children. *Eur J Pediatr Surg* 2000;10:41-4.
17. Satoh H, Uozumi T, Kiya K, Arita K, Kurisu K, Sumida M, Ikawa F. Venous thrombosis after closed head injury: a report of two cases presenting as intracranial hypertension. [Article in Japanese] *No Shinkei Geka* 1993;21:953-7. [Abstract]
18. Ma J, Song T, Hu W, Muhumuza ME, Zhao W, Yang S, et al. Reconstruction of the superior sagittal sinus with silicone tubing. *Neurosurg Focus* 2002;12:15.
19. Sani S, Jobe KW, Byrne RW. Successful repair of an intracranial nail-gun injury involving the parietal region and the superior sagittal sinus. Case report. *J Neurosurg* 2005;103:567-

- 9.
20. Sindou M, Auque J, Jouanneau E. Neurosurgery and the intracranial venous system. *Acta Neurochir Suppl* 2005;94:167-75.
21. Stam J, Majoie CB, van Delden OM, van Lienden KP, Reekers JA. Endovascular thrombectomy and thrombolysis for severe cerebral sinus thrombosis: a prospective study. *Stroke* 2008;39:1487-90.
22. Yamashita S, Matsumoto Y, Tamiya T, Kawanishi M, Shindo A, Nakamura T, et al. Mechanical thrombolysis for treatment of acute sinus thrombosis-case report. *Neurol Med Chir (Tokyo)* 2005;45:635-9.
23. Li B, Guo M, Li S, Wang M. Endovascular thrombolysis and stent angioplasty for obliteration in cerebral venous sinuses. [Article in Chinese] *Zhonghua Wai Ke Za Zhi* 2002;40:890-2. [Abstract]
24. Ferrera PC, Pauze DR, Chan L. Sagittal sinus thrombosis after closed head injury. *Am J Emerg Med* 1998;16:382-5.