



# End-to-side anastomosis for limb salvage in the single artery of a traumatized extremity

Bacağın kurtarılması amacıyla travmalı ekstremitenin tek arterine uygulanan uç-yan anastomoz

Mohammad Reza GHAZISAIDI,<sup>1</sup> Naser MOZAFARI,<sup>1</sup> Masoud YAVARI,<sup>1</sup> Seyed Nejat HOSSEINI<sup>2</sup>

## BACKGROUND

The purpose of this article is to describe and highlight our experience of end-to-side anastomosis technique in such cases for limbs salvage in the single artery of a traumatized extremity with free-flap transfer.

## METHODS

Thirty-two traumatized patients in need of free-flap transfer for their extremity reconstruction were referred to our hospital from March 2006 to November 2008. Angiography was performed in all patients. A single artery was confirmed in 11 cases (Gustilo IIIC). End-to-side anastomosis was applied for limb salvage in single-artery extremity reconstruction, such as preserving recipient's flow and preserving donor's flow in 11 patients.

## RESULTS

The anastomosis arteries included the popliteal artery (n=3), posterior tibial artery (n=2), peroneal artery (n=5) and radial artery (n=1). The mean time from the injury to the flap reconstruction was 34 days. All patients had severe fracture or bone deficit plus soft tissue defect. Postoperative hospital stay was 12-18 days. Time interval between the injury and referral was 27-45 days. Split thickness skin graft was performed in eight patients.

## CONCLUSION

Free-flap transfer by end-to-side anastomosis for limb salvage with a single artery is a safe procedure, so a vein graft and T and Y shape anastomosis are not necessary.

**Key Words:** End-to-side anastomosis; free flap; single-artery extremity.

## AMAÇ

Bu yazıda, bacaklarda serbest flep transferiyle tek arterli travmalı ekstremitenin kurtarıldığı olgularda, uç-yan anastomoz tekniği deneyimlerimizi vurgulayarak tanımlamak amaçlandı.

## GEREÇ VE YÖNTEM

Travma sonrası ekstremitte rekonstrüksiyonu için serbest flep transferi ihtiyacı olan 32 hasta Mart 2006 ile Kasım 2008 tarihleri arasında hastanemize sevk edildi. Tüm hastalara anjiyografi yapıldı. On bir olgu tek bir arterli olarak doğrulandı (Gustilo IIIC). Alıcının ve vericinin akımlarının sürdürüldüğü 11 hastada, tek arterli ekstremitte rekonstrüksiyonunda ekstremitte kurtarılması için uç-yan anastomoz tekniği uygulandı.

## BULGULAR

Anastomoz uygulanan arterler, popliteal arter (n=3), posterior tibial arter (n=2), peroneal arter (n=5) ve radial arterdi (n=1). Yaralanma ile flep rekonstrüksiyonu arasında geçen ortalama süre 34 gündü. Tüm hastalarda ciddi kırıklar, kemik açığıyla birlikte yumuşak doku defekti vardı. Ameliyat sonrası hastanede kalış süresi 12-18 gün idi. Yaralanma ve sevk edilme arasındaki süre 27-45 gün idi. Kısmi kalınlıkta deri grefti sekiz hastaya yapıldı.

## SONUÇ

Tek bir arterle ekstremitte kurtarılması için uç-yan anastomozla serbest flep transferi güvenli bir işlemdir, bir ven grefti ve T ve Y şeklinde anastomoz gerekli değildir.

**Anahtar Sözcükler:** Uç-yan anastomoz; serbest flep; tek arterli ekstremitte.

<sup>1</sup>Department of Plastic and Microsurgery, 15 Khordad Hospital, Shahid Beheshti University of Medical Sciences, Tehran;

<sup>2</sup>Department of Plastic Zanzan University of Medical Sciences, Zanzan, Iran.

<sup>1</sup>Shahid Beheshti Tıp Bilimleri Üniversitesi, 15 Khordad Hastanesi, Plastik ve Mikrocerrahi Bölümü, Tahran; <sup>2</sup>Zanzan Tıp Bilimleri Üniversitesi Plastik Bölümü, Zanzan, Iran.

With the recent improvements in microsurgical techniques and our better understanding of soft tissue and bone anatomy plus physiology, surgeons have the opportunity to salvage traumatized lower extremities after high-energy injuries, even in developing countries.<sup>[1-4]</sup> In many of the complicated cases, which are referred to plastic surgeons for limb salvage, only one artery remains in the extremity (Gustilo IIIC). Gustilo's widely cited open fracture Types I, II, and III from 1976 were later appended in 1984 with a classification of Type III fracture. Type I open fractures have clean wound less than 1 cm in length. In Type II, the laceration is more than 1 cm. However, there is no extensive soft-tissue damage, skin flaps or avulsions. Type IIIA represents wounds with demarcation of injured from non-injured tissues and in which exposed bone can be covered with local tissue. Wounds in which local soft-tissue coverage is not possible and that have poor wound demarcation are called Type IIIB. Type IIIC refers to open fractures accompanied by arterial injury. High-energy and massive contamination are frequently associated with those wounds. Later, a different system of classification was developed (Types I-IV), with more vascular damage associated with Types III and IV. These two classification schemes are helpful in defining the severity of the trauma in order to form an appropriate treatment plan.<sup>[1]</sup> Free-flap transfer for open wound coverage is required in these cases, and deciding how to transfer the free flap without jeopardizing the limb's survival in such cases is a difficult task. In free-flap transfer, the recipient's artery is often sacrificed to provide the pedicle anastomosis. Since the recipient's artery is necessary for distal circulation, preserving its patency is also important (especially in traumatized extremities). In this respect, some of the studies have discussed T or Y arterial shape free flaps,

interposition vein graft for end-to-end anastomosis in proximally ligated artery and end-to-side arterial anastomosis.<sup>[2-7]</sup> Clinical studies and rat models have shown no obvious differences in patency between end-to-end and end-to-side anastomosis.<sup>[2-5]</sup>

Our center is a tertiary referral center in which many complicated cases are referred up to several weeks after their extremity trauma and after several debridements have been done, such that only one artery remains in the extremity. The purpose of this article is to describe and highlight our experience of end-to-side anastomosis technique in such cases for limbs salvage in the single artery of a traumatized extremity with free-flap transfer.

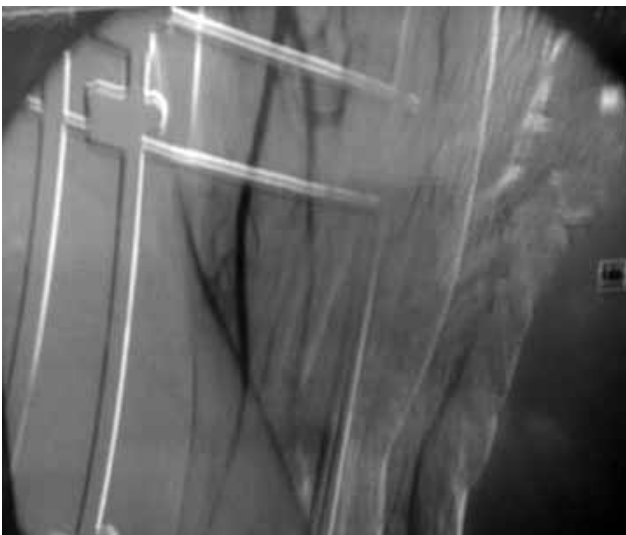
## MATERIALS AND METHODS

### Patients and Surgical Technique

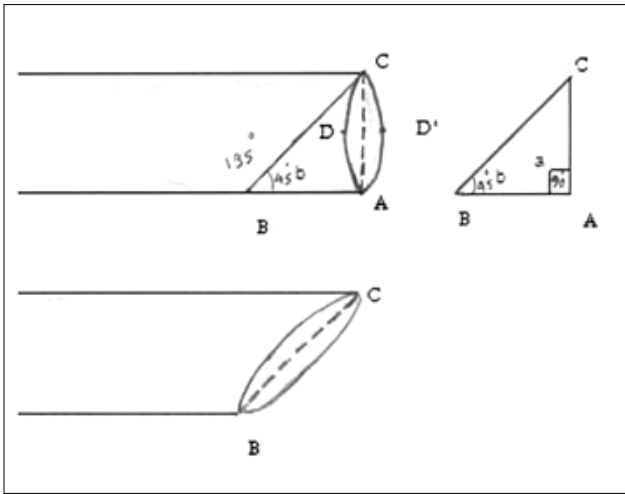
Thirty-two traumatized patients in need of free-flap transfer for their extremity reconstruction were referred to 15 Khordad Hospital of Tehran (Shahid Beheshti University of Medical Sciences) from March 2006 to November 2008. Angiography was performed in all patients. A single artery was confirmed in 11 cases (Gustilo IIIC) (Fig. 1). Two of them were females and the rest males, with an age range of 12 to 43 years. Their weight ranged between 36 to 88 kg and height between 125 to 190 cm. Seven of the patients had been transferred to us from other provinces. The mechanisms of trauma were motorcycle accident (7 patients), car accident (3 patients) and crush injury (1 patient). Popliteal artery repair was performed in two patients.

Two arteries of the lower leg were ligated due to severe injury and one artery remained in all the patients. These procedures were performed in other centers and they were referred to us from between 27-45 days afterwards. Written informed consent was obtained from all patients prior to their enrollment in the study. They were aware of the multistage process of reconstruction and the possibility of a late limb amputation.

Eleven free flaps were performed by end-to-side anastomosis in the patients with single-artery extremities (i.e. those with only one artery remaining) who had no systemic disease. First, the patients were placed in a lateral decubitus position. Then, micro-anastomoses were performed on the single artery of the lower extremity in 10 patients. Micro-anastomosis was performed in the supine position on the single artery of the upper extremity in one patient. Anastomosis was attempted on the periphery of the injury zone. Proper and meticulous microsurgical techniques were performed in all patients. The procedure was performed using tourniquet in the lateral position. A 2 to 4 cm segment of the recipient's artery was prepared by clearing away the perivascular tissue. First,



**Fig. 1.** Radial single artery in angiography; ulnar artery cut in mid-forearm and 10 cm radius bone lose.



**Fig. 2.** Flap artery beveling and circle converted to oval shape.

the donor's artery was beveled 45° from the heel (i.e. inferior level) to the toe (i.e. superior level). The circle pattern thus converts to an oval pattern. The length of BC equals approximately the slit arteriotomy of the recipient's artery. Slit arteriotomy was 40%- 50% more than the donor's artery in diameter ( $BC^2 = AC^2 + AB^2$ ) (Fig. 2). With this technique, the donor's artery was stretched and cupped over the slit arteriotomy. This helped us to perform proper micro-anastomoses. As a result, a 45° end-to-side anastomosis was usually planned between the recipient's artery and donor's artery. The position of the slit on the recipient's artery was lateral or anterolateral. The ultimate longitudinal slit was made about 1.5 times larger than the flap artery in diameter (BC) with the N11 knife (Fig. 2).

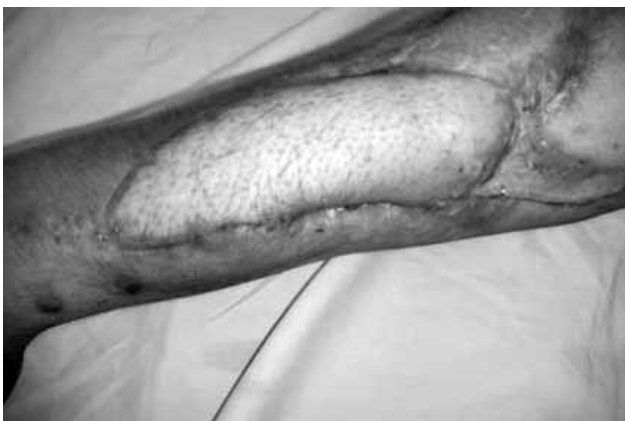Beginning at the heel, interrupted sutures were placed sequentially feeding the redundant vessel towards the toe. On the far side, the suturing of the corners was done by first terminating the middle portion where the exposure is good. The end product was anticipated to be a well-stretched donor vessel that end-

cupped over the slit arteriotomy. As much as possible, the needle was passed inside-to-outside on the recipient's artery, to tag the intima. We commonly used 9/0 polypropylene sutures for the anastomosis. After arterial anastomosis, the resulting blood circulation into the flap was immediately confirmed by flap bleeding or oozing, extremity pulse and intraoperative ultrasound.

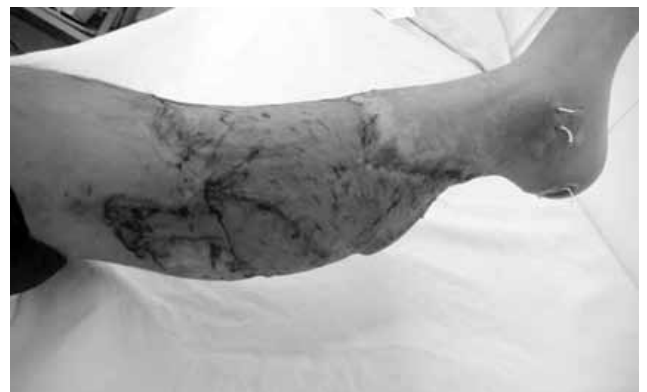All the veins were anastomosed by end-to-end technique. Split thickness skin graft was performed from the 5th to the 10th postoperative day whenever needed. The patients were monitored every hour for the first 24 hours and every two hours until 72 hours by an assistant of plastic surgery. The records were reviewed to assess the type and mechanism of injury, concomitant injuries, number of pre-flap operations, timing from injury to flap transfer, preoperative vascular studies, flap viability, and minor and major complications. The average follow-up period was 14 months (range: 6 to 24 months).

## RESULTS

A total of 32 patients were included in the study. Eleven patients (12 to 43 years old) with single artery were confirmed by angiography. Free flaps were performed by end-to-side anastomosis in these patients who had a single artery remaining in their extremities after major trauma (Gustilo IIIC). End-to-end anastomosis was performed on the other patients (n=21). End-to-side anastomosis was applied for limb salvage in extremity reconstruction with a single artery, preserving recipient's flow and preserving donor's flow in all patients (Figs. 3-5). It should be mentioned that seven of the patients had been transferred to us from other provinces. The mean time from the injury to the flap reconstruction was 34 days. All patients had severe fracture or bone deficit plus soft tissue defect. The mechanism of injury, defect location, type of flap, recipient's artery, and others data are included in Table 1. Post-



**Fig. 3.** Free fibula transfer with skin paddle forearm reconstruction (after 6 weeks).



**Fig. 4.** Latissimus dorsi musculocutaneous flap transfer after 3 weeks; end-to-side anastomosis was performed in posterior tibialis artery.

**Table 1.** Patient's data

No	Sex/Age	Etiology	Defect site	Bone exposed	Flap	Site of single artery anastomoses	Complication	STSG
1	M/12	Motorcycle accident	Leg (OFSTD)	+	LDMCF	Posterior tibialis artery	Thrombosis	+
2	M/19	Motorcycle accident	Leg (OFSTD)	+	LDMCF	Popliteal artery	-	+
3	M/23	Motorcycle accident	Leg (OFSTD)	+	LDMCF	Popliteal artery	-	-
4	M/36	Motorcycle accident	Leg (OFSTD)	+	LDMCF	Peroneal artery	-	+
5	M/32	Car accident	Leg (OFSTD)	+	LDMCF	Popliteal artery	Wound infection	+
6	M/26	Crush injury	Forearm (BSTD)	-	Fibula flaps	Radial artery	-	-
7	M/43	Motorcycle accident	Leg (BSTD)	-	Fibula flaps	Posterior tibialis artery	-	+
8	M/35	Motorcycle accident	Leg (OFSTD)	+	Radial forearm flap	Peroneal artery	-	+
9	M/22	Car accident	Leg (OFSTD)	+	LDMCF	Peroneal artery	-	+
10	F/22	Car accident	Leg (OFSTD)	+	LDMCF	Peroneal artery	Distal flap necrosis	+
11	F/33	Motorcycle accident	Leg (OFSTD)	-	Radial forearm flap	Peroneal artery	Wound infection	-

F: Female; M: Male; STSG: Split thickness skin graft; OFSTD: Open fracture and soft tissue defect; BSTD: Bone and soft tissue defect; LDMCF: Latissimus dorsi musculocutaneous flap.

operative hospital stay was 12-18 days. Time interval between the injury and referral was 27-45 days. Split thickness skin graft was performed in eight patients. Only one patient developed arterial thrombosis at the anastomoses site, but the removal of the thrombus and reanastomosis resulted in flap survival. This thrombus was due to excessive manipulation of the flap artery. Apart from this, eventually all 11 flaps survived. After an average 14-month follow-up, the flaps had good integration, viability and there were no failures in flaps.

## DISCUSSION

The results of the present study suggest that end-to-side anastomosis for limb salvage with a single artery remaining (for extremity reconstruction) is a safe procedure. When we encounter a severely traumatized extremity that has only one artery left for circulation and that requires a free flap for wound coverage, selecting the type of surgery for limb salvage is a difficult task. There are several choices in this case:

- 1- Using a vein graft between that flap artery and proximally ligated artery.
- 2- Using a T or Y shape anastomosis that is performed with end-to-end anastomoses.
- 3- Using an end-to-side anastomosis above the traumatized level.<sup>[2,4-8]</sup>

The vein graft's disadvantages are the necessity of performing two anastomoses, major dissection in the proximal extremity for recognition of the proximally ligated artery and that artery for flap and, in some cases, dissection is very difficult and detrimental to the limb. At the other hand, several studies demonstrated no obvious differences in patency and free-flap survival rates between end-to-end and end-to-side anastomosis techniques.<sup>[2,9,10]</sup> Furthermore, the use of Y or T anastomosis has been described recently as an alternative option for end-to-end anastomosis in a single-artery extremity.<sup>[7,11]</sup> The major disadvantage of this technique is the need for two anastomoses. It is necessary to have a reliable proximal branch system

for the donor's pedicle, so that the use of free flap is limited.<sup>[8,11]</sup>

Using end-to-side arterial anastomosis in extremity reconstruction was first described and popularized by Godina in 1970.<sup>[12]</sup> The advantages of this technique include: decreased vessel spasm, elimination of vessel mismatch and preservation of the distal run-off.<sup>[2,4,6,12,13]</sup> Adams et al.<sup>[2]</sup> showed that the hole technique is better for large artery (>1.5 mm) and slit technique for small artery (<1.5 mm). This avoids potentially irreversible damage in the recipient vessel. The final result also depends on the surgical expertise. Zhang et al.<sup>[4]</sup> examined the incident angle in carotid to carotid end-to-side anastomosis in rats. They performed anastomoses with angles of 45°, 90°, and 135°, with an elliptical arteriotomy. They concluded no statistically significant flow difference between 45° and 90° anastomoses. Some of the studies recommended that different lengths of slit arteriotomy should be adjusted with the diameter of the donor vessel.<sup>[2]</sup> The length of slit arteriotomy is at least twice the diameter of the donor vessel.<sup>[14]</sup> If the length of the slit arteriotomy is more than twice the diameter of the donor vessel, it leads to the stretching of the donor vessel and caliber narrowing.



**Fig. 5.** Free fibula transfer for radius reconstruction; the fibula was fixed by two plates.

Some surgeons believe that using end-to-side anastomosis in a single-artery extremity endangers the limb survival. However, the overall success depends mainly on the surgical skill, planning and micro-anastomosis technique, whether it is end-to-end or end-to-side. In addition, the surgical technique is a major factor in patency.<sup>[2,4,11]</sup> In this study, we showed, in 11 consecutive cases, that use of this technique is very safe for limb salvage in patients with a single artery. In many of the published studies, these techniques were performed on animals.

In our study, we performed end-to-side anastomosis for limb salvage with a single artery. At first, the donor's artery is beveled 45° from the heel to the toe. Then we use 45° between the donor and recipient's artery. Slit arteriotomy is performed about 1.5 times larger in diameter than the donor's artery so that a well-stretched donor vessel end-cups over the slit arteriotomy. This prevents slit deficiency and slit long. In this way, the blood flow is better without any untoward side effects like turbulation, and caliber narrowing is prevented. Despite the fact that anastomoses were performed in the trauma location, no flap necrosis occurred.

#### Acknowledgement

We would like to thank all the staff of the Microsurgery Department of 15 Khordad hospital for their sincere cooperation. We also thank Seyed Muhammed Hussein Mousavinasab for his efforts in revising and editing our work.

#### REFERENCES

- Gustilo RB, Anderson JT. Prevention of infection in the treatment of one thousand and twenty-five open fractures of long bones: retrospective and prospective analyses. *J Bone Joint Surg [Am]* 1976;58:453-8.
- Adams WP Jr, Ansari MS, Hay MT, Tan J, Robinson JB Jr, Friedman RM, et al. Patency of different arterial and venous end-to-side microanastomosis techniques in a rat model. *Plast Reconstr Surg* 2000;105:156-61.
- Godina M. Early microsurgical reconstruction of complex trauma of the extremities. *Plast Reconstr Surg* 1986;78:285-92.
- Zhong C, Tang NX, Zheng CF, Xu YW, Wang TD. Experimental study on microvascular anastomosis using a dissolvable stent support in the lumen. *Microsurgery* 1991;12:67-71.
- Dotson RJ, Bishop AT, Wood MB, Schroeder A. End-to-end versus end-to-side arterial anastomosis patency in microvascular surgery. *Microsurgery* 1998;18:125-8.
- Verhelle NA, Heymans O. How to deal with difficult microsurgical end-to-side anastomoses. *Microsurgery* 2005;25:203-8.
- Yajima H, Kobata Y, Shigematsu K, Kawamura K, Omokawa S, Takakura Y. Dysvascular lower extremity reconstruction using free flaps with a "Y" configuration of the arterial pedicle. *J Reconstr Microsurg* 2004;20:291-5.
- Kim JT, Kim CY, Kim YH. T-anastomosis in microsurgical free flap reconstruction: an overview of clinical applications. *J Plast Reconstr Aesthet Surg* 2008;61:1157-63.
- Albertengo JB, Rodriguez A, Buncke HJ, Hall EJ. A comparative study of flap survival rates in end-to-end and end-to-side microvascular anastomosis. *Plast Reconstr Surg* 1981;67:194-9.
- Frodel JL, Trachy R, Cummings CW. End-to-end and end-to-side microvascular anastomoses: a comparative study. *Microsurgery* 1986;7:117-23.
- Haas FM, Hellbom BA, Moshhammer HE, Koch H, Pierer GR, Scharnagl E. Salvage of an ischaemic lower limb and a free flap with an arterial Y-graft. Case report. *Scand J Plast Reconstr Surg Hand Surg* 2000;34:177-80.
- Godina M. Preferential use of end-to-side arterial anastomoses in free flap transfers. *Plast Reconstr Surg* 1979;64:673-82.
- Zoubos AB, Seaber AV, Urbaniak JR. Hemodynamic and histological differences in end-to-side anastomoses. *Microsurgery* 1992;13:200-3.
- Rutherford RB. *Vascular surgery*. Philadelphia: Saunders; 2000. p. 484-86.