

# Contribution of the appendix sphericity index in predicting perforated acute appendicitis

✉ Mehmet Şirik, M.D., ✉ İbrahim İnan, M.D.

Adiyaman University Faculty of Medicine, Training and Research Hospital, Department of Radiology, Adiyaman-Turkey

## ABSTRACT

**BACKGROUND:** The purpose of the present study was to investigate the diagnostic value of the appendiceal sphericity index (SI) and appendix diameters in cases of perforated and non-perforated acute appendicitis.

**METHODS:** Eighty-one patients who underwent computed tomography (CT) in our clinic and who were diagnosed with acute appendicitis after histopathological assessment between January 2015 and August 2017 were included in the study. According to their histopathological findings, the patients were divided into two groups: perforated and non-perforated appendicitis. The patients' CT images were re-evaluated with respect to perforation. Long axis and short axis of the appendix and the SI obtained by their proportions were calculated from the appropriate plane on CT. Their parameters and other CT findings as defined in the current literature were analyzed for statistical significance in the detection of perforation.

**RESULTS:** The perforated and non-perforated appendicitis groups consisted of 20 and 61 patients, respectively. For wall defect, abscess, extraluminal air, free fluid, and appendicolith, the sensitivity values were 25%, 15%, 25%, 55%, and 50%, respectively, and the specificity values were 100%, 100%, 100%, 77%, and 70.5%, respectively. Sensitivity and specificity for the SI and long axis of the appendix were calculated as 85% and 90% and 85.2% and 73.8%, respectively ( $p < 0.001$ ).

**CONCLUSION:** Although there are many findings with high specificity in the diagnosis of perforation, their sensitivity is very low when evaluated separately. We consider that the measurement of long-axis length with high sensitivity and the evaluation of SI with high specificity and sensitivity will contribute significantly to the diagnosis of perforation.

**Keywords:** Acute appendicitis; perforated appendicitis; sphericity index.

## INTRODUCTION

Acute appendicitis is the most common cause of acute-onset abdominal pain that results in emergency abdominal surgery.<sup>[1,2]</sup> Uncomplicated acute appendicitis can be diagnosed with high accuracy using ultrasonography (US) and computed tomography (CT). The appearance of a normal appendix in CT images excludes the diagnosis of acute appendicitis. Therefore, the visualization rate of the appendix in CT examination is important.<sup>[3]</sup> Negative laparotomy rates have decreased  $< 2\%$  using CT.<sup>[4]</sup> Despite successful results with early diagnosis and appropriate treatment, severe complications, such as perforation, intra-abdominal abscess, plastron, and gangrenous appendicitis, are observed at high rates (16%–39%).<sup>[2,4,5]</sup>

Perforation is a serious complication that significantly increases the risk of morbidity and mortality, especially in the case of delayed diagnosis and treatment.<sup>[6,7]</sup> As a result of the obstruction of the appendix lumen, luminal fluid accumulation and distension trigger inflammation, leading to perforation.<sup>[8]</sup> The diagnosis of perforated appendicitis is important for treatment choice. Perforated appendicitis is associated with increased pre- and postoperative complications. It also affects the choice of surgical procedure and is usually treated via open surgery or non-surgical treatments, such as antibiotic therapy and/or drainage.<sup>[6]</sup> Although findings, such as extraluminal free air or abscess, are commonly associated with intestinal perforation, they may not be observed in all patients with perforated appendicitis.<sup>[9]</sup> The presence of inflam-

Cite this article as: Şirik M, İnan İ. Contribution of the appendix sphericity index in predicting perforated acute appendicitis. *Ulus Travma Acil Cerrahi Derg*

Address for correspondence: Mehmet Şirik, M.D.

Adres bilgisi: Adiyaman Üniversitesi Tıp Fakültesi Eğitim ve Araştırma Hastanesi, Radyoloji Anabilim Dalı, 02100 Adiyaman, Turkey.

Tel: +90 416 - 216 10 15 / 2230 E-mail: dr.mmtsirk@gmail.com

*Ulus Travma Acil Cerrahi Derg* DOI: 10.5505/tjtes.2018.29266 Submitted: 26.03.2018 Accepted: 16.11.2018 Online: 23.01.2019

Copyright 2019 Turkish Association of Trauma and Emergency Surgery

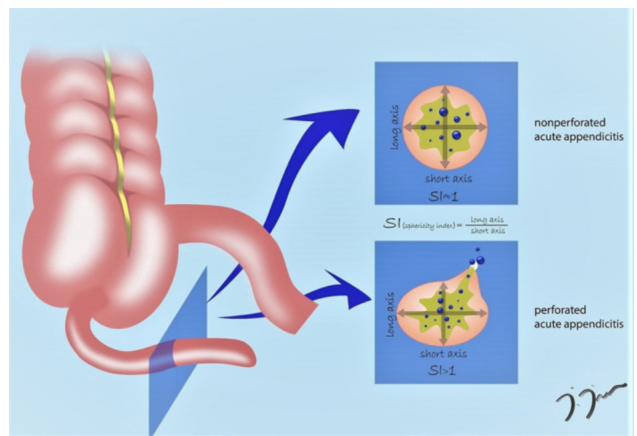


mation around the appendix is a non-specific finding that may indicate perforation. In addition, it is known that perforation risk is higher in patients with radiologically detected appendicoliths. Therefore, it should be noted that perforation may occur especially in cases with multiple appendicoliths or signs of inflammation around the appendix.<sup>[10,11]</sup> The presence of extraluminal air or appendicoliths, formation of an abscess or phlegmon, and appendiceal wall defects are other findings indicating that acute appendicitis is complicated by perforation.<sup>[9]</sup> In the current study, we investigated the efficacy of existing CT findings in detecting perforated acute appendicitis and evaluated the significance of appendiceal diameters and appendix sphericity index (SI) measurements obtained from sections perpendicular to the appendix lumen in the diagnosis of perforation.

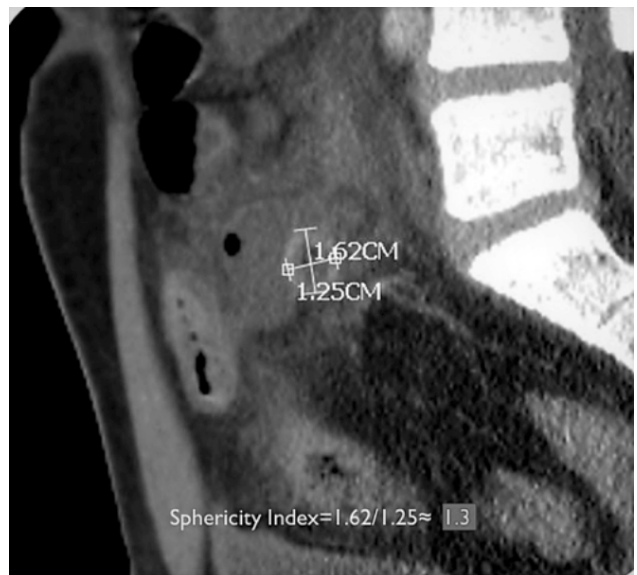## MATERIALS AND METHODS

A total of 81 patients who underwent abdominal CT with a pre-diagnosis of acute appendicitis and were histopathologically diagnosed with perforated or non-perforated acute appendicitis following surgical treatment were included in the study. Approval from the ethics committee was obtained, and CT images were retrospectively evaluated. CT scans were performed on a 64-slice multislice CT scanner (Aquilion; Toshiba, Japan). Routine abdominal tomography scans and portal phase images were obtained 60–70 s after the administration of 70–80 mL non-ionic iodinated contrast material and 40 mL saline at an injection rate of 2.5–3 mL/s to examine the venous structures in the abdomen. CT scans were evaluated on a workstation (Vitrea; Toshiba, Japan).

The evaluation of CT images was conducted by a single experienced radiologist. Patients for whom the appendix lumen was not clearly visualized, the interval between CT and surgery was >12 h, the quality of images was not optimal, or histopathological data were not available were excluded from the study. SI was calculated based on the ratio of the long-axis length to the short-axis length as measured in the CT plane perpendicular to the appendix (Figs. 1 and 2). In cases where any of the sagittal, coronal, and axial sections of CT were not perpendicular to the appendix and the optimal appendix section could not be visualized on these planes, the measurements were collected from the oblique section images obtained by multiplanar reconstruction. Images of the oblique section perpendicular to the lumen in the widest part of the appendix were obtained by reconstruction of thin-section CT images containing volumetric data. Volumetric CT images with a slice thickness of 1 mm were used to obtain the optimal oblique section perpendicular to the appendix lumen from the multiplanar reconstruction panel by the same radiologist on a workstation. Pathological evaluation was accepted as the gold standard for diagnosis of perforation, and the significance of long-axis length, short-axis length, and SI was evaluated in cases with and without perforation.



**Figure 1.** A schematic diagram of the sphericity index in perforated and non-perforated appendicitis.

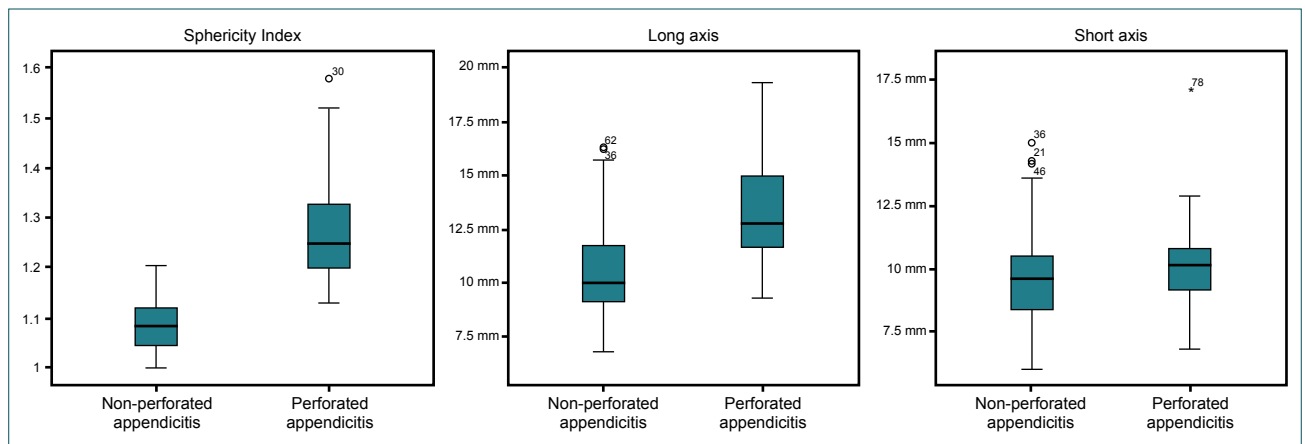


**Figure 2.** The measurement of the sphericity index in a perforated acute appendicitis case using the sagittal-oblique multiplanar reconstruction CT image. Small abscess foci containing millimetric air are present in the vicinity of the appendix.

Statistical data were analyzed using SPSS version 21.0 (IBM Corp., NY, USA). The Shapiro–Wilk test was used to evaluate the normal distribution of numerical data. The Mann–Whitney U test was used to compare differences between the groups with respect to non-parametric data, and receiver operating characteristic (ROC) curve analysis was performed to calculate the diagnostic performance and predictive value of the same data. Categorical data were compared between the groups using Pearson’s and Fisher’s exact tests.

## RESULTS

Of the 81 cases included in the study, 46 (56.8%) were male, and 35 (43.2%) were female. The pathology results were interpreted as perforated appendicitis in 20 (24.7%) cases and as non-perforated appendicitis in 61 (75.3%) cases. Since age, long-axis length, short-axis length, and SI were not normally



**Figure 3.** A box plot of the distribution of sphericity index, long-axis length, and short-axis length in perforated and non-perforated acute appendicitis cases.

distributed, non-parametric tests were used to compare these data ( $p < 0.001$ ,  $p = 0.023$ ,  $p = 0.003$ , and  $p < 0.001$ , respectively). The median age of the case subjects was 31 years, and the age ranges from 18 to 82 years. The median lengths of the

long axis and short axis were 10.9 mm and 9.7 mm, respectively, and the median SI was 1.1. Figure 3 presents a box plot of long axis, short axis, and SI. Table 1 summarizes the findings of wall defects, abscesses, extraluminal air, free fluid, and

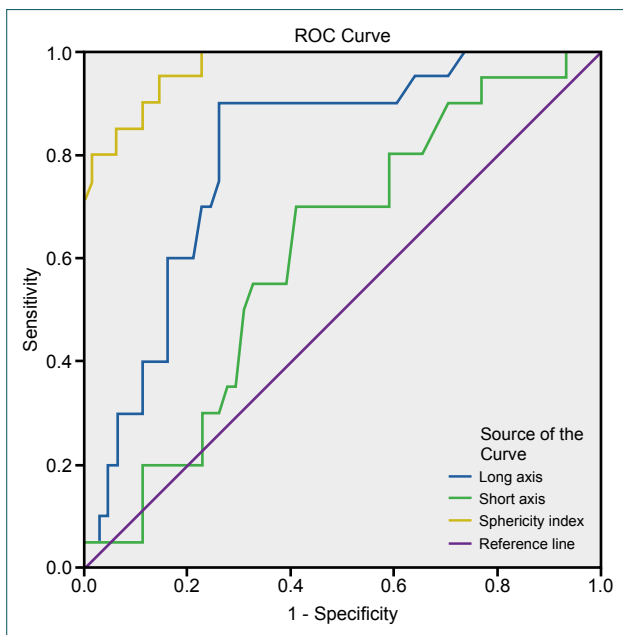
**Table 1.** Distribution of categorical data in perforated and non-perforated appendicitis cases

		Non-perforated appendicitis	Perforated appendicitis
Appendicolith	Present	18	10
	Absent	43	10
Free fluid	Present	14	11
	Absent	47	9
Wall defect	Present	0	5
	Absent	61	15
Abscess	Present	0	3
	Absent	61	17
Extraluminal air	Present	0	5
	Absent	61	15

**Table 2.** Comparative categorical and numerical data between perforated and non-perforated appendicitis cases

	EAA*	p-value	Cut-off value	Sensitivity	Specificity
Sphericity index**	97.1%	<0.001	1.139	85	85.2
Long axis length**	80.1%	<0.001	11.05 mm	90	73.8
Short axis length	61.2%	0.133	–	70	59
Appendicolith	–	0.094	–	50	70.5
Free fluid**	–	0.007	–	55	77
Wall defect**	–	0.013	–	25	100
Abscess**	–	0.007	–	15	100
Extraluminal air**	–	0.013	–	25	100

\*Under the curve. \*\*Statistically significant. \*\*\*Long-axis length, short-axis length, and sphericity index were compared using ROC curve analysis, and the remaining categorical data were compared using Yates's corrected chi-square test and Fisher's exact test.



**Figure 4.** The ROC curves of sphericity index, long-axis length, and short-axis length in perforated and non-perforated acute appendicitis cases.

appendicoliths. For these findings, the sensitivity values were 25%, 15%, 25%, 55%, and 50%, and the specificity values were 100%, 100%, 100%, 77%, and 70.5%, respectively. The sensitivity and specificity values were calculated as 85% and 90%, respectively, for the SI and 85.2% and 73.8%, respectively, for the long-axis length of the appendix ( $p < 0.001$ ; Table 2).

There was a statistically significant difference between perforated and non-perforated appendicitis cases with respect to the mean long-axis length and SI values ( $p < 0.001$  and  $p \leq 0.001$ , respectively); however, there was no significant difference regarding the mean short-axis length ( $p = 0.133$ ). In the ROC curve analysis, the area under the curve was calculated as 97.1% for SI, 80.1% for long-axis length, and 61.2% for short-axis length (Fig. 4). For long-axis length, when the cut-off was calculated as 11.05 mm, the sensitivity was 90%, and the specificity was 73.8%. Based on a cut-off value of 1.14 for SI, the sensitivity and specificity values were found to be 85% and 85.2%, respectively.

## DISCUSSION

Approximately 7% of the population is likely to be affected by appendicitis at some time in their lives, and it is a frequently encountered indication for abdominal surgery.<sup>[12]</sup> Despite physical examination and advanced laboratory and imaging techniques, the rates of misdiagnosis and perforation of appendicitis are still high (9%–20%).<sup>[2,7]</sup> Perforation is a serious complication of acute appendicitis and can cause clinical problems, such as abscess, phlegmon, and peritonitis. Therefore, in addition to the diagnosis of acute appendicitis in radiological evaluation, it is also important for a clinician to report the perforation status. In the case of perforation, the likelihood

of complications, such as repeat surgery and intra-abdominal sepsis, is increased.<sup>[13]</sup> Previous studies have shown that CT and US can be used to detect perforation.<sup>[5,9,10,14]</sup>

US is a valuable method for diagnosis of acute appendicitis, with rates ranging from 75% to 90%. Local fluid in the pericecal area, pericecal area with  $>10$  mm fat tissue, echogenic submucosal layering, and decrease in roundness are important criteria for predicting perforation. Perforation detection rates range from 29% when these findings are evaluated separately to 84% when the findings are combined.<sup>[9,15]</sup> However, extraluminal air, extraluminal appendicoliths, and abscesses can be detected more clearly on CT and have high sensitivity in detecting perforation.<sup>[9]</sup>

Rao et al.<sup>[16]</sup> found a decrease in negative laparotomy rate (from 20% to 7%) and in perforation rate (from 22% to 14%) with the use of appendiceal CT. For this reason, the reporting of perforation on CT images is very important for planning of early treatment and prevention of possible complications.

Borushok et al.<sup>[15]</sup> evaluated the reduction of appendix roundness as an ultrasonographic criterion of perforation and found that it is not significant, with 59.1% sensitivity and 67.9% specificity. However, they did not mention the role of long- and short-axis measurements in the diagnosis of perforation. In our study, the increase in SI and long-axis length was found to be significant with respect to perforation. Although the short axis alone is not significant, it is an important parameter in calculating the SI of the appendix.

Horrow et al.<sup>[9]</sup> reported that the presence of at least one of five findings, such as phlegmon, abscess, extraluminal air, extraluminal appendicolith, and appendiceal wall defect, has a 94.9% sensitivity in the diagnosis of perforated acute appendicitis. However, when the findings were evaluated separately, their sensitivity varied between 21% and 64%. Their study showed that the diameter of the appendix is different in perforated and non-perforated acute appendicitis cases ( $p = 0.049$ ).

Kim et al.<sup>[5]</sup> found that an appendiceal diameter of  $\geq 11$  mm is the most sensitive finding (62.7%) for perforation, and the highest specificity (98.8%) is obtained from the discontinuity of the appendiceal wall. Another previous study evaluated perforation findings in pediatric patients using US and reported that the presence of an abscess, loss of the echogenic submucosal layer, and presence of appendicolith in children  $< 8$  years old provided statistically significant results.<sup>[14]</sup>

In another previous study conducted in 2010, the highest sensitivity was obtained from the mesenteric lymph nodes in the right lower quadrant and the discontinuity of the appendix wall (88.9% and 88.5%, respectively), whereas the highest specificity was observed in the findings of abscess, extraluminal air, and extraluminal appendix (95.2%, 95%, and 95%,

respectively).<sup>[6]</sup> Siddiqui et al.<sup>[17]</sup> reported 69% sensitivity and 97% specificity in the identification of perforation using CT.

In the study by Aydin et al.<sup>[4]</sup> in 2016, in addition to the high values obtained from laboratory tests, such as white blood cells, C-reactive protein, and neutrophil-to-lymphocyte ratio, an appendix diameter >11 mm ( $p=0.002$ ) was found to indicate that appendicitis was accompanied by perforation, gangrene, or abscess.

Ekici et al.<sup>[7]</sup> reported that the length-to-diameter ratio of the appendix is an important indicator for perforation in the evaluation of pathological specimens after appendectomy. According to this study, if the appendix length-to-diameter ratio was <10, perforation frequency increased significantly ( $p<0.01$ ).

Tanrikulu et al.<sup>[2]</sup> investigated the effects of the physical features of the appendix on perforation and reported that body mass index, retrocecal appendix, wall thickness, delayed admission to the hospital, presence of an abscess, appendiceal wall thickness, appendiceal diameter at root level, and length of the appendix are important risk factors for perforation. In this study, measurements were made on pathological specimens, and the appendix diameter was not found to be significant for indicating perforation.

As reviewed by the literature, although there are a large number of findings with high specificity in the diagnosis of perforation, sensitivity is relatively low when these findings are evaluated separately. Most studies refer to a single diameter, which is the largest diameter of the appendix. We hypothesized that a non-perforated appendix would be round (due to distension in the lumen) and that a perforated appendix would be oval (due to loss of pressure in the lumen and possibly with external support of the mesoappendix), as shown in Figure 1. Therefore, we predicted that SI, obtained by dividing the long-axis length by the short-axis length, can be significant in predicting appendix perforation. The results of the present study show that whereas the short-axis measurement was not significant in perforation detection, both SI and long-axis length had significant sensitivity (95% and 90%, respectively) and specificity (85.2% and 73.8%, respectively) in the diagnosis of perforation.

The limitations of the study include the relatively small number of cases, lack of US as the first-step assessment, and lack of evaluation of the consistency of diameter measurements made by different observers. In addition, the maximum time between CT and surgery was 12 h. Cases with perforation that developed after CT examination may cause underestimation of sensitivity.

## Conclusion

We consider that in acute appendicitis cases, the evaluation of the SI in a CT cross-section perpendicular to the appendix

lumen can contribute to the diagnosis of perforation with high sensitivity and specificity, complementing the other findings defined for the prediction of perforation, and can increase the diagnostic accuracy in suspected cases.

## Acknowledgments

The present study was presented as a selected oral presentation at the 2017 Turkish Radiology Congress.

Conflict of interest: None declared.

## REFERENCES

1. Hekimoğlu K, Yildirim UM, Karabulut E, Coskun M. Comparison of combined oral and i.v. contrast-enhanced versus single i.v. contrast-enhanced mdct for the detection of acute appendicitis. *JBR-BTR* 2011;94:278–82.
2. Tanrikulu Y, Yılmaz G, Şen Tanrikulu C, Temi V, Köktürk F, Çağsar M, et al. A prospective clinical study of the effects of the physical features of the appendix on perforation. *Ulus Travma Acil Cerrahi Derg* 2015;21:440–5.
3. Willekens I, Peeters E, De Maeseneer M, de Mey J. The normal appendix on CT: does size matter? *PLoS One* 2014;9:e96476.
4. Aydin OU, Soylu L, Dandin O, Uysal Aydin E, Karademir S. Laboratory in complicated appendicitis prediction and predictive value of monitoring. *Bratisl Lek Listy* 2016;117:697–701.
5. Kim MS, Park HW, Park JY, Park HJ, Lee SY, Hong HP, et al. Differentiation of early perforated from nonperforated appendicitis: MDCT findings, MDCT diagnostic performance, and clinical outcome. *Abdom Imaging* 2014;39:459–66.
6. Suthikeeree W, Lertdomrongdej L, Charoensak A. Diagnostic performance of CT findings in differentiation of perforated from nonperforated appendicitis. *J Med Assoc Thai* 2010;93:1422–9.
7. Ekici U, Tatlı F, Kanlıoz M. Is the appendix length/diameter ratio an early-indicator for the perforation in acute appendicitis? *Annals of Medical Research* 2018;25:390–3.
8. Pinto Leite N, Pereira JM, Cunha R, Pinto P, Sirlin C. CT evaluation of appendicitis and its complications: imaging techniques and key diagnostic findings. *AJR Am J Roentgenol* 2005;185:406–17.
9. Horrow MM, White DS, Horrow JC. Differentiation of perforated from nonperforated appendicitis at CT. *Radiology* 2003;227:46–51.
10. Birnbaum BA, Wilson SR. Appendicitis at the millennium. *Radiology* 2000;215:337–48.
11. Sivit CJ. Diagnosis of acute appendicitis in children: spectrum of sonographic findings. *AJR Am J Roentgenol* 1993;161:147–52.
12. Şahbaz NA, Bat O, Kaya B, Ulukent SC, İlkül Ö, Özgün MY, et al. The clinical value of leucocyte count and neutrophil percentage in diagnosing uncomplicated (simple) appendicitis and predicting complicated appendicitis. *Ulus Travma Acil Cerrahi Derg* 2014;20:423–6.
13. Hale DA, Molloy M, Pearl RH, Schutt DC, Jaques DP. Appendectomy: a contemporary appraisal. *Ann Surg* 1997;225:252–61.
14. Blumfield E, Nayak G, Srinivasan R, Muranaka MT, Blitman NM, Blumfield A, et al. Ultrasound for differentiation between perforated and nonperforated appendicitis in pediatric patients. *AJR Am J Roentgenol* 2013;200:957–62.
15. Borushok KF, Jeffrey RB Jr, Laing FC, Townsend RR. Sonographic diagnosis of perforation in patients with acute appendicitis. *AJR Am J Roentgenol* 1990;154:275–8.



16. Rao PM, Rhea JT, Rattner DW, Venus LG, Novelline RA. Introduction of appendiceal CT: impact on negative appendectomy and appendiceal perforation rates. *Ann Surg* 1999;229:344–9.
17. Siddiqui AH, Afzal S. Perforated appendicitis: accuracy of ct diagnosis and correlation of ct findings with the length of hospital stay. *J Coll Physicians Surg Pak* 2007;17:721–5.

## ORJİNAL ÇALIŞMA - ÖZET

### Akut apandisitte apendiks sferisite indeksinin perforasyon tahmininde taniya katkısı

**Dr. Mehmet Şirik, Dr. İbrahim İnan**

Adıyaman Üniversitesi Tıp Fakültesi Eğitim ve Araştırma Hastanesi, Radyoloji Anabilim Dalı, Adıyaman

**AMAÇ:** Çalışmamızda perfore ve nonperfore apandisit olgularında apendiks sferisite indeksi ve apendiks çaplarının ve perforasyon tespitinde taniya katkısını değerlendirdik.

**GEREÇ VE YÖNTEM:** Çalışmaya Ocak 2015–Ağustos 2017 arasında kliniğimizde yapılan bilgisayarlı tomografi (BT) sonucu apandisit ile uyumlu olan ve histopatolojik sonucu apandisit olarak kanıtlanmış 81 hasta dahil edildi. Histopatolojik sonuçlarına göre hastalar perfore ve nonperfore apandisit olmak üzere iki gruba ayrıldı. Hastaların BT görüntüleri perforasyon açısından tekrar değerlendirildi. Uygun BT planından apendiks uzun aksı, kısa aksı ve bunların oranlanması ile elde edilen sferisite indeksi hesaplandı. Her bulgunun duyarlılığı ve özgüllüğü perforasyon tanısında literatürde tanımlanmış diğer BT bulguları ile birlikte gruplar arasında istatistiksel olarak analiz edildi.

**BULGULAR:** Perfore grup 20, nonperfore grup 61 hastadan oluşmaktaydı. Duvar defekti, apse, ekstralüminal hava, serbest sıvı ve apendikolit bulguları için sensitivite değerleri sırasıyla %25, %15, %25, %55, %50, spesifite değerleri sırasıyla %100, %100, %100, %77, %70.5 iken, sferisite indeksi ve apendiks uzun aksı için sensitivite değerleri sırasıyla %85 ve %90 spesifite değerleri sırasıyla %85.2 ve %73.8 olarak hesaplandı ( $p<0.001$ ).

**TARTIŞMA:** Perforasyon tanısında yüksek özgüllüğe sahip çok sayıda bulgu olmasına rağmen bulgular ayrı ayrı değerlendirildiğinde duyarlılık oldukça düşüktür. Uzun aks ölçümünün yüksek duyarlılık; sferisite indeksi değerlendirilmesinin ise yüksek duyarlılık ve özgüllük ile perforasyon tanısına önemli katkı sağlayabileceğini düşünmekteyiz.

**Anahtar sözcükler:** Akut apandisit; perfore apandisit; sferisite indeksi.

Ulus Travma Acil Cerrahi Derg doi: 10.5505/tjtes.2018.29266