

CASE REPORT

Laryngeal adenoid cystic carcinoma in an adolescent

Ergen bir hastada larengeal adenoid kistik karsinom

Ömer AYDIN, M.D., Emre ÜSTÜNDAĞ, M.D., Mete İŞERİ, M.D., Cengiz ERÇİN, M.D.¹

Malignant tumors of the larynx are extremely rare in children and adolescents. Adenoid cystic carcinoma accounts for less than 1% of all malignant tumors in the larynx. We presented a 16-year-old girl with subglottic adenoid cystic carcinoma, whose symptoms of prolonged and exacerbating dyspnea had been attributed to asthma at another medical center. Indirect flexible and rigid laryngoscopy revealed a smooth mass in the subglottic region occupying 80% of the airway passage. The lesion was also confirmed by both CT and MRI. There was no lymphadenopathy in the neck. The patient was successfully treated by surgery and postoperative radiotherapy. Pathological staging was T₄N₀M₀ according to the AJCC, 2003. During six years of follow-up, there was no evidence for local recurrence or regional and distant metastasis.

Key Words: Adolescent; carcinoma, adenoid cystic/surgery; child; laryngeal neoplasms/surgery.

Larenksin malign tümörleri çocukluk ve ergenlik döneminde çok nadir görülür. Adenoid kistik karsinom bu bölgenin malign tümörlerinin %1'den azını oluşturmaktadır. Bu yazıda, subglottik adenoid kistik karsinom saptanan 16 yaşında bir kız hasta sunuldu. Hastanın uzamış ve şiddetlenen dispne semptomları başka bir merkezde astım lehine yorumlanmıştı. İndirekt fleksibl ve rijid larengoskopide, subglottik bölgede, havayolu pasajını %80 dolduran düz bir kitle görüldü. Lezyon bilgisayarlı tomografi ve manyetik rezonans ile de doğrulandı. Boyunda lenfadenopati yoktu. Hasta başarılı bir şekilde cerrahi ve ameliyat sonrası radyoterapi ile tedavi edildi. Tümörün patolojik evrelemesi AJCC 2003'e göre T₄N₀M₀ bulundu. Hastanın altı yıllık takibi sırasında lokal nüks veya rejyonel ya da uzak metastaz bulgusu saptanmadı.

Anahtar Sözcükler: Ergen; karsinom, adenoid kistik/cerrahi; çocuk; larenks neoplazileri/cerrahi.

Malignant tumors of the larynx are rare in children and adolescents.^[1,2] Among these, adenoid cystic carcinoma (ACC) accounts for less than 1%.^[3,4] Laryngeal ACC probably arises from the endogenous minor salivary gland-like seromucinous glands and two-thirds of these tumors are subglottic.^[5,6] Glandular carcinomas of the larynx tend to spread submucosally, and due to predilection for indolent submucosal growth, most of the patients present with locally advanced tumors at the time of the diagnosis.^[7] We presented

a pediatric patient who was diagnosed as having a laryngeal ACC and discussed potential difficulties in diagnosis and treatment in pediatric patients.

CASE REPORT

A 16-year-old girl was admitted to our clinic with prolonged and recently exacerbating dyspnea lasting for two years. She was previously diagnosed as having asthma at another medical center. The patient had no history of hoarseness or dysphagia.

♦ Departments of Otolaryngology and ¹Pathology, Medicine Faculty of Kocaeli University (Kocaeli Üniversitesi Tıp Fakültesi, Kulak Burun Boğaz Hastalıkları Anabilim Dalı, ¹Patoloji Anabilim Dalı), Kocaeli, Turkey.

♦ Received - December 18, 2006 (Dergiye geliş tarihi - 18 Aralık 2006). Request for revision - March 13, 2007 (Düzeltilme isteği - 13 Mart 2007). Accepted for publication - June 5, 2007 (Yayın için kabul tarihi - 5 Haziran 2007).

♦ Correspondence (İletişim adresi): Dr. Mete İşeri. Kocaeli Üniversitesi Tıp Fakültesi, Kulak Burun Boğaz Hastalıkları Anabilim Dalı, 41380 Umuttepe, Kocaeli, Turkey. Tel: +90 262 - 303 74 33 Fax (Faks): +90 262 - 303 80 03 e-mail (e-posta): metei@superonline.com

Indirect flexible and rigid laryngoscopy revealed a smooth mass in the subglottic region occupying 80% of the airway passage (Fig. 1). The lesion was also confirmed by both CT and MRI (Fig. 2a, b). There was no lymphadenopathy in the neck on palpation and radiological examinations. The chest x-ray was normal.

Exploration under general anesthesia revealed a subglottic mass extending to the third tracheal ring and infiltrating the right thyroid lobe. Histopathologic examination of the frozen biopsy specimen showed an ACC (Fig. 3a, b). Thus, laryngotracheal resection, total thyroidectomy, bilateral paratracheal dissection, and superior mediastinal dissections were performed. Total laryngectomy and total thyroidectomy specimens were reported as ACC and colloid nodular goiter, respectively. There was no lymph node metastasis in bilateral paratracheal and superior mediastinal lymph node dissection materials on final histopathologic examination. Surgical borders and recurrent laryngeal nerves revealed no histopathologic evidence for tumoral invasion. Pathological staging was T₄N₀M₀ according to the AJCC, 2003. The Blom-Singer indwelling voice prosthesis was inserted at surgery to provide phonation. Postoperative radiotherapy was also applied with a dose of 25,000 Gy in five weeks. During the first six years of follow-up, there was no evidence for local recurrence or regional and distant metastasis.

DISCUSSION

Cancer of the larynx in childhood and adolescent period is very rare in the literature. For those under the age of 15 years, laryngeal cancer accounts for

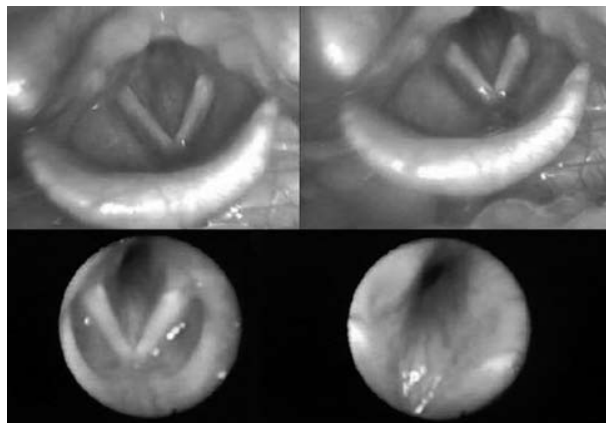


Fig. 1. Rigid (top left and right) and flexible (bottom left and right) endoscopic views of the subglottic mass.

less than 0.1% of all head and neck malignancies.^[1,8] Primary nonsquamous laryngeal carcinomas in this age group are usually adenocarcinoma, mucoepidermoid carcinoma, and adenoid cystic carcinoma.^[1-3] No known risk factor has been suggested for children, although smoking is the most common reported risk factor in adults. The male-to-female ratio of childhood cases is 1:1.7, which is 9:1 in adult patients.^[8]

Glandular tumor is also rare in the larynx, accounting for 0.1% to 1% of all laryngeal neoplasms.^[7] Alavi et al.^[7] reported 1,547 invasive squamous carcinomas and 12 glandular carcinomas between 1950 and 1988. Five of the glandular carcinomas were ACC in their series. Dahm et al.^[9] reported 2,201 laryngeal cancers, and among them only one was ACC. The age of patients at the time of diagnosis ranges from 30 to 70 years, with a preponderance in the sixth and

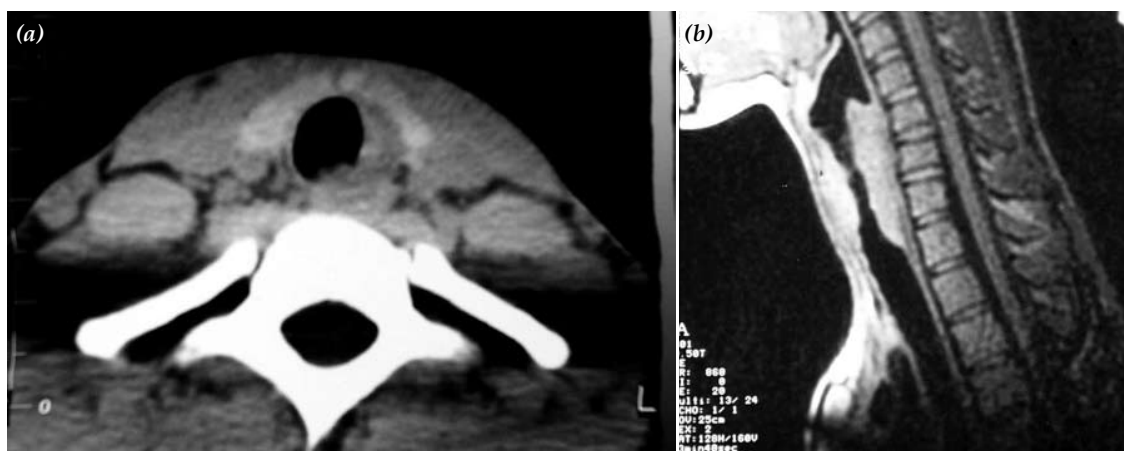


Fig. 2. (a) Axial CT scan clearly indicates the subglottic mass. (b) Sagittal T₁-weighted magnetic resonance image demonstrating the mass with 3-cm subglottic extension.

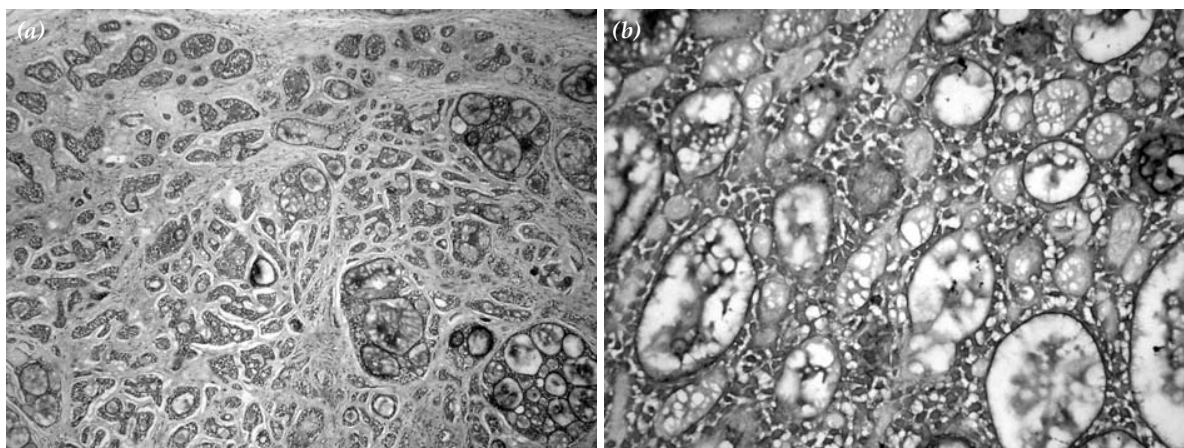


Fig. 3. (a) Cribriform pattern of adenoid cystic carcinoma is seen in the submucosa of the involved laryngeal tissue (H-E x 40). (b) Atypical glandular structures and loose myxoid stroma are observed (H-E x 200).

seventh decades.^[4] Although it is rare under 20 years of age,^[10] Javadi^[3] reported a 12-year-old boy with a subglottic ACC. Our patient was 16 years old at the time of diagnosis, representing one of the youngest cases described in the literature.

Adenoid cystic carcinoma is usually located in the subglottic region and has classically been described as having an indolent, but persistent and recurrent growth with a high incidence of late metastasis.^[6,11] Subglottic tumors tend to spread circumferentially and generally present as dyspnea and stridor. Other symptoms may include cough, neck pain, and vocal cord palsy. The diagnosis of tumors in the subglottic region is not easy because of difficulty in examination and asymptomatic course of the disease even at the advanced stage. In younger patients, the diagnosis may be more difficult since the presenting symptoms are usually similar to those of inflammatory or benign laryngeal diseases, and neoplasms are not often suspected. Therefore, the probability of malignancy must be considered in the differential diagnosis of patients who have progressive and prolonged symptoms of upper airway obstruction in spite of treatment.

Conventional treatment for this type of tumors is wide excision. Because the incidence of lymph node metastasis is rare, elective neck dissection in the absence of palpable lymph nodes is not recommended for ACC of the larynx.^[4,5] These tumors have been shown to be radiosensitive, but usually are not radiocurable. However, most authors believe that postoperative radiotherapy may provide better prognosis with a higher survival rate.^[5,7,10] The

survival rate is approximately 40% for 20 years with adequate surgical treatment and postoperative radiotherapy.^[12]

Histological subtype, histological grade, and perineural invasion are main prognostic factors for ACCs. Microscopic examination shows a growth pattern of glandular, cribriform, or solid. Several studies reported a more favorable prognosis for the tubular and cribriform pattern of ACC, compared to that of the solid variant.^[11,12] In addition, the solid variant of ACC should be differentiated from basaloid squamous cell carcinoma which has a high incidence of neck metastasis.^[13] Although perineural invasion is the most important characteristic of ACC, invasion to the recurrent laryngeal nerve secondary to laryngeal ACC occurs seldom as in our case.^[5,14] Because of the previous misdiagnosis, the proper treatment of the patient was delayed and, at the time of the diagnosis, the stage of the tumor was T₄N₀M₀. However, the cribriform growth pattern and lack of perineural invasion may account for the good survival in our case. Long-term follow-up is crucial to detect and treat any possible recurrence and distant metastasis in this patient.

REFERENCES

1. McGuirt WF Jr, Little JP. Laryngeal cancer in children and adolescents. *Otolaryngol Clin North Am* 1997; 30:207-14.
2. Mitchell DB, Humphreys S, Kearns DB. Mucoepidermoid carcinoma of the larynx in a child. *Int J Pediatr Otorhinolaryngol* 1988;15:211-5.
3. Javadi M, Bafrouee FM, Mohseni M, Asghari A. Laryngeal adenoid cystic carcinoma in a child: a case report. *Ear Nose Throat J* 2002;81:34-5.

4. Tewfik TL, Novick WH, Schipper HM. Adenoid cystic carcinoma of the larynx. *J Otolaryngol* 1983;12:151-4.
5. Cappellari JO. Histopathology and pathologic prognostic indicators. *Otolaryngol Clin North Am* 1997;30:251-68.
6. Ferlito A, Rinaldo A. The pathology and management of subglottic cancer. *Eur Arch Otorhinolaryngol* 2000;257:168-73.
7. Alavi S, Namazie A, Calcaterra TC, Blackwell KE. Glandular carcinoma of the larynx: the UCLA experience. *Ann Otol Rhinol Laryngol* 1999;108:485-9.
8. Barnes C, Sexton M, Sizeland A, Tiedemann K, Berkowitz RG, Waters K. Laryngo-pharyngeal carcinoma in childhood. *Int J Pediatr Otorhinolaryngol* 2001;61:83-6.
9. Dahm JD, Sessions DG, Paniello RC, Harvey J. Primary subglottic cancer. *Laryngoscope* 1998;108:741-6.
10. Shin YJ, Percodani J, Coste EU, Delisle MB, Serrano E, Pessey JJ. Adenoid cystic carcinoma of the larynx. A case report and review of the literature. *Rev Laryngol Otol Rhinol* 1998;119:105-8. [Abstract]
11. Batsakis JG, Luna MA, el-Naggar AK. Nonsquamous carcinomas of the larynx. *Ann Otol Rhinol Laryngol* 1992;101:1024-6.
12. Jones AS, Hamilton JW, Rowley H, Husband D, Helliwell TR. Adenoid cystic carcinoma of the head and neck. *Clin Otolaryngol Allied Sci* 1997;22:434-43.
13. Kaya S. Larenksin seyrek görülen benign ve malign tümörleri. In: Kaya S. Larenks hastalıkları. Ankara: Bilimsel Tıp Yayınevi; 2002. p. 492-539.
14. Hogg RP, Kuo MJ, Olliff J, Das Gupta AR. Invasion of the recurrent laryngeal nerve by adenoid cystic carcinoma. An unusual cause of true vocal fold paralysis. *J Laryngol Otol* 1999;113:260-2.