

CASE REPORT

A case of nasal leiomyosarcoma: the first comparative genomic hybridization analysis

Nazal leiomyosarkomlu bir olguda ilk kez yapılan karşılaştırmalı genomik hibridizasyon analizi

Isabelle PETERS, M.D.,¹ Christian BRUNNER, M.D.,¹ Steffi URBSCHAT, M.D.,² Bernhard SCHICK, M.D.¹

Leiomyosarcomas are rare in the head and neck region. The treatment of choice is surgical resection. We present a case of leiomyosarcoma in a 50-year-old female patient, arising from the inferior turbinate. The tumor was resected by a transnasal micro-endoscopic approach and no evidence for tumor recurrence was found during an endoscopic and radiologic follow-up of two years. Cytogenetic analysis by means of comparative genomic hybridization revealed chromosomal gains at 4p13p15, 6p21p22, 7q22qter, 9q22qter and chromosomal losses at 10q22qter and 19p12p13.1. With augmented experience, the transnasal approach may be appropriate to resect circumscribed malignant tumors located in the nasal cavity.

Key Words: Chromosome mapping; endoscopy/methods; gene amplification; leiomyosarcoma/pathology/surgery/genetics; nose neoplasms; nucleic acid hybridization/methods; soft tissue neoplasms/genetics.

Leiomyosarkomlar baş-boyun bölgesinde nadir görülür. Tedavide cerrahi rezeksiyon tercih edilir. Bu yazıda, inferior turbinattan kaynaklanan leiomyosarkom saptanan 50 yaşındaki bir kadın hasta sunuldu. Cerrahi tedavide transnazal mikro-endoskopik yaklaşım kullanıldı. Hastanın iki yıl süreli endoskopik ve radyolojik izlemde tümör nüksü görülmedi. Karşılaştırmalı genomik hibridizasyon ile yapılan sitogenetik analizlerde, 4p13p15, 6p21p22, 7q22qter ve 9q22qter yerleşimlerinde kromozomal artış, 10q22qter ve 19p12p13.1 yerleşimlerinde kromozomal kayıp saptandı. İleri derecede deneyimle birlikte, nazal kaviteye yerleşik malign tümörlerin rezeksiyonunda transnazal yaklaşımın kullanılması uygun olabilir.

Anahtar Sözcükler: Kromozom haritalandırması; endoskopi/yöntem; gen amplifikasyonu; leiomyosarkom/patoloji/cerrahi/genetik; burun neoplazileri; nükleik asit hibridizasyonu/yöntem; yumuşak doku neoplazileri/genetik.

Leiomyosarcomas are smooth muscle tumors accounting for 7% of all soft tissue sarcomas.^[1,2] This malignant tumor is mainly found in the gastrointestinal tract and the uterus.^[3] The retroperitoneum may also be affected. Leiomyosarcomas involving the nasal cavity or paranasal sinuses are rare. Dobben^[4] reported the first case of leiomyosarcoma arising from the inferior turbinate. Since then, a total

of 41 cases of the nasal cavity or paranasal sinuses have been reported.^[5] To date, none of these tumors has been subjected to comparative genetic hybridization analysis. In this report, a case of leiomyosarcoma arising from the inferior turbinate is presented, together with its transnasal micro-endoscopic resection and findings of comparative genetic hybridization.

◆ ¹Department of Otolaryngology, Head & Neck Surgery, ²Institute of Human Genetics, University Hospital Homburg, Saar, Germany.

◆ Received: July 18, 2003. Accepted for publication: September 17, 2003.

◆ Correspondence: Bernhard Schick, Department of Otolaryngology, Head & Neck Surgery, Kirrberger Straße, University Homburg, Saar, D-66421 Germany. Tel: ++6841-16-22984 Fax: ++6841-16-22997 e-mail: bernhard.schick@hno.imed.uni-erlangen.de

CASE REPORT

A fifty-year-old female patient presented with urticaria. She had no ear, nasal, or pharyngeal complaints. She denied nasal obstruction, nasal bleeding or a recurrent head and neck infection. Rhinoscopy revealed a spheroid, reddish tumoral mass arising from the right inferior turbinate, with a vascular plexus on its surface. Computed tomography demonstrated a mass occupying lesion in the right nasal cavity, 2x6 cm in size. A convex excursion was noted in the right medial maxillary sinus wall and a bony destruction was found at the apical, dorsal part thereof (Fig. 1a, b).

Transnasal micro-endoscopic tumor resection was performed with frozen section analysis for the resection margins to ensure complete tumor removal. A part of the tumor specimen was immediately stored at -80 °C for genetic analysis. Histopathologic evaluation showed a spindle cell

rich neoplasm with a proliferation index of 10% and strong alpha-actin positive immunoreactivity leading to a diagnosis of low-grade leiomyosarcoma. No evidence for metastasis was detected by ultrasonography of the neck and abdomen, chest X-ray, and bone scintigraphy. During a follow-up of two years, the patient was examined quarterly by endoscopy, and annually by magnetic resonance imaging. No recurrence was encountered (Fig. 1c, d).

Comparative genomic hybridization was performed as described in detail before^[6] after isolation of tumor DNA and control DNA from a male donor. We found chromosomal gains at 4p13p15, 6p21p22, 7q22qter, and 9q22qter. Chromosomal losses were observed at 10q22qter and 19p12p13.1 (Fig. 2).

DISCUSSION

Leiomyosarcoma of the nose and paranasal sinuses is a rare tumor being reported in only 41

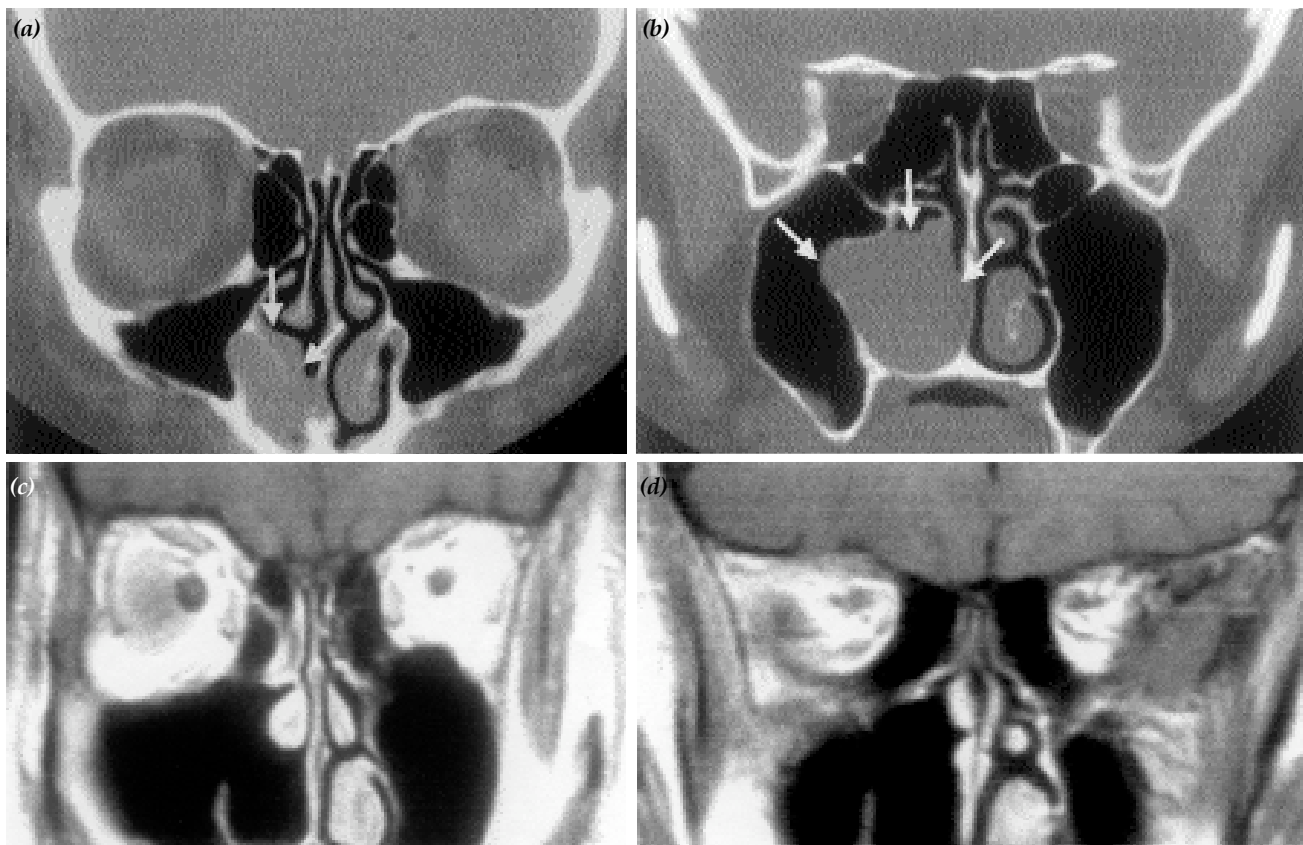


Fig. 1 - (a, b) Native coronal computed tomography demonstrating a tumoral mass in the right nasal cavity arising from the inferior turbinate and causing an excursion of the medial maxillary sinus wall and a distinct bony destruction (arrows). (c, d) Coronal magnetic resonance imaging two years after endonasal tumor resection indicates no evidence for recurrence of nasal leiomyosarcoma.

cases.^[5] Nasal obstruction, nasal bleeding, pain, nasal discharge, and in advanced cases, swelling of the cheek, and exophthalmus are symptoms of this tumor in that location.^[7] As in any other malignant tumor, early diagnosis is important for optimizing prognosis. Nasal leiomyosarcomas are likely to be detected earlier than those located in the paranasal sinuses. This may be one reason why recurrences after treatment of this neoplasm in nasal location are rather rare compared to paranasal sinus leiomyosarcomas.^[8] In our case, the leiomyosarcoma was incidentally detected prior to any symptoms and was treated at an early stage without any recurrence. Lymph node metastasis is uncommon even in advanced leiomyosarcomas. In five nasal/paranasal leiomyosarcomas previously reported distant metastases were found affecting the lung, liver, or the skeleton.^[8]

Radical surgical tumor removal is the treatment of choice for leiomyosarcomas, because they are known to be radiotherapy- and chemotherapy-resistant.^[9-11] However, the attitude towards radiotherapy has changed with the introduction of neutron radiation. Neutron beam therapy has been recommended for leiomyosarcomas having a high recurrence risk.^[12]

Although transnasal micro-endoscopic tumor resection may be considered insufficient to treat a low-grade malignant tumor of the nasal cavity, it uses a minimally invasive approach through the nostrils and allows radical resections when necessary. The selection of the surgical approach depends mainly on the tumor extension and is influenced by the experience of the surgeon. Delineation of tumor extension has improved tremendously thanks to endoscopic evaluation and advancements in neuro-radiologic investigations. If it is possible to visualize tumor margins completely through the natural nasal openings with the use of a microscope and endoscopy as in our case, the transnasal approach may be a proper option for a surgeon experienced in transnasal surgery. The use of the transnasal approach in selected malignant tumors is also favored by the reports of six esthesioneuroblastomas treated by transnasal endoscopic resection combined with radiosurgery^[13] and endoscopic resection of a nasal hemangiopericytoma.^[14] Nevertheless, further experience is necessary to define the value of transnasal surgery in malignant tumors.

Histopathologic grading of leiomyosarcoma is based mainly on the rate of mitosis and detection of

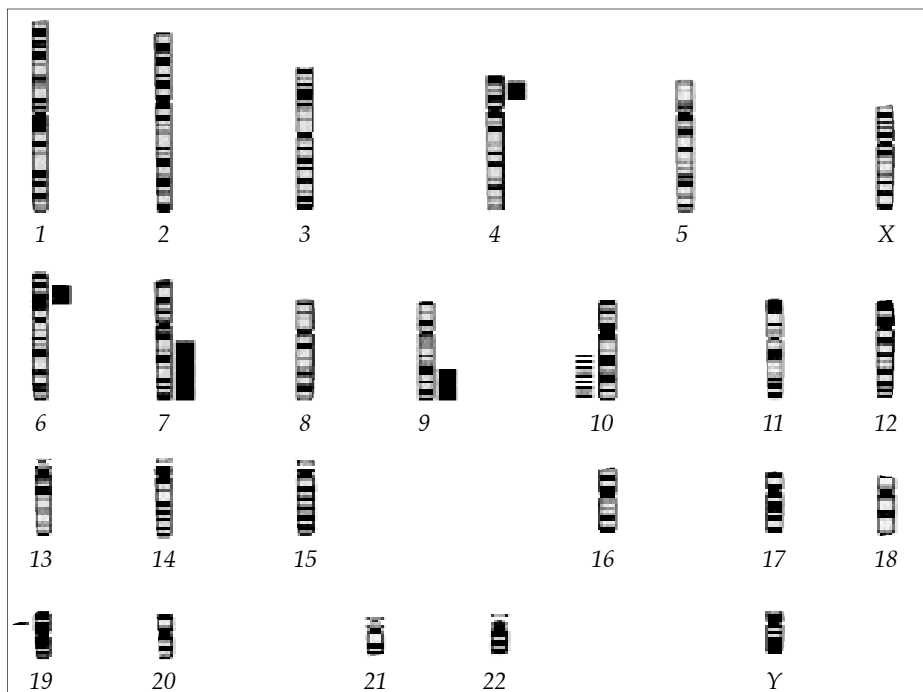


Fig. 2 - An overview of the detected genetic imbalances of the leiomyosarcoma by comparative genomic hybridization. Gains are indicated by grey beams on the right side and losses by striped beams on the left side.

tumor necrosis.^[15] Molecular cytogenetic analysis improves histopathologic grading and can further identify potential candidate genes underlying tumor progression. In our case, determination of chromosomal gain on 4p13p15 may indicate involvement of ras oncogenes in tumor biology as the ras-gene family is located at 4p13.

A synopsis of 169 tumors from 73 diverse neoplasms by comparative genomic hybridization found chromosomal losses at 10q23 and 10q25qter in 25%.^[16] Our detection of chromosomal loss at 10q22qter, which is located in this area, may indicate loss of the tumor suppressor gene PTEN and the MXI 1-gene, the latter of which is known to participate in the regulation of the CMYC-oncogene. In contrast to our findings, analyses of leiomyosarcomas in other locations by comparative genomic hybridization showed chromosomal aberrations at 1q21, 5p14pter, and 20q13.^[10] Moreover, molecular cytogenetic analysis of leiomyosarcomas in other locations documented a significant genetic heterogeneity within a tumor.^[17] It is of our opinion that interpretation of these findings requires some degree of caution.

REFERENCES

1. Enzinger FM. Leiomyosarcoma. In: Enzinger FM, Weiss SW, editors. *Soft tissue tumors*. 2nd ed. St. Louis: Mosby; 1988. p. 402-21.
2. Russell WO, Cohen J, Enzinger FM, Hajdu SI, Heise H, Martin RG, et al. A clinical and pathological staging system for soft tissue sarcomas. *Cancer* 1977;40:1562-70.
3. Thomas G. Tumoren der glatten und quergestreiften Muskulatur. In: Thomas C, editor. *Spezielle Pathologie*. Stuttgart: Schattauer Verlag; 1996. p. 519-21.
4. Dobben GD. Leiomyosarcoma of the nasopharynx. *AMA Arch Otolaryngol* 1958;68:211-3.
5. Batra PS, Kern RC, Pelzer HJ, Haines GK 3rd. Leiomyosarcoma of the sinonasal tract: report of a case. *Otolaryngol Head Neck Surg* 2001;125:663-4.
6. Schick B, Brunner C, Praetorius M, Plinkert PK, Urbschat S. First evidence of genetic imbalances in angiofibromas. *Laryngoscope* 2002;112:397-401.
7. Kuruvilla A, Wenig BM, Humphrey DM, Heffner DK. Leiomyosarcoma of the sinonasal tract. A clinicopathologic study of nine cases. *Arch Otolaryngol Head Neck Surg* 1990;116:1278-86.
8. Lippert BM, Godbersen GS, Luttgies J, Werner JA. Leiomyosarcoma of the nasal cavity. Case report and literature review. *ORL J Otorhinolaryngol Relat Spec* 1996;58:115-20.
9. Dropkin LR, Tang CK, Williams JR. Leiomyosarcoma of the nasal cavity and paranasal sinuses. *Ann Otol Rhinol Laryngol* 1976;85(3 pt 1):399-403.
10. Forus A, Weghuis DO, Smeets D, Fodstad O, Myklebost O, van Kessel AG. Comparative genomic hybridization analysis of human sarcomas: I. Occurrence of genomic imbalances and identification of a novel major amplicon at 1q21-q22 in soft tissue sarcomas. *Genes Chromosomes Cancer* 1995;14:8-14.
11. Kawabe Y, Kondo T, Hosoda S. Two cases of leiomyosarcoma of the maxillary sinuses. *Arch Otolaryngol* 1969;90:492-5.
12. Schmääl F, Laubert A. Rare tumor of the nose and paranasal sinuses. Leiomyosarcoma. [Article in German] *HNO* 1995;43:250-2.
13. Unger F, Walch C, Stammberger H, Papaefthymiou G, Haselsberger K, Pendl G. Olfactory neuroblastoma (esthesioneuroblastoma): report of six cases treated by a novel combination of endoscopic surgery and radiosurgery. *Minim Invasive Neurosurg* 2001;44:79-84.
14. Castelnuovo P, Pagella F, Delu G, Benazzo M, Cerniglia M. Endoscopic resection of nasal haemangiopericytoma. *Eur Arch Otorhinolaryngol* 2003;260:244-7.
15. Jamali Y, Salim PA, Bilkenroth U, Holzhausen HJ. Unilateral nasal breathing difficulties. [Article in German] *HNO* 1999;47: 126-7.
16. Knuutila S, Aalto Y, Autio K, Bjorkqvist AM, El-Rifai W, Hemmer S, et al. DNA copy number losses in human neoplasms. *Am J Pathol* 1999;155:683-94.
17. Wang R, Lu YJ, Fisher C, Bridge JA, Shipley J. Characterization of chromosome aberrations associated with soft-tissue leiomyosarcomas by twenty-four-color karyotyping and comparative genomic hybridization analysis. *Genes Chromosomes Cancer* 2001;31:54-64.