

## ORIGINAL ARTICLE

# Left atrial appendage 2D-strain assessed by transesophageal echocardiography is associated with thromboembolic risk in patients with atrial fibrillation

## Atriyal fibrilasyon hastalarında transözofajiyal ekokardiyografi ile değerlendirilen sol atriyal apendiks 2D strain'i tromboembolik risk ile ilişkilidir

Erhan Saraçoğlu, M.D.,<sup>1</sup> Dilek Ural, M.D.,<sup>2</sup> Salih Kılıç, M.D.,<sup>1</sup> Ertan Vuruşkan, M.D.,<sup>1</sup> Tayfun Şahin, M.D.,<sup>2</sup> Ayşen Ağaçdiken Ağır, M.D.<sup>2</sup>

<sup>1</sup>Department of Cardiology, Gaziantep Dr. Ersin Arslan Training and Research Hospital, Gaziantep, Turkey

<sup>2</sup>Department of Cardiology, Kocaeli University Faculty of Medicine, Kocaeli, Turkey

### ABSTRACT

**Objective:** The aim of this study was to determine the relationship of left atrial appendage (LAA) mechanics assessed using 2-dimensional (2D)-strain analysis of the gray scale images obtained during transesophageal echocardiography (TEE) to the conventional LAA functional parameters, CHA<sub>2</sub>DS<sub>2</sub>-VASc score, and the presence of spontaneous echo contrast (SEC) and/or LAA thrombus in patients with non-valvular atrial fibrillation (AF).

**Methods:** The study included 126 patients with AF and 30 controls with a sinus rhythm who were referred for TEE. The global, medial, lateral and apical LAA longitudinal 2D-strain of all patients and the CHA<sub>2</sub>DS<sub>2</sub>-VASc score of AF patients were evaluated.

**Results:** The global, medial, lateral, and apical LAA longitudinal 2D-strain results of AF patients were significantly lower than those of the controls and revealed moderate but significant correlations with LAA flow velocity and LAA area change. Patients with a CHA<sub>2</sub>DS<sub>2</sub>-VASc score of 0 or 1 had the highest LAA 2D-strain values and the results revealed that the LAA-emptying velocity and LAA lateral and medial 2D-strain values were independent correlates of CHA<sub>2</sub>DS<sub>2</sub>-VASc score. SEC was detected in 84 patients, of whom, 42 had dense SEC and 27 had thrombus in the LAA. Multivariate analysis indicated that LAA emptying velocity, LAA area change, and LAA medial 2D-strain were independently associated with the presence of dense SEC/thrombus. In ROC analysis, cut-off values for global, medial, apical, and lateral 2D-strain for the presence of dense SEC/ thrombus were 6.0% (p=0.011), 8.0% (p=0.032), 6.0% (p=0.033), and 5.4% (p=0.004), respectively.

**Conclusion:** Global and regional LAA mechanics were significantly related to conventional LAA functional parameters and to the presence of LAA-dense SEC/thrombus in patients with AF and may be useful as complementary data for estimating future thromboembolism.

### ÖZET

**Amaç:** Bu çalışmada, valvüler olmayan atriyal fibrilasyonlu (AF) hastalarda transözofajiyal ekokardiyografi (TEE) sırasında elde edilen gri skala görüntülerinde 2B-strain analizi ile değerlendirilen sol atriyal apandis (LAA) mekanik işlevlerinin geleneksel LAA fonksiyonel parametreleri, CHA<sub>2</sub>DS<sub>2</sub>-VASc skoru ve LAA'da spontan eko kontrastı (SEK) ve/veya trombus varlığı ile ilişkisinin belirlenmesi amaçlandı.

**Yöntemler:** Çalışmaya, TEE için sevk edilen 126 AF'li hasta ve 30 sinüs ritminde kontrol alındı. Tüm hastalarının global, mediyal, lateral ve apikal LAA longitudinal 2D-strain'i ve AF hastalarının CHA<sub>2</sub>DS<sub>2</sub>-VASc skoru değerlendirildi.

**Bulgular:** AF hastalarının global, mediyal, lateral ve apikal LAA longitudinal 2D-strain'i kontrollerden anlamlı olarak düşük ve LAA akım hızları ve LAA alan değişikliğiyle orta derecede fakat anlamlı olarak bağıntılıydı. CHA<sub>2</sub>DS<sub>2</sub>-VASc skoru 0-1 olan hastalar en yüksek LAA 2D-strain değerlerine sahipti ve CHA<sub>2</sub>DS<sub>2</sub>-VASc skoru LAA lateral, mediyal ve global 2D-strain ile anlamlı olarak korele idi. Hastaların 84'ünde SEK, bu hastaların 45'inde yoğun SEK ve/veya trombus tespit edildi. Global ve bölgesel LAA 2D-strain değerleri yoğun SEK/ trombusü olan hastalarda anlamlı olarak düşüktü ama çok değişkenli analizde 2D-strain değerlerinin SEK/trombus varlığının bağımsız belirleyicileri olmadıkları görüldü. ROC analizinde, yoğun SEK/trombus varlığı için global, mediyal, apikal ve lateral 2D-strain kestirim değerleri sırasıyla %6.0 (p=0.011), %8.0 (p=0.032), %6.0 (p=0.033) ve %5.4 (p=0.004) idi.

**Sonuç:** Global ve bölgesel LAA mekaniği, geleneksel LAA fonksiyonel parametreleri ve LAA yoğun SEK/trombus varlığı ile anlamlı derecede ilişkilidir ve gelecekteki tromboembolizmi öngördürmede tamamlayıcı bir teknik olarak faydalı olabilir.

Received: November 07, 2018 Accepted: February 07, 2019

Correspondence: Dr. Erhan Saraçoğlu, Gaziantep Dr. Ersin Arslan Eğitim ve Araştırma Hastanesi, Kardiyoloji Kliniği, Gaziantep, Turkey.

Tel: +90 342 - 221 07 00 e-mail: erhansaracoglu@hotmail.com

© 2019 Turkish Society of Cardiology



Active contraction of the left atrial appendage (LAA) in a healthy heart prevents the pooling of blood and the development of a thrombus in the LAA. Conversely, LAA dysfunction predisposes the development of several cardiovascular diseases, especially stroke, primarily via local thrombus formation and systemic embolization. The main left atrial cavity and the LAA originate from different embryonic sources. The trabecular LAA is a remnant of the embryonic left atrium, whereas the smooth-walled part of the left atrium is derived from pulmonary veins.<sup>[1]</sup> This difference may be responsible for dissimilar responses to loading conditions in the main left atrial cavity and the LAA.

Etiologies leading to dilatation of the left atrium may impair LAA function by themselves or by leading to the development of atrial fibrillation (AF). This impairment may be reflected differently in each wall of the LAA. Thus, a direct examination of global and regional LAA function is important for hemodynamic and prognostic evaluation. Thus far, studies that have evaluated regional LAA function have primarily used tissue-Doppler imaging for direct measurements from the LAA wall<sup>[2,3]</sup> or performed strain imaging of the left atrium with transthoracic echocardiography (TTE) for indirect evaluation.<sup>[4]</sup> The main disadvantages of these techniques are the angle-dependency of tissue Doppler imaging, which limits its applicability to a triangular and lobular structure such as the LAA, and the dissimilarities between the left atrium and the LAA.

Speckle tracking echocardiography (STE) is an objective and reproducible method that quantifies global and regional myocardial deformation independently of the angle of insonation or cardiac translational movements.<sup>[5-7]</sup> STE examination measures strain directly from 2-dimensional (2D) grayscale images, and therefore provides a better tool for the evaluation of cardiac mechanics. Including STE in the echocardiographic evaluation of patients with LAA dysfunction, as in patients with AF, may provide more robust data on regional LAA mechanics and improve risk assessment.

Various risk factors have been associated with the occurrence of thromboembolic events in patients with AF, and several scoring systems have been developed to predict the risk of thromboembolism to guide the decision to initiate oral anticoagulants. Among these risk scoring systems, the CHA<sub>2</sub>DS<sub>2</sub>-VASc risk score is

recommended both by US and European guidelines for risk stratification in AF patients.<sup>[8,9]</sup> Previous studies have reported significant associations between the CHA<sub>2</sub>DS<sub>2</sub>-VASc score and left atrial structural and func-

tional parameters on echocardiography,<sup>[10-12]</sup> but the relationship between the CHA<sub>2</sub>DS<sub>2</sub>-VASc score and regional LAA mechanics has not been evaluated in detail. Similarly, data on regional LAA mechanics in the presence of spontaneous echo contrast (SEC) or thrombus are limited.

This study was designed to determine the relationship between global and regional LAA mechanics evaluated directly from 2D grayscale images obtained during transesophageal echocardiography (TEE) (1) and the conventional LAA functional parameters, (2) the CHA<sub>2</sub>DS<sub>2</sub>-VASc score, and (3) the presence of dense SEC and/or LAA thrombus in patients with non-valvular AF.

#### Abbreviations:

|     |  |
|-----|--|
| 2D  | 2-dimensional                            |
| AF  | Atrial fibrillation                      |
| ASE | American Society of Echocardiography     |
| CI  | Confidence interval                      |
| EAE | European Association of Echocardiography |
| LAA | Left atrial appendage                    |
| PW  | Pulsed wave                              |
| ROC | Receiver operating characteristic        |
| SEC | Spontaneous echo contrast                |
| STE | Speckle tracking echocardiography        |
| TEE | Transesophageal echocardiography         |
| TTE | Transthoracic echocardiography           |

## METHODS

### Patients

The study group consisted of patients with persistent or permanent non-valvular AF who had been referred for a TEE examination to evaluate the presence of left atrial thrombus either for diagnostic purposes or before cardioversion. Patients with insufficient clinical information, sinus rhythm, paroxysmal AF, significant valvular heart disease (prosthetic valve, significant valve insufficiency, moderate stenosis), atrial septal defect closed with a device, cardiac mass, restrictive cardiomyopathy, ventricular septal defect, poor image quality, or an LAA morphology hampering STE evaluation, such as pectinated, cauliflower, cactus, and multi-lobed LAA morphologies, were excluded.

Data of patient clinical characteristics and treatment were obtained from interviews and hospital records. The CHA<sub>2</sub>DS<sub>2</sub>-VASc score and presence of left atrial thrombus and/or SEC in LAA were used to assess the thromboembolic risk.

In order to perform a comparison of the echocardiographic data, 30 patients with a sinus rhythm and no significant abnormalities observed on TTE or TEE examination served as the control group.

The study was approved by the ethics committee (date: 29.05.2012, no.: 2012/34) and conducted in accordance with prevailing ethical standards. All of the patients provided their written, informed consent before the study was performed.

### Echocardiographic examination

All of the echocardiographic recordings were performed by 2 physician-echocardiographers (T.S. and E.S.) using commercially available Vivid 7 equipment (GE Vingmed Ultrasound, Horten, Norway) with a standard phased array 2.5 MHz multi-frequency transducer for TTE and a 5 MHz multiplane transducer for TEE examinations.

Conventional TTE was performed according to the consensus recommendations of the American Society of Echocardiography (ASE) and the European Association of Echocardiography (EAE).<sup>[13]</sup> The 2D left ventricular volume was determined using the modified Simpson rule with images obtained from apical 4- and 2-chamber views to calculate the left ventricular ejection fraction.

TEE was performed within 1 month of conventional TTE after at least 4 hours of fasting using 10% lidocaine spray for posterior pharyngeal anesthesia. The LAA was visualized from the mid-esophageal position at an angle (typically 45°–90°) providing the longest apex to the orifice length. The grayscale frame rate was set to 60 to 90 frames/second in patients with AF and adjusted to higher rates in patients with tachycardia. On average, 5 cycles were performed for both 2D and pulsed-wave (PW) Doppler recordings. The maximum and minimum LAA areas were measured with planimetry. The LAA area change was calculated using the following formula:  $\text{LAA area change} = [(\text{maximal LAA area} - \text{minimal LAA area}) / \text{maximal LAA area}] \times 100$ . LAA flow measurements were obtained approximately 1 cm below the outlet of the LAA cavity using PW Doppler with suitable gain and filter adjustments. The LAA emptying and the LAA filling velocities were recorded.

SEC was visualized by adjusting the gain settings to prevent low-amplitude echo images, and it was dis-

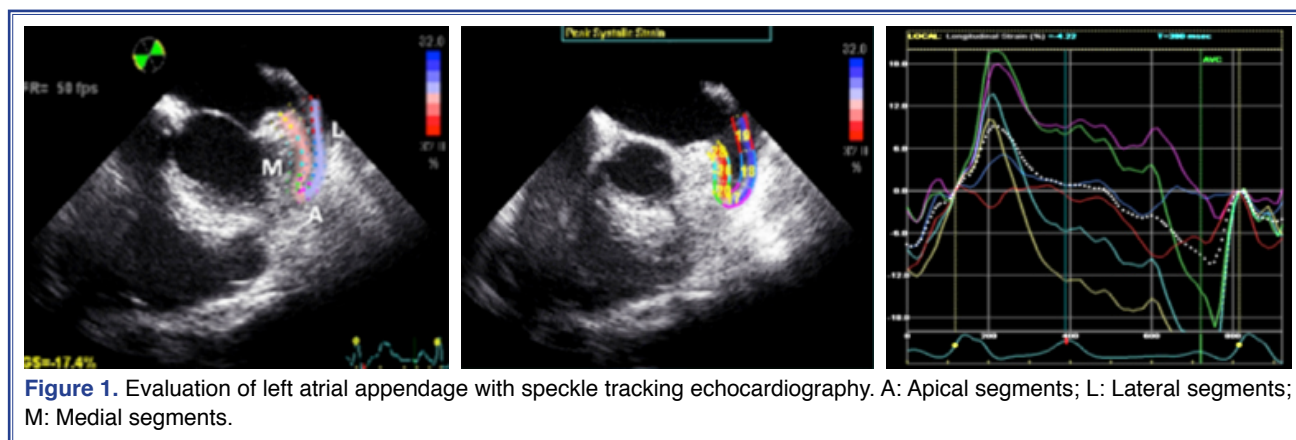
tinguished from white noise artifacts by the chaotic swirling motion of “smoke-like” echoes. The intensity of SEC was graded as none (0: absence of smoke-like echogenicity), mild (1: minimal echogenicity located in LAA or sparsely distributed in the main left atrial cavity detectable only transiently during the cardiac cycle and with increased gain settings), mild–moderate (2: more dense swirling pattern than grade 1+ SEC having similar distribution pattern and detectable without increased gain settings), moderate (3: dense swirling pattern distributed throughout both the left atrium and the LAA, detectable throughout the cardiac cycle), or severe (4: more intense echo density and very slow swirling pattern, greater than grade 3). Dense SEC was defined as moderate or severe SEC. A thrombus in the LAA was defined as a mobile, irregularly shaped, gray, textured density on the image that was acoustically distinct from the surrounding endocardium.

All images were recorded on a hard disk for subsequent offline analysis.

### Speckle tracking echocardiography

The LAA longitudinal strain analysis was performed using 2D images recorded during the TEE examination with EchoPAC PC software, version 6.3 (GE Vingmed Ultrasound, Horten, Norway). After manual selection of the region of interest, the software marked the endocardial, mid-myocardial, and epicardial borders. The accuracy of the borders was controlled by the operator and manually adjusted to cover the full thickness of the LAA wall. Before processing, a cine loop preview was used to confirm whether the internal line of the region of interest followed the LAA endocardial border throughout the cardiac cycle. The software divided LAA images into 6 segments (2 medial, 2 lateral, and 2 apical segments) and generated curves of velocity, strain, and strain rate for each segment. (Fig. 1). Segments that were not tracked adequately were excluded from the analysis.

Longitudinal LAA wall deformation was assessed by measuring the peak 2D-strain value during the LAA contractile period. Due to the small length of the segments, 2 contiguous segments were combined for analysis by averaging the peak 2D-strain values and 3 main LAA segments (i.e., medial, apical, and lateral). The global LAA 2D-strain was obtained by averaging all 6 segmental strain curves if they were tracked adequately.



## Reproducibility

To evaluate intra-observer variability, LAA 2D-strain measurements were repeated 3 separate times by the same operator (E.S.) in 10 randomly selected patients with AF. The intra-observer variability was expressed as the coefficient of variability calculated as the absolute difference in measurements as a percentage of the mean values. The intra-observer variability for 2D-strain was 7.6%, 7.8%, and 8.1% for medial, apical, and lateral segments, respectively.

## Statistical analysis

Continuous data were presented as mean±SD. The Kolmogorov-Smirnov test was used to evaluate whether the distribution of continuous variables was normal. Differences in continuous variables between the 2 groups were determined using Student's t-test or the Mann-Whitney U test. Categorical variables were summarized as percentages and compared using a chi-square test or Fisher's exact test. Correlations of LAA 2D-strain measurements with conventional LAA functional parameters and CHA<sub>2</sub>DS<sub>2</sub>-VASc score were evaluated using Pearson and Spearman analysis, respectively. A multivariable logistic regression analysis was performed to identify LAA functional variables that were independently associated with the presence of dense SEC and/or thrombus using variables with p<0.010 in the univariate analysis. To evaluate the cut-off values of LAA 2D-strain for predicting dense SEC/thrombus, receiver operating characteristic (ROC) curve analysis was performed. Statistical analyses were conducted using IBM SPSS Statistics for Windows, Version 20.0 (IBM Corp., Armonk, NY, USA).

## RESULTS

A total of 126 patients with persistent or permanent AF meeting the inclusion criteria were consecutively enrolled in the study. Baseline clinical characteristics and TEE findings of the patients and the controls are presented in Table 1. All of the global and regional LAA 2D-strain values of the AF patients were significantly impaired compared with the patients with a sinus rhythm. In the AF group, all of the variables showed moderate but statistically significant correlations with the conventional LAA functional parameters. The variables with the greatest correlation with LAA area change were medial and global LAA 2D-strain ( $r=0.39$ ,  $p<0.001$  and  $r=0.37$ , respectively;  $p<0.001$ ), whereas the greatest correlation with LAA emptying velocity was detected in the lateral and global LAA 2D-strain values ( $r=0.38$ ,  $p<0.001$  and  $r=0.37$ , respectively;  $p<0.001$ ). Apical LAA 2D-strain values demonstrated the least correlation with LAA area change and LAA emptying velocity ( $r=0.21$ ,  $p=0.02$  and  $r=0.27$ , respectively;  $p=0.002$ ).

### Association of LAA2D-strain values with the CHA<sub>2</sub>DS<sub>2</sub>-VASc score

The median CHA<sub>2</sub>DS<sub>2</sub>-VASc score of the patients with AF was 2 (interquartile range: 0–7). The global LAA 2D-strain values of patients with a CHA<sub>2</sub>DS<sub>2</sub>-VASc score ≤1 were significantly higher than those of patients with a CHA<sub>2</sub>DS<sub>2</sub>-VASc score >1 ( $7.6±2.2%$  vs.  $5.6±2.2%$ , respectively;  $p<0.001$ ). Likewise, the lateral and medial LAA 2D-strain values demonstrated significant differences between the same groups ( $6.8±2.3%$  vs.  $4.5±1.8%$ ;  $p<0.001$  and  $8.9±2.7%$  vs.  $6.8±3.8%$ ;  $p=0.02$ , respectively).



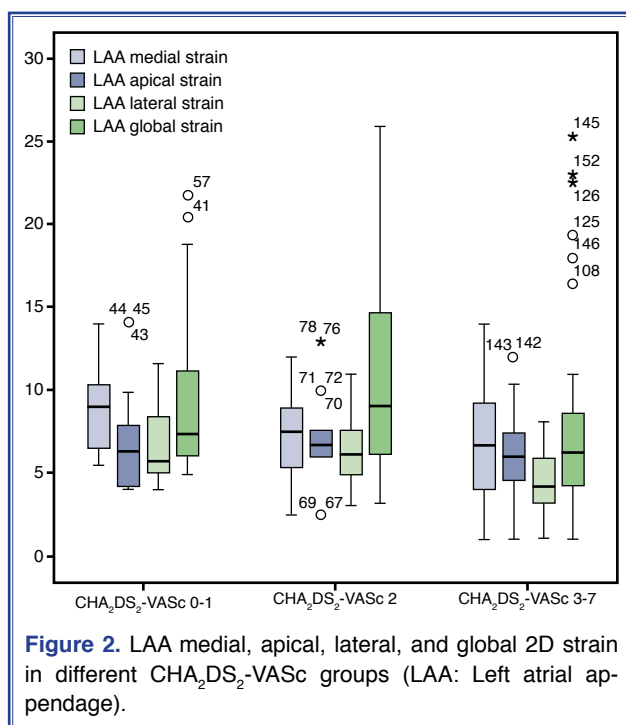
**Table 1. Clinical and echocardiographic characteristics of patients with persistent and permanent AF**

| Clinical characteristics                       | Patients with AF<br>(n=126) | Controls with SR<br>(n=30) | <i>p</i> |
|--|-----------------------------|----------------------------|----------|
| Age (years)                                    | 62 (38–81)                  | 55 (51–61)                 | 0.002    |
| Gender (female, %)                             | 72 (57%)                    | 19 (63%)                   | 0.537    |
| Persistent AF                                  | 86 (68.2%)                  | –                          | –        |
| Permanent AF                                   | 40 (31.8%)                  | –                          | –        |
| Body mass index (kg/m <sup>2</sup> )           | 28.4±4.5                    | 27.4±3.7                   | 0.115    |
| Heart rate (beats/min)                         | 103±23                      | 90±18                      | 0.004    |
| Congestive heart failure or LVEF ≤40%          | 20 (16%)                    | –                          | –        |
| Hypertension                                   | 90 (71%)                    | 18 (60%)                   | 0.223    |
| Diabetes mellitus                              | 39 (31%)                    | 4 (13%)                    | 0.052    |
| History of stroke or TIA or thromboembolism    | 34 (27%)                    | 7 (23%)                    | 0.683    |
| Coronary artery disease                        | 19 (15%)                    | 7 (23%)                    | 0.276    |
| CHA <sub>2</sub> DS <sub>2</sub> -VASc score   |                             |                            |          |
| 0–1  | 33 (26.2%)                  | –                          | –        |
| 2  | 30 (23.8%)                  | –                          | –        |
| 3  | 17 (13.5%)                  | –                          | –        |
| 4  | 16 (12.7%)                  | –                          | –        |
| 5  | 18 (14.3%)                  | –                          | –        |
| 6  | 6 (4.8%)                    | –                          | –        |
| 7  | 6 (4.8%)                    | –                          | –        |
| Conventional echocardiographic data            |                             |                            |          |
| Left atrium diameter (mm)                      | 49±7                        | 41±4                       | <0.001   |
| Interventricular septum (mm)                   | 11±3                        | 11±2                       | 0.602    |
| Posterior wall (mm)                            | 11±2                        | 11±2                       | 0.372    |
| Left ventricle end-diastolic diameter (mm)     | 50±7                        | 48±6                       | 0.518    |
| LVEF (%)                                       | 59±5                        | 64±11                      | 0.083    |
| TEE findings of left atrial appendage function |                             |                            |          |
| Left atrial appendage area change (%)          | 31.1±15.5                   | 66.2±18.8                  | <0.001   |
| Left atrial appendage emptying velocity (cm/s) | 30.2±11.9                   | 62.8±19.6                  | <0.001   |
| Left atrial appendage filling velocity (cm/s)  | 27.4±12.9                   | 50.0±17.8                  | <0.001   |
| Presence of spontaneous echo contrast (%)      | 84 (67%)                    | –                          | –        |
| Presence of left atrium thrombus (%)           | 27 (21%)                    | –                          | –        |
| Left atrial appendage STE examination          |                             |                            |          |
| Left atrial appendage global strain (%)        | 6.3±2.6                     | 15.5±5.4                   | <0.001   |
| Left atrial appendage apical wall strain (%)   | 6.6±2.8                     | 14.7±6.4                   | <0.001   |
| Left atrial appendage medial wall strain (%)   | 7.5±3.4                     | 17.2±6.9                   | <0.001   |
| Left atrial appendage lateral wall strain (%)  | 5.5±2.3                     | 14.6±5.8                   | <0.001   |

AF: Atrial fibrillation; LVEF: Left ventricular ejection fraction; SR: Sinus rhythm; STE: Speckle tracking echocardiography; TIA: Transient ischemic attack; TEE: Transesophageal echocardiography.

There were moderate correlations between the CHA<sub>2</sub>DS<sub>2</sub>-VASc score and LAA emptying velocity ( $r=-0.32$ ;  $p<0.001$ ) and LAA lateral strain ( $r=-0.39$ ;

$p<0.001$ ), as well as weak-moderate correlations with LAA global and medial 2D-strain values ( $r=-0.30$ ;  $p=0.001$  and  $r=-0.24$ ;  $p=0.008$ , respectively) (Fig. 2).



**Figure 2.** LAA medial, apical, lateral, and global 2D strain in different CHA<sub>2</sub>DS<sub>2</sub>-VASc groups (LAA: Left atrial appendage).

### Association of LAA 2D-strain values with the presence of LAA SEC/thrombus

SEC was detected in 84 patients, of whom 45 (54%) had dense SEC. Spearman correlation analysis indicated that the grade of the SEC density was significantly correlated with LAA emptying velocity ( $r=-0.48$ ;  $p<0.001$ ), LAA filling velocity ( $r=-0.484$ ;  $p<0.001$ ), left atrial diameter ( $r=0.22$ ;  $p=0.015$ ), LAA area change ( $r=-0.217$ ;  $p=0.007$ ), LAA medial strain ( $r=-0.33$ ;  $p<0.001$ ), LAA apical strain ( $r=-0.246$ ;  $p=0.005$ ), LAA lateral strain ( $r=-0.34$ ;  $p<0.001$ ), and CHA<sub>2</sub>DS<sub>2</sub>-VASc score ( $r=0.317$ ;  $p<0.001$ ), but did not show significant correlations with left ventricular ejection fraction ( $r=0.09$ ;  $p=0.306$ ) or LAA global strain values ( $r=-0.046$ ;  $p=0.607$ ).

Twenty-seven (60%) of the patients with dense SEC also had an isolated thrombus in the LAA. The clinical and echocardiographic features of the patients with and without dense SEC and/or thrombus are presented in Table 2. In 34 patients, there was a previ-

**Table 2.** Clinical and echocardiographic characteristics of the patients with and without dense SEC/thrombus

|  | Patients with SEC/thrombus<br>(n=45) | Patients without SEC/thrombus<br>(n=81) | <i>p</i> |
|--|--------------------------------------|---|----------|
| <b>Clinical characteristics</b>              |                                      |   |          |
| Age (years)                                  | 60±9                                 | 63±11                                   | 0.176    |
| Gender (female)                              | 27 (60%)                             | 18 (56%)                                | 0.629    |
| Congestive heart failure or LVEF ≤40%        | 5 (11%)                              | 15 (19%)                                | 0.276    |
| Hypertension                                 | 33 (73%)                             | 57 (70%)                                | 0.724    |
| Diabetes mellitus                            | 15 (33%)                             | 24 (30%)                                | 0.667    |
| History of stroke or TIA                     | 22 (49%)                             | 12 (15%)                                | <0.001   |
| Coronary artery disease                      | 13 (29%)                             | 6 (7%)                                  | 0.001    |
| CHA <sub>2</sub> DS <sub>2</sub> -VASc score | 3.4±1.7                              | 2.6±2.0                                 | 0.041    |
| Left atrial diameter (mm)                    | 53±8                                 | 48±7                                    | <0.001   |
| LVEF (%)                                     | 60±16                                | 59±14                                   | 0.694    |
| <b>TEE findings of LAA function</b>          |                                      |   |          |
| LAA area change (%)                          | 28 (10–30)                           | 30 (20–46)                              | 0.001    |
| LAA emptying velocity (cm/s)                 | 21.0 (18.0–26.0)                     | 34.0 (24.0–42.0)                        | <0.001   |
| LAA filling velocity (cm/s)                  | 19.4±8.5                             | 31.9±12.9                               | <0.001   |
| LAA global strain (%)                        | 5.8±2.5                              | 6.8±2.0                                 | 0.015    |
| LAA apical wall strain (%)                   | 6.0±3.3                              | 6.9±2.4                                 | 0.105    |
| LAA medial wall strain (%)                   | 6.5±3.2                              | 8.0±3.4                                 | 0.016    |
| LAA lateral wall strain (%)                  | 4.9±2.4                              | 5.9±2.2                                 | 0.012    |

AF: Atrial fibrillation; BMI: Body mass index; F: Female; LAA: Left atrial appendage; LVEF: Left ventricular ejection fraction; SEC: Spontaneous echo contrast; TEE: Transesophageal echocardiography; TIA: Transient ischemic attack.

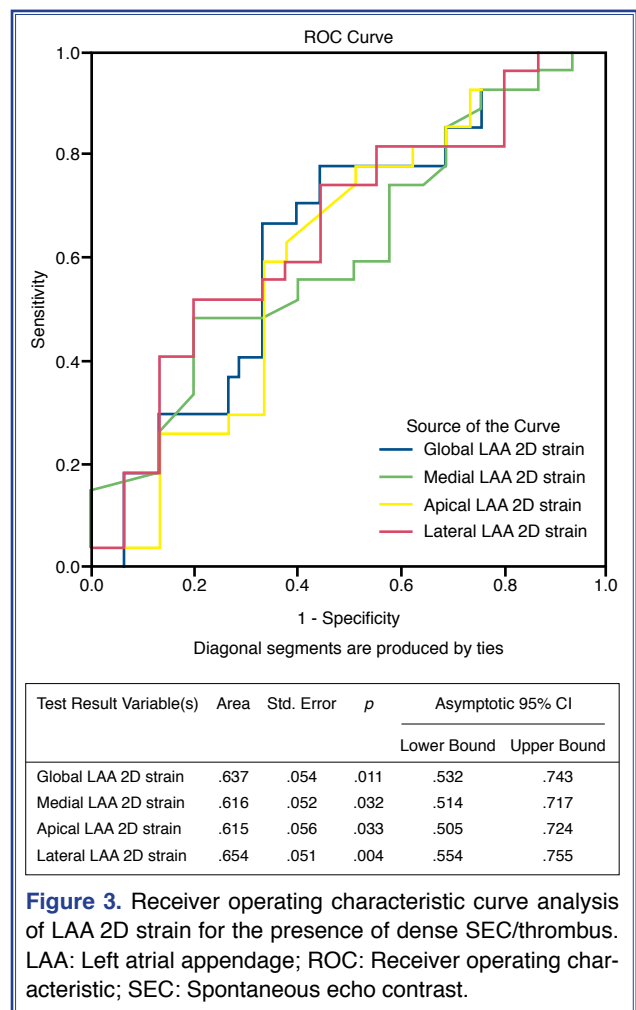
ous history of stroke or transient ischemic attack as diagnosed by computed tomography and/or magnetic resonance imaging. Among them, 22 (65%) had dense SEC/thrombus, which was a significantly higher proportion than that of the group without a history of a cerebrovascular event (65% vs. 25%;  $p < 0.001$ ).

Multivariate logistic regression analysis revealed that among the LAA functional parameters, LAA-emptying velocity and LAA area change were independent associates of the presence of dense SEC and/or thrombus (Exp[B] 0.839, 95% confidence interval [CI] 0.754–0.933,  $p = 0.001$  and Exp[B] 0.953, 95% CI 0.913–0.996,  $p = 0.033$ , respectively). LAA 2D-strain variables did not demonstrate independent associations with the presence of dense SEC/thrombus.

None of the patients with a  $CHA_2DS_2$ -VASc score of 0 had dense SEC/thrombus, but 6 of 21 patients (29%) with a score of 1 had moderate-severe density SEC and 3 also had a thrombus in the LAA. None of the patients with a score of 0 or 1 had a history of a cerebrovascular event. In the subgroup with a  $CHA_2DS_2$ -VASc score of 0 or 1, patients with dense SEC/thrombus had a significantly lower LAA emptying ( $22 \pm 2$  cm/second vs.  $39 \pm 15$  cm/second;  $p < 0.001$ ) and filling velocity ( $13 \pm 2$  cm/second vs.  $31 \pm 11$  cm/second;  $p < 0.001$ ), and a significantly lower LAA medial 2D-strain value ( $6.1 \pm 1.0\%$  vs.  $9.5 \pm 2.6\%$ ;  $p = 0.010$ ) than the patients without dense SEC/thrombus.

A ROC analysis was generated for each LAA 2D-strain variable to identify the cut-off values for determining dense SEC/thrombus in LAA (Fig. 3). The cut-off values for global, medial, apical, and lateral 2D-strain for the presence of dense SEC/thrombus were 6.0% (sensitivity 66%, specificity 67%), 8.0% (sensitivity 48%, specificity 80%), 6.0% (sensitivity 63%, specificity 64%) and 5.4% (sensitivity 56%, specificity 67%), respectively.

To evaluate the possible additive value of depressed regional LAA mechanics, a subgroup of AF patients with mild-moderately depressed LAA function (defined as a LAA emptying velocity of 20–40 cm/second) was selected. Multivariate logistic regression analysis of this subgroup ( $n = 84$ ) showed that medial LAA 2D-strain was the most significant determinant of the presence of dense SEC/thrombus (Exp[B] 0.723, 95% CI for Exp[B] 0.547–0.955;  $p = 0.002$ ) among the LAA functional variables.



**Figure 3.** Receiver operating characteristic curve analysis of LAA 2D strain for the presence of dense SEC/thrombus. LAA: Left atrial appendage; ROC: Receiver operating characteristic; SEC: Spontaneous echo contrast.

## DISCUSSION

The findings of this study demonstrate that STE is a feasible method for the evaluation of regional LAA mechanics in TEE. The 2D-strain values obtained from global and partial views of the LAA were significantly depressed in patients with AF compared with the patients with a sinus rhythm. Reduced global and regional LAA 2D-strain revealed significant associations with flow velocity in the LAA, the  $CHA_2DS_2$ -VASc score, and the presence of dense SEC/thrombus in the LAA. Among them, the greatest correlations with defined events were observed in the medial LAA 2D-strain value, and in AF patients with a mild-moderately depressed LAA emptying flow velocity (20–40 cm/second), concomitant impairment in the medial LAA 2D-strain value was independently correlated with the presence of dense SEC/thrombus.

Numerous studies have proven that poor contractile function and reduced flow velocity in the LAA on TEE examination are strongly correlated with thrombus formation in the LAA cavity.<sup>[14–16]</sup> It has also been demonstrated that the LAA functions of patients with AF rhythm were significantly impaired compared with subjects with a sinus rhythm, predisposing them to increased risk of developing left atrial SEC/thrombus, and hence for thromboembolic events.<sup>[16–18]</sup>

Conventional LAA functional parameters determined by TEE examination provide information on the global changes within the LAA cavity and do not reflect regional wall motion abnormalities. Direct evaluation of regional LAA wall motion is possible using conventional TTE, but requires expertise and may not be reliable due to technical difficulties. Therefore, several studies have investigated the relationship of left atrial global and regional deformation assessed by TTE to LAA functional impairment on TEE.<sup>[19–21]</sup> All of these studies found significant correlations between left atrial strain and LAA function according to TTE, and concluded that TTE left atrial strain assessment can noninvasively predict LAA stasis and the presence of LAA thrombus. However, the left atrium and the LAA may sometimes demonstrate mechanical discord and information obtained through left atrial examination with TTE may not directly reflect LAA functional or wall motion abnormalities.<sup>[16,22]</sup>

TEE is a reliable imaging technique to directly evaluate real-time regional LAA contractility. Active LAA deformation may be assessed using strain analysis either with real-time 2D color Doppler myocardial imaging or 2D speckle tracking methods. Only a few studies have assessed the feasibility of strain imaging of the LAA with TEE, possibly due to the thin wall diameter of this structure. Sevimli et al.<sup>[23]</sup> examined LAA strain using real-time 2D color Doppler myocardial imaging. They analyzed only the lateral wall of the LAA and reported that LAA strain was positively correlated with LAA emptying velocity and was significantly lower in patients with SEC and LAA thrombus. They concluded that color Doppler myocardial strain imaging can be considered a robust technique for the assessment of LAA systolic deformation. Kurzwski et al.<sup>[24]</sup> and Kaya et al.<sup>[25]</sup> used tissue-Doppler imaging for LAA strain evaluation. The first group analyzed the basal segments of the LAA, including the left lateral ridge and the baso-medial

appendage segment, and demonstrated significantly reduced deformation in AF patients compared with patients with a sinus rhythm and in those with an LAA thrombus. Kaya et al. analyzed the proximal third of the septal and the mid-lateral walls of the LAA and found a reduction and subsequent recovery after cardioversion.

Compared to tissue Doppler imaging, STE is a more advantageous method to evaluate global and regional myocardial deformations because of its angle-independency, high reproducibility, accuracy, and lack of a fixed angle of insonation. In this study, we took advantage of the similarity of the LAA imaged in a mid-esophageal 2-chamber view to the apical 2-chamber left ventricle image. This allowed us to apply the STE program, which was designed for the left ventricle, to the LAA. As we had excluded patients with complex LAA morphologies, the technique could be successfully used for almost all patients with sufficient 2D grayscale image quality, despite the thinness of the LAA walls. Nevertheless, in AF patients, severe reduction in LAA wall thickness and the small amount of deformation owing to fibrillatory motion made the application of STE relatively difficult and required repeated analysis. Another drawback in AF patients was the limited feasibility of STE due to increased heart rate.

Our findings on LAA deformation indices were similar to those of previous studies, confirming significantly reduced global and regional 2D-strain in AF patients compared with patients with a sinus rhythm, and a significant reduction in AF patients with dense SEC/thrombus in the LAA compared with those without these findings. A novel finding of the study was the observation of a relatively stronger association between medial LAA 2D-strain and reduced flow velocity as well as the presence of dense SEC/thrombus in the LAA compared with the apical and lateral regions of the LAA. Particularly in patients with mild-moderately impaired LAA flow velocities, reduced medial LAA strain values were the most significant independent correlate with dense SEC/thrombus. A normal LAA emptying flow rate is 20–40 cm/second. Velocities <40 cm/second are associated with a greater risk of stroke and the presence of SEC, and even more depressed flow velocities of <20 cm/second are associated with a greater incidence of thromboembolic events and thrombus formation within the



LAA.<sup>[26]</sup> In this study, none of the AF patients with an LAA emptying velocity of  $>40$  cm/second had dense SEC/thrombus, but 30 (36%) of the 84 patients with a mild-moderately depressed LAA emptying velocity and 15 (71%) of the 21 patients with a severe flow velocity reduction ( $<20$  cm/second) were observed to have SEC/thrombus in the LAA. The value of concomitant mitral LAA 2D-strain depression, particularly in patients with mild-moderately depressed LAA emptying velocities, in predicting future thromboembolic events was not evaluated in this study.

These findings suggest that the medial LAA wall shows greater deformation than the other 2 segments and contributes more to LAA function. The importance of medial LAA wall motion has also been observed in previous studies. Topsakal et al.<sup>[27]</sup> evaluated patients with acute myocardial infarction by assessing LAA function using color Doppler tissue imaging on TEE and observed significant decreases in the mid LAA medial wall and LAA emptying velocity in patients with SEC and/or thrombus in the LAA. Contrary to those findings, Sallach et al.<sup>[28]</sup> observed more marked motion decreases in the apical and lateral LAA regions in patients with AF and SEC/thrombus formation. Theirs was a multicenter study consisting of 118 patients with paroxysmal, persistent, and permanent AF. Regional LAA function was assessed mainly using tissue-Doppler imaging from a TTE parasternal short-axis view at the level of the aortic valve and the apical 2-chamber or apical 4-chamber views. There were significant differences between tissue-Doppler imaging velocities measured using TTE and TEE examinations. Therefore, a direct comparison between our findings and theirs cannot be made.

The CHA<sub>2</sub>DS<sub>2</sub>-VASc score is the most commonly used scoring system to determine a need for anticoagulant therapy. Especially in patients with a CHA<sub>2</sub>DS<sub>2</sub>-VASc score of 1, additional parameters may be useful for more reliable thromboembolic risk prediction. Several attempts have been made to integrate echocardiographic findings into the CHA<sub>2</sub>DS<sub>2</sub>-VASc score, but no echocardiographic parameters have been included in the score thus far. STE of left atrium as an indirect marker of impaired LAA function seems to be a promising parameter for further risk assessment.<sup>[29]</sup> In our study, none of the patients with a CHA<sub>2</sub>DS<sub>2</sub>-VASc score of 0 had dense SEC/thrombus. In patients with a CHA<sub>2</sub>DS<sub>2</sub>-VASc score of 1, reduced medial

LAA strain appeared to be significantly associated with dense SEC/thrombus in the LAA; however, due to the small number of patients, a clear conclusion cannot be drawn from this finding.

### Study limitations

The LAA has a complex 3D anatomy that limits precise evaluation using standard TEE imaging planes. This study examined the LAA using images obtained from a single window and assessed the longitudinal strain findings. Confirmation of the findings with a 3D imaging technique would be appropriate.

The relatively low frame rate of STE limits usage in patients with AF and tachycardia. In this study, a frame rate higher than the recommended the 40 to 80 frames/second recommended by the ASE/EAE was used: 60 to 90 frames/second. Nevertheless, it is possible that there were measurement inaccuracies.

Due to the cross-sectional nature of the study, we were not able to accurately determine the value of assessing global and regional LAA mechanics for the prediction of future thromboembolic events.

### Conclusion

STE evaluation of LAA function from 2D grayscale images obtained during TEE is technically feasible and provides accurate data on global and regional LAA function in AF patients. Although its usage in daily practice is limited, it may be valuable as a complementary technique to conventional LAA flow velocity measurements in patients with mild-moderately depressed LAA flow velocities and in patients with a CHA<sub>2</sub>DS<sub>2</sub>-VASc score of 1.

**Ethics Committee Approval:** The study was approved by the Ethics Committee of Kocaeli University (approval date: 29.05.2012 approval no.: 2012/34).

**Peer-review:** Externally peer-reviewed.

**Conflict-of-interest:** None.

**Authorship contributions:** Concept: E.S., D.U.; Design: D.U.; Supervision: D.U.; Materials: E.S., T.Ş., E.V.; Data: E.S., S.K.; Analysis: D.U., S.K., E.S.; Literature search: E.S., E.V.; Writing: E.S., D.U.; Critical revision: D.U., E.V.

### REFERENCES

1. Hara H, Virmani R, Holmes DR Jr, Buchbinder M, Lesser JR,

- Van Tassel RA, et al. Is the left atrial appendage more than a simple appendage? *Catheter Cardiovasc Interv* 2009;74:234–42.
2. Parvathaneni L, Mahenthiran J, Jacob S, Foltz J, Gill WJ, Ghumman W et al. Comparison of tissue Doppler dynamics to Doppler flow in evaluating left atrial appendage function by transesophageal echocardiography. *Am J Cardiol* 2005;95:1011–4. [[CrossRef](#)]
  3. Tan C, Ou Yang M, Kong D, Zhou X. Association between the left atrial and left atrial appendages systole strain rate in patients with atrial fibrillation. *Med Sci Monit* 2016;22:4974–7.
  4. Providência R, Faustino A, Ferreira MJ, Gonçalves L, Trigo J, Botelho A, et al. Evaluation of left atrial deformation to predict left atrial stasis in patients with non-valvular atrial fibrillation - a pilot-study. *Cardiovasc Ultrasound* 2013;11:44.
  5. Blessberger H, Binder T. Non-invasive imaging: Two dimensional speckle tracking echocardiography: basic principles. *Heart* 2010;96:716–22. [[CrossRef](#)]
  6. Ancona R, Comenale Pinto S, Caso P, D'Andrea A, Di Salvo G, Arenga F, et al. Left atrium by echocardiography in clinical Practice: From conventional methods to new echocardiographic techniques. *ScientificWorldJournal* 2014;2014:451042. [[CrossRef](#)]
  7. Mor-Avi V, Lang RM, Badano LP, Belohlavek M, Cardim NM, Derumeaux G, et al. Current and evolving echocardiographic techniques for the quantitative evaluation of cardiac mechanics: ASE/EAE consensus statement on methodology and indications endorsed by the Japanese Society of Echocardiography. *J Am Soc Echocardiogr* 2011;24:277–313.
  8. January CT, Wann LS, Alpert JS, Calkins H, Cigarroa JE, Cleveland JC Jr, et al; American College of Cardiology/American Heart Association Task Force on Practice Guidelines. 2014 AHA/ACC/HRS guideline for the management of patients with atrial fibrillation: a report of the American College of Cardiology/American Heart Association Task Force on Practice Guidelines and the Heart Rhythm Society. *J Am Coll Cardiol* 2014;64:e1–76. [[CrossRef](#)]
  9. Kirchhof P, Benussi S, Kotecha D, Ahlsson A, Atar D, Casadei B, et al; ESC Scientific Document Group. 2016 ESC Guidelines for the management of atrial fibrillation developed in collaboration with EACTS. *Eur Heart J* 2016;37:2893–962.
  10. Zhao Y, Zhang PP, Xu QF, Yu LW, Yu Y, Li YG. Relationship between left atrial appendage morphology and thrombus formation in patients with atrial fibrillation. *Int J Cardiol* 2015;188:86–8. [[CrossRef](#)]
  11. Yarmohammadi H, Klosterman T, Grewal G, Alraies MC, Varr BC, Lindsay B, et al. Efficacy of the CHADS2 scoring system to assess left atrial thrombogenic milieu risk before cardioversion of non-valvular atrial fibrillation. *Am J Cardiol* 2013;112:678–83. [[CrossRef](#)]
  12. Willens HJ, Gómez-Marín O, Nelson K, DeNicco A, Moscucci M. Correlation of CHADS2 and CHA2DS2-VASc scores with transesophageal echocardiography risk factors for thromboembolism in a multiethnic United States population with nonvalvular atrial fibrillation. *J Am Soc Echocardiogr* 2013;26:175–84. [[CrossRef](#)]
  13. Lang RM, Badano LP, Mor-Avi V, Afilalo J, Armstrong A, Ernande L, et al. Recommendations for cardiac chamber quantification by echocardiography in adults: an update from the American Society of Echocardiography and the European Association of Cardiovascular Imaging. *Eur Heart J Cardiovasc Imaging* 2015;16:233–70. [[CrossRef](#)]
  14. Kamp O, Verhorst PM, Welling RC, Visser CA. Importance of left atrial appendage flow as a predictor of thromboembolic events in patients with atrial fibrillation. *Eur Heart J* 1999;20:979–85. [[CrossRef](#)]
  15. Ozer N, Tokgözoğlu L, Ovünç K, Kabakçi G, Aksöyek S, Aytemir K, et al. Left atrial appendage function in patients with cardioembolic stroke in sinus rhythm and atrial fibrillation. *J Am Soc Echocardiogr* 2000;13:661–5. [[CrossRef](#)]
  16. Patti G, Pengo V, Marcucci R, Cirillo P, Renda G, Santilli F, et al; Working Group of Thrombosis of the Italian Society of Cardiology. The left atrial appendage: from embryology to prevention of thromboembolism. *Eur Heart J* 2017;38:877–87.
  17. Fukushima K, Fukushima N, Kato K, Ejima K, Sato H, Fukushima K, et al. Correlation between left atrial appendage morphology and flow velocity in patients with paroxysmal atrial fibrillation. *Eur Heart J Cardiovasc Imaging* 2016;17:59–66.
  18. Handke M, Harloff A, Hetzel A, Olschewski M, Bode C, Geibel A. Left atrial appendage flow velocity as a quantitative surrogate parameter for thromboembolic risk: determinants and relationship to spontaneous echocontrast and thrombus formation—a transesophageal echocardiographic study in 500 patients with cerebral ischemia. *J Am Soc Echocardiogr* 2005;18:1366–72. [[CrossRef](#)]
  19. Costa C, González-Alujas T, Valente F, Aranda C, Rodríguez-Palomares J, Gutierrez L, et al. Left atrial strain: a new predictor of thrombotic risk and successful electrical cardioversion. *Echo Res Pract* 2016;3:45–52. [[CrossRef](#)]
  20. Karabay CY, Zehir R, Güler A, Oduncu V, Kalayci A, Aung SM, et al. Left atrial deformation parameters predict left atrial appendage function and thrombus in patients in sinus rhythm with suspected cardioembolic stroke: a speckle tracking and transesophageal echocardiography study. *Echocardiography* 2013;30:572–81. [[CrossRef](#)]
  21. Leong DP, Penhall A, Perry R, Shirazi M, Altman M, Chong D, et al. Speckle-tracking strain of the left atrium: a transoesophageal echocardiographic validation study. *Eur Heart J Cardiovasc Imaging* 2013;14:898–905. [[CrossRef](#)]
  22. Warraich HJ, Gandhavadi M, Manning WJ. Mechanical discordance of the left atrium and appendage: a novel mechanism of stroke in paroxysmal atrial fibrillation. *Stroke* 2014;45:1481–4. [[CrossRef](#)]
  23. Sevimli S, Gundogdu F, Arslan S, Aksakal E, Gurlertop HY,

- Islamoglu Y, et al. Strain and strain rate imaging in evaluating left atrial appendage function by transesophageal echocardiography. *Echocardiography* 2007;24:823–9. [CrossRef]
24. Kurzawski J, Janion-Sadowska A, Sadowski M. Left atrial appendage function assessment and thrombus identification. *Int J Cardiol Heart Vasc* 2016;14:33–40.
25. Kaya EB, Tokgözoğlu L, Aytemir K, Kocabas U, Tülümen E, Deveci OS, et al. Atrial myocardial deformation properties are temporarily reduced after cardioversion for atrial fibrillation and correlate well with left atrial appendage function. *Eur J Echocardiogr* 2008;9:472–7.
26. Li YH, Lai LP, Shyu KG, Hwang JJ, Kuan P, Lien WP. Clinical implications of left atrial appendage flow patterns in non-rheumatic atrial fibrillation. *Chest* 1994;105:748–52.
27. Topsakal R, Eryol NK, Çiçek Y, Sağlam H, Seyfeli E, Abacı A, et al. Evaluation of left atrial appendage functions in patients with thrombus and spontaneous echo contrast in left atrial appendage by using color Doppler tissue imaging. *Ann Noninvasive Electrocardiol* 2004;9:345–51. [CrossRef]
28. Sallach JA, Puwanant S, Drinko JK, Jaffer S, Donal E, Thambidorai SK, et al. Comprehensive left atrial appendage optimization of thrombus using surface echocardiography: the CLOTS multicenter pilot trial. *J Am Soc Echocardiogr* 2009;22:1165–72. [CrossRef]
29. Saha SK, Kiotseoglou A. Value of speckle tracking echocardiography for prediction of stroke risk in atrial fibrillation: Time to spare a stare outside the box? *Echocardiography* 2018;35:589–91. [CrossRef]

---

**Keywords:** CHA<sub>2</sub>DS<sub>2</sub>-VASc score; left atrial appendage; speckle-tracking echocardiography; thromboemboli.

**Anahtar sözcükler:** CHA<sub>2</sub>DS<sub>2</sub>-VASc skoru; sol atriyal apendiks; speckle tracking ekokardiyografi; tromboemboli.