

Management of a subclavian artery thrombosis causing acute anterior wall infarction and concurrent left arm ischemia in a patient with prior coronary bypass

Koroner baypaslı hastada, akut ön yüz kalp krizi ve sol kol iskemisine yol açan subklavya atardamarı pıhtısının tedavisi

Çağdaş Akgüllü, M.D., Ufuk Eryılmaz, M.D., Cemil Zencir, M.D., Hasan Güngör, M.D.

Department of Cardiology, Adnan Menderes University Faculty of Medicine, Aydın

Summary– We report a 57-year-old patient with acute anterior wall infarction with a history of a coronary bypass graft operation in 2007. He also had concurrent left arm cyanosis and severe pain. He had received diagnosis of pancreatic adenocarcinoma one month previously and had had his first chemotherapy in the previous week with gemcitabine and 5-fluorouracil. After the angiography, a giant thrombus was detected in the proximal left subclavian artery, deteriorating the flows of both left internal mammary artery (LIMA) to left anterior descending (LAD) coronary artery graft, as well as the left brachial artery. The proximal subclavian artery was stented and good flow was achieved. Through the LIMA, the distal part of LAD, which was totally obstructed with probable distal thrombus embolization, was reached and a percutaneous balloon angioplasty performed. However, the no-reflow phenomenon was observed in distal LAD. A Fogarty traction of thrombus was performed successfully for the revascularization of the left arm. Approximately 30 minutes after the procedure, both angina and ST segment elevation in ECG were resolved under unfractionated heparin and nitroglycerin infusion. However, the patient died due to sepsis seven days after admission to hospital. In the literature, there are only a few previous reports on this rare clinical entity. The etiology, presentation, and the possible management strategies of this clinical entity is presented in this report.

Subclavian steal syndrome (SSS) is characterized by stenosis of the proximal subclavian artery (SA). This causes reversal of vertebral and left internal mammary artery (LIMA) blood flows, which leads to dizziness and angina pectoris after coronary bypass grafting. SSS classically causes stable angina

Özet– 2007 yılında koroner arter baypas operasyonu öyküsü olan ve akut ön yüz kalp krizi geçiren 57 yaşında bir hasta sunuyoruz. Hastanın aynı zamanda eşlik eden ciddi sol kol ağrısı ve siyanozu da bulunmaktaydı. Bir ay önce pankreastan kaynaklanan adenokarsinom tanısı konan hastaya, bir hafta önce gemcitabin ve 5-fluorourasil içeren kemoterapinin ilk kürü uygulanmıştı. Anjiyografide sol subklavya atardamarı başlangıcında yer alan ve sol iç meme atardamarı- sol ön inen koroner arter baypas greftinin ve sol kol atardamarının akımını engelleyen dev bir pıhtı parçası görüntülendi. Sol subklavya arterinin başlangıç kısmına stent yerleştirilerek iyi bir akım sağlandı. Sol iç meme atardamarı aracılığıyla, ötesi olası pıhtı göçü ile tıkanmış sol ön inen koroner atardamara ulaşıldı ve perkütan anjiyoplasti yapıldı, ne var ki “no reflow” fenomeni izlendi. Sol koldaki pıhtı parçası Fogarty kateteri ile başarılı bir şekilde uzaklaştırıldı. İşlemden yaklaşık yarım saat sonra, sürekli fraksiyone olmayan heparin ve nitrogliserin infüzyonu altında hastanın hem göğüs ağrısı, hem de EKG’deki ST segment yükselmeleri geriledi. Ancak hasta, yatışının yedinci gününde sepsis nedeniyle hayatını kaybetti. Bu klinik olay ile ilgili literatürde ancak birkaç sunu mevcuttur. Bu sunuda, bu klinik olayın etiyojisi, başvuru şekli ve olası yönetim stratejileri sunulmaktadır.

pectoris, with related acute coronary syndromes being extremely rare. However, SSS due to thrombosis is a novel entity that may cause myocardial infarctions. In the literature, there are only a few cases described with acute coronary syndromes related to subclavian artery occlusions.^[1-3]

Received: May 12, 2014 Accepted: August 07, 2014

Correspondence: Dr. Çağdaş Akgüllü. Adnan Menderes Üniversitesi Üniversitesi Tıp Fakültesi, Kardiyoloji Anabilimdalı, Aytepe Mevkii, Aydın.

Tel: +90 256 - 444 12 56 / 2215 e-mail: cagdasakgullu@gmail.com

© 2014 Turkish Society of Cardiology



Here we report a 57-year-old male patient with acute anterior wall infarction and severe left arm ischemia secondary to proximal subclavian artery thrombosis.

CASE REPORT

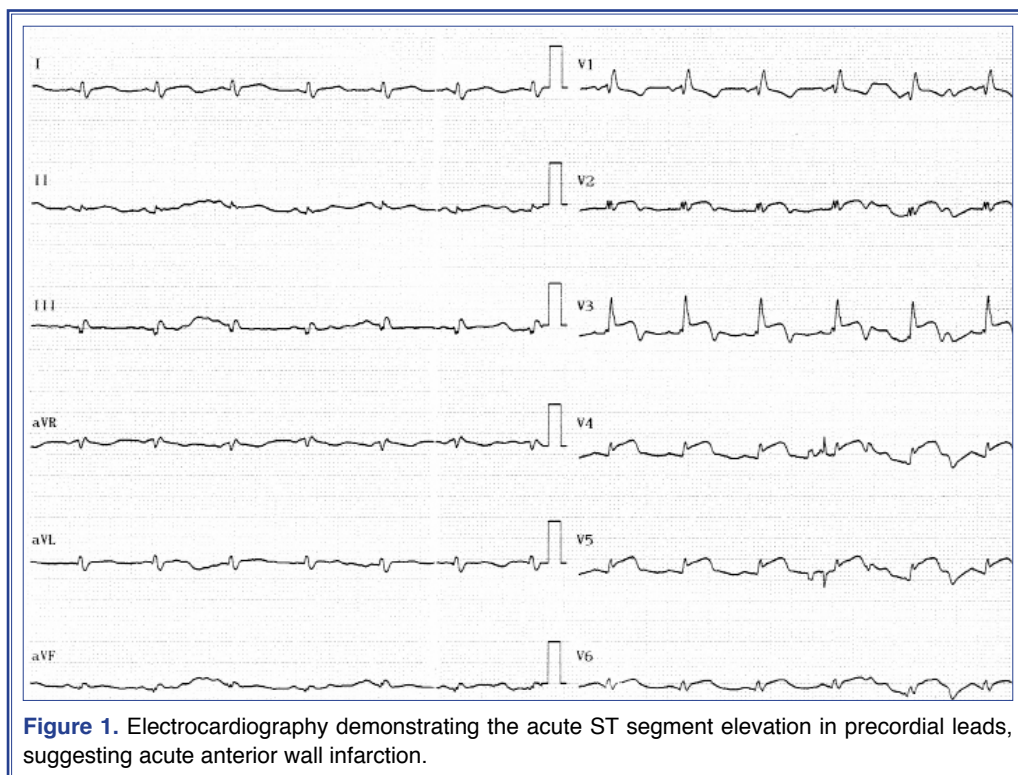
A 57-year-old man with a history of hypertension underwent coronary artery bypass grafting in 2007. A LIMA graft was anastomosed to the left anterior descending coronary artery (LAD), while one vein graft was anastomosed to the obtuse marginal branch of the left circumflex coronary artery. One month previous to presenting to the emergency room this time, he had been diagnosed with pancreatic adenocarcinoma and had had his first dose of chemotherapy (gemcitabine and 5-fluorouracil) one week previously. This time, the patient presented to the emergency room with general dizziness, ongoing severe angina pectoris and left arm cyanosis and pain. Blood pressure was not measurable, and the left radial and brachial pulses were not detectable in the left upper limb. On the right side, the blood pressure was 100/60 mmHg with a regular pulse of 90 beats per minute. The electro-cardiogram revealed a sinus rhythm and ST segment elevations in the precordial leads between V2-6 (Figure 1).

An emergent angiography was performed, which disclosed patent vein graft and no sign of acute thrombosis in native coronary arteries (Video 1*). However,

a huge thrombus in the proximal left subclavian artery, distinct from the orifices of the vertebral and left internal mammary arteries, rendered severe obstruction of the left subclavian artery and restricted the perfusion of distal tissues, including the anterior wall of the myocardium through the LIMA (Figure 2a) (Video 2a*). Moreover, the left brachial artery (Video 2b*) and distal part of the LAD flows were absent (Video 2a*), probably due to distal embolisation. An echocardiogram showed no intracardiac thrombus or mass, but showed hypokinesis in the anterior septum and mid- and apical anterior walls of the left ventricle. There was no sign of valvular disease. Laboratory work up showed severe thrombocytopenia (25.000 per microlitre of blood). The patient was consulted to a cardiovascular surgeon. The options of operation or thrombolytic therapy were thought to be risky because of thrombocytopenia. Intravenous (i.v.)

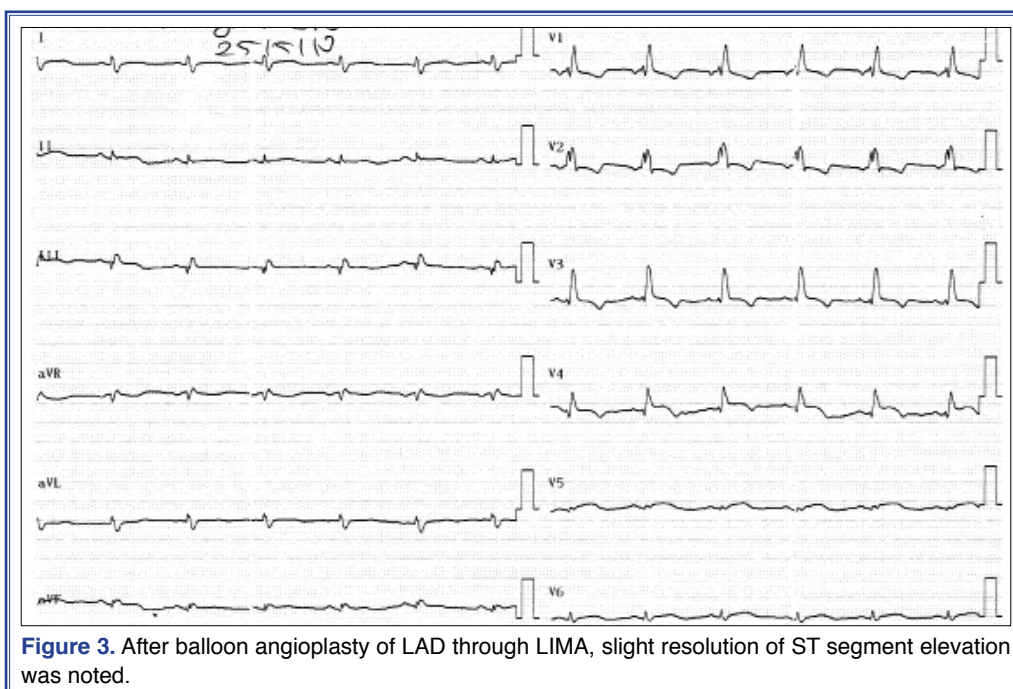
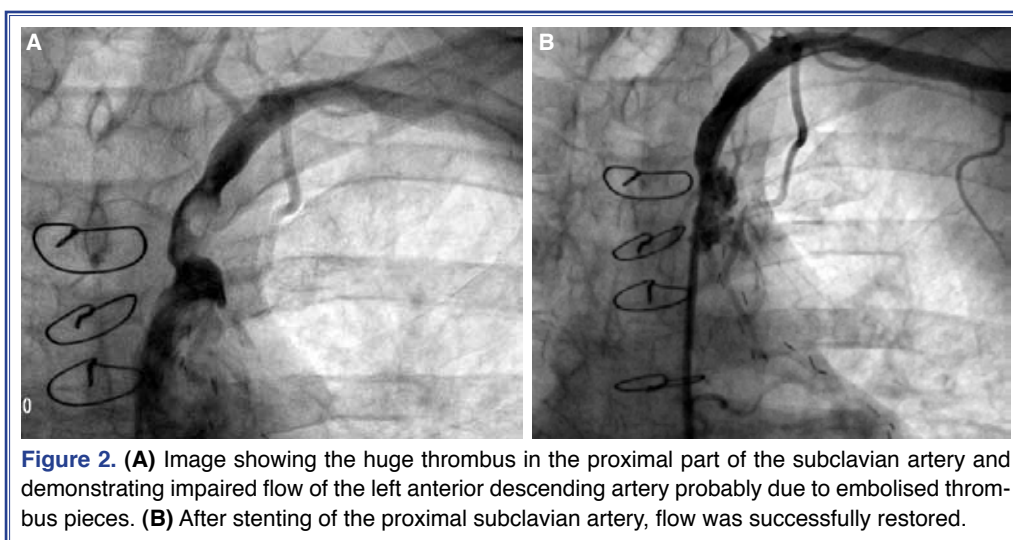
Abbreviations:

CABG	Coronary artery bypass surgery
LAD	Left anterior descending
LIMA	Left internal mammary artery
SA	Subclavian artery
SSS	Subclavian steal syndrome
UFH	Unfractionated heparin



bolus of 70 U/kg unfractionated heparin (UFH) was administered during the procedure, and using a hybrid approach, the patient underwent successful stenting of the proximal subclavian artery, and then extraction of the left brachial thrombus with a Fogarty catheter. The stenting procedure of the subclavian artery restored the flow (8.5x25 mm self-expandable stent) (Figure 2b) (Video 3a*), and then the LIMA was cannulated and balloon dilatation (2x12 mm balloon) of the distal part of the LAD was performed (Video 3b*). However, no-reflow phenomenon was observed in the distal

part of the LAD (Video 3c*). After the hybrid process, left brachial and radial pulses were restored and the cyanosis disappeared. Following the procedure, continuous i.v. nitroglycerin (5 mcg/min) and UFH infusions was administered to achieve and maintain therapeutic activated clotting time (ACT) between 250 and 300 seconds. Approximately 30 minutes after the procedure, during follow-up in the intensive care unit, angina was found to have been relieved and the resolution of ST segment elevation was remarkable in the control ECG (Figure 3). The patient did not ex-



perience any bleeding. However, on the second day he was oliguric and the laboratory workup suggested an acute deterioration of renal function, with a serum creatinine level of 2.4 mg/dL. Dialysis was begun, but unfortunately he was lost due to renal failure and sepsis seven days following admission to our hospital.

DISCUSSION

Subclavian artery thrombosis may develop because of infections, rheumatic disorders, radiation therapy, chronic extra arterial compressions, expanding aortic dissections, trauma, concomitant diseases like malignancies or hematological disturbances, situations and/or diseases that may lead to hypercoagulopathy and disseminate intravascular coagulation.^[4-8] Rarely, it may develop on the site – such as the cervical rib - of local stenosis that occurs secondary to atherosclerosis or congenital pathologies.^[9] The clinical presentation varies widely, from asymptomatic to severe pain in the upper extremity and dizziness. In patients with prior coronary artery bypass surgery (CABG), accompanying angina pectoris, and even myocardial infarction, may occur if the left subclavian artery thrombosis develops proximal to a LIMA graft.^[2]

In patients with prior CABG and LIMA graft, acute myocardial infarction and concurrent left arm ischemia should suggest a disease involving the aortic arch and/or left subclavian artery. In our case, one of our probable initial-diagnoses was ascending aortic dissection, possibly involving the left SA and brachial artery, and giving rise to the same clinical setting. Thus, first we performed an aortography, but did not see any sign of dissection. After selective cannulation of the SA, the thrombosis was revealed. There are different treatment choices that should be adopted depending on circumstances. Percutaneous stent implantation is a good choice for appropriate patients.^[10] For total occlusions, if the clinic is acute, thrombolytic therapy may be preferred as an alternative approach for the surgical thrombectomy. In selected cases, extrathoracic surgical revascularization with a bypass yields high success.^[11] In our particular patient with severe thrombocytopenia, we discussed these possible treatment strategies and decided to undertake a hybrid approach with the surgeon. A successful stenting for the thrombotic occlusion of the subclavian artery and an angioplasty of the distal LAD were performed. After the procedure, a thrombectomy of

the left brachial artery with a Fogarty catheter was performed by the surgeons. The acute results of both procedures were satisfying, with the no-reflow phenomenon in distal LAD, which was observed just after the balloon angioplasty, probably resolved under nitroglycerin and UFH therapy. The patient's angina was relieved, and ST segment elevations in precordial leads resolved approximately 30 minutes after the procedure. The concomitant effect of reperfusion of the left subclavian artery, i.v. nitroglycerin and heparin infusion, and percutaneous coronary angioplasty might have contributed to the progressive reperfusion of the LAD.

However, during follow-up, the patient was lost due to sepsis and acute renal failure. The cause of the thrombotic subclavian obstruction may be related to malignancy in our patient, but the exact reason remains unknown.

In conclusion, subclavian artery disorders like acute thrombosis should be kept in mind for patients with prior LIMA to coronary bypass grafting. If symptomatic thrombosis in the SA is detected, treatment strategy should be individualized.

Conflict-of-interest issues regarding the authorship or article: None declared.

***Supplementary video file associated with this article can be found in the online version of the journal.**

REFERENCES

1. Munk PS, Larsen AI, Fjetland L, Nilsen DW. Acute occlusion of the left subclavian artery causing a non-ST-elevation myocardial infarction with subacute lung edema due to a coronary subclavian steal syndrome--a case report. *Int J Cardiol* 2006;108:139-41. [CrossRef](#)
2. Wu CH, Sung SH, Chang JC, Huang CH, Lu TM. Subclavian artery thrombosis associated with acute ST-segment elevation myocardial infarction. *Ann Thorac Surg* 2009;88:2036-8. [CrossRef](#)
3. Barlis P, Brooks M, Hare DL, Chan RK. Subclavian artery occlusion causing acute myocardial infarction in a patient with a left internal mammary artery graft. *Catheter Cardiovasc Interv* 2006;68:326-31. [CrossRef](#)
4. Colomba C, Siracusa L, Rubino R, Trizzino M, Scarlata F, Imburgia C, et al. A case of Brucella endocarditis in association with subclavian artery thrombosis. *Case Rep Infect Dis* 2012;2012:581489.
5. Wisneski AD, Beyer AT, Shunk KA. An unusual case of bilateral subclavian-carotid artery graft occlusion with coronary steal syndrome managed in the cath lab. *J Invasive Cardiol* 2013;25:E14-6.

6. Hay E, Cohen H, Pasik S. Acute thrombosis of subclavian artery during CPR. *Ann Emerg Med* 1987;16:447-51. [CrossRef](#)
7. Halpin DP, Moran KT, Jewell ER. Arm ischemia secondary to giant cell arteritis. *Ann Vasc Surg* 1988;2:381-4. [CrossRef](#)
8. Hashmonai M, Elami A, Kuten A, Lichtig C, Torem S. Subclavian artery occlusion after radiotherapy for carcinoma of the breast. *Cancer* 1988;61:2015-8. [CrossRef](#)
9. Santra G, Banerjee S, De D, Bhattacharya K. Right subclavian artery thrombosis due to cervical rib. *J Assoc Physicians India* 2012;60:51.
10. Angle JF, Matsumoto AH, McGraw JK, Spinosa DJ, Hagspiel KD, Leung DA, et al. Percutaneous angioplasty and stenting of left subclavian artery stenosis in patients with left inter-nal mammary-coronary bypass grafts: clinical experience and long-term follow-up. *Vasc Endovascular Surg* 2003;37:89-97.
11. Salam TA, Lumsden AB, Smith RB 3rd. Subclavian artery revascularization: a decade of experience with extrathoracic bypass procedures. *J Surg Res* 1994;56:387-92. [CrossRef](#)

Key words: Acute anterior wall infarction; acute arm ischemia; coronary artery by-pass graft; pancreatic adenocarcinoma; subclavian artery thrombosis.

Anahtar sözcükler: Akut ön duvar kalp krizi; akut kol iskemisi; koroner arter baypas grefti; pankreas adenokarsinomu; subklavya atardamarı trombozu.