

Percutaneous treatment of superior vena cava syndrome caused by chronic thrombosis

Kronik tromboz sonucu oluşan süperiyör vena kava sendromunun perkütan tedavisi

Müslüm Şahin, M.D., Süleyman Aktürk, M.D.,# Mustafa Bulut, M.D., Cevat Kıрма, M.D.

Department of Cardiology, Kartal Kosuyolu Training and Research Hospital, Istanbul;

#Department of Cardiology, Gebze Yuzyıl Hospital, Istanbul

Summary– Chronic upper extremity deep vein thrombosis (UEDVT) and superior vena cava syndrome (SVCS) are becoming increasingly common due to the use of indwelling catheters and implantable central venous access devices. Hypercoagulable syndromes, malignancy, extrinsic compression, and tumor invasion are other causes. Endovascular management of chronic UEDVT and SVCS is accepted as an important first-line treatment given its high overall success rate and low morbidity as compared with medical and surgical treatments. In this case, we present successful management with stenting of superior vena cava obstruction syndrome as a result of chronic thrombosis. A 48-year-old woman was diagnosed with SVCS one year ago. Despite the use of warfarin therapy, her symptoms (swelling of the face and both upper extremities) progressively increased. It was thus decided to treat the patient with percutaneous angioplasty and stenting. Details of the occlusion were evaluated with computed tomography and venography. The right femoral vein and right jugular vein were used for the intervention. The occlusion was passed with a Miracle 12-g guidewire. After balloon pre-dilatation, two self-expandable stents were implanted. After stent placement, her clinical symptoms improved and she was discharged without complication.

Özet– Kronik üst ekstremitte derin ven trombozu (ÜEDVT) ve süperiyör vena kava sendromu (SVKS) kalıcı kateterler ve implante edilebilir santral venöz erişim cihazlarının kullanımı nedeniyle giderek daha sık görülmektedir. Hiperkoagülabilité sendromları, kanser, dıřsal bası ve tümör yayılımı diđer nedenlerdir. Kronik ÜEDVT'nin ve SVKS'nin endovasküler yöntem ile tedavisi başarı oranının yüksekliđi ve düşük morbiditesi nedeniyle, tıbbi ve cerrahi tedavi ile karşılaştırıldıđında önemli bir ilk basamak tedavi olarak kabul edilmektedir. Bu yazıda, kronik tromboz sonucunda oluşan süperiyör vena kava obstrüksiyon sendromunun stent ile başarılı şekilde tedavi edildiđi bir olgu sunuldu. Bir yıl önce SVKS tanısı konulan 48 yařındaki kadın hastanın varfarin tedavisi almasına rađmen semptomları (yüz ve her iki üst ekstremitte şiřme) giderek arttı. Bu nedenle hastanın perkütan anjiyoplasti ve stent ile tedavi edilmesine karar verildi. Vena kava tıkanmasının ayrıntıları bilgisayarlı tomografi ve venografi ile deđerlendirildi. Giriřim için femoral ven ve sađ juguler ven kullanıldı. Tıkalı damar Miracle 12 g kılavuz tel ile geçildi. Balon ile öndilatasyon sonrası iki adet kendiliđinden genişleyebilen stent yerleřtirildi. Stent yerleřtirdikten sonra klinik semptomlar düzeldi ve hasta sorunsuz olarak taburcu edildi.

Superior vena cava syndrome (SVCS) is defined as the stenosis or occlusion of the superior vena cava (SVC) leading to obstruction of the venous outflow of the head and upper extremities. Upper extremity deep vein thrombosis (UEDVT) and SVCS are rare, but in recent years, they have been found to be considerably more prevalent than previously believed.

[1] Anticoagulation is the first step in the treatment of

asymptomatic patients. However, some patients may develop significant symptoms despite warfarin, and intervention is required.^[2] Endovascular

management of chronic UEDVT and SVCS is accepted as an important treatment strategy because of

Abbreviations:

CT	Computed tomography
SVC	Superior vena cava
SVCS	Superior vena cava syndrome
UEDVT	Upper extremity deep vein thrombosis

Received: May 26, 2013 Accepted: July 17, 2013

Correspondence: Dr. Müslüm Şahin. Kartal Koşuyolu Yüksek İhtisas Eğitim ve Araştırma Hastanesi, Kardiyoloji Kliniđi, Kartal, İstanbul.

Tel: +90 216 - 459 44 40 e-mail: sahinm78@yahoo.com

© 2014 Turkish Society of Cardiology



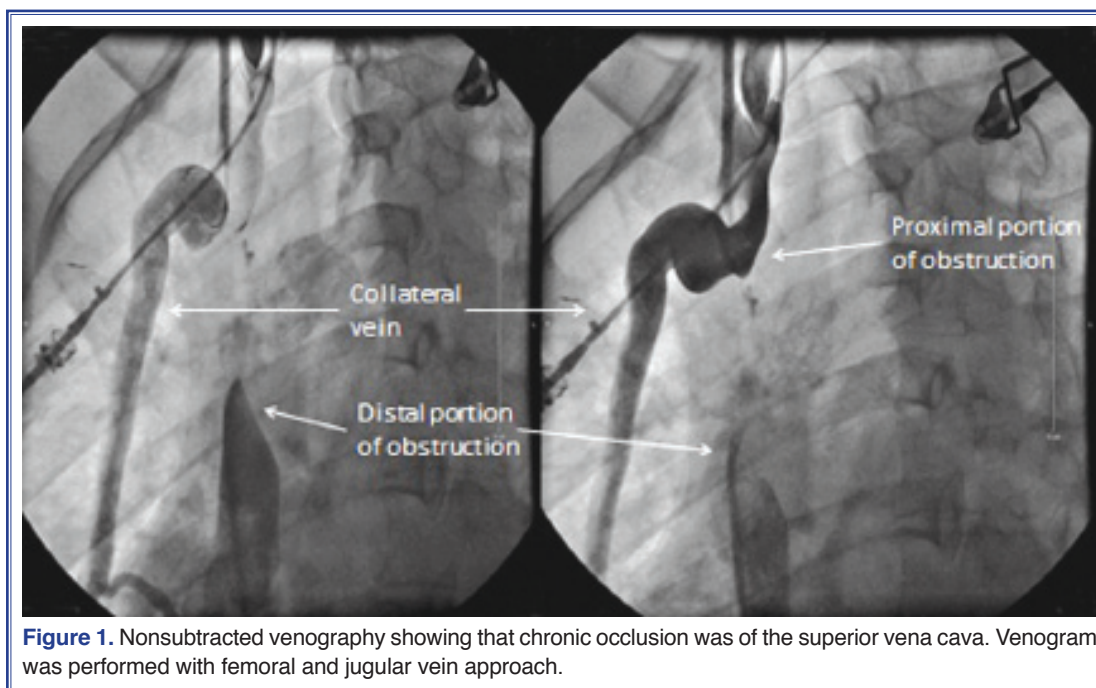


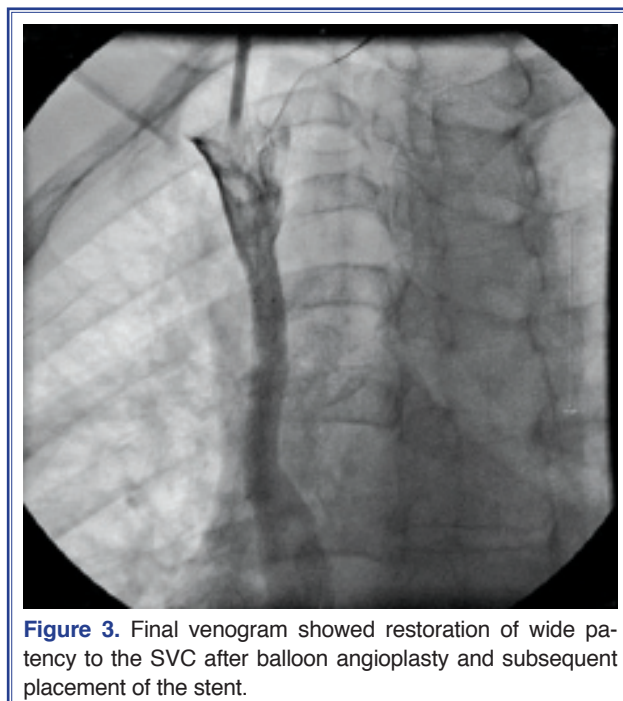
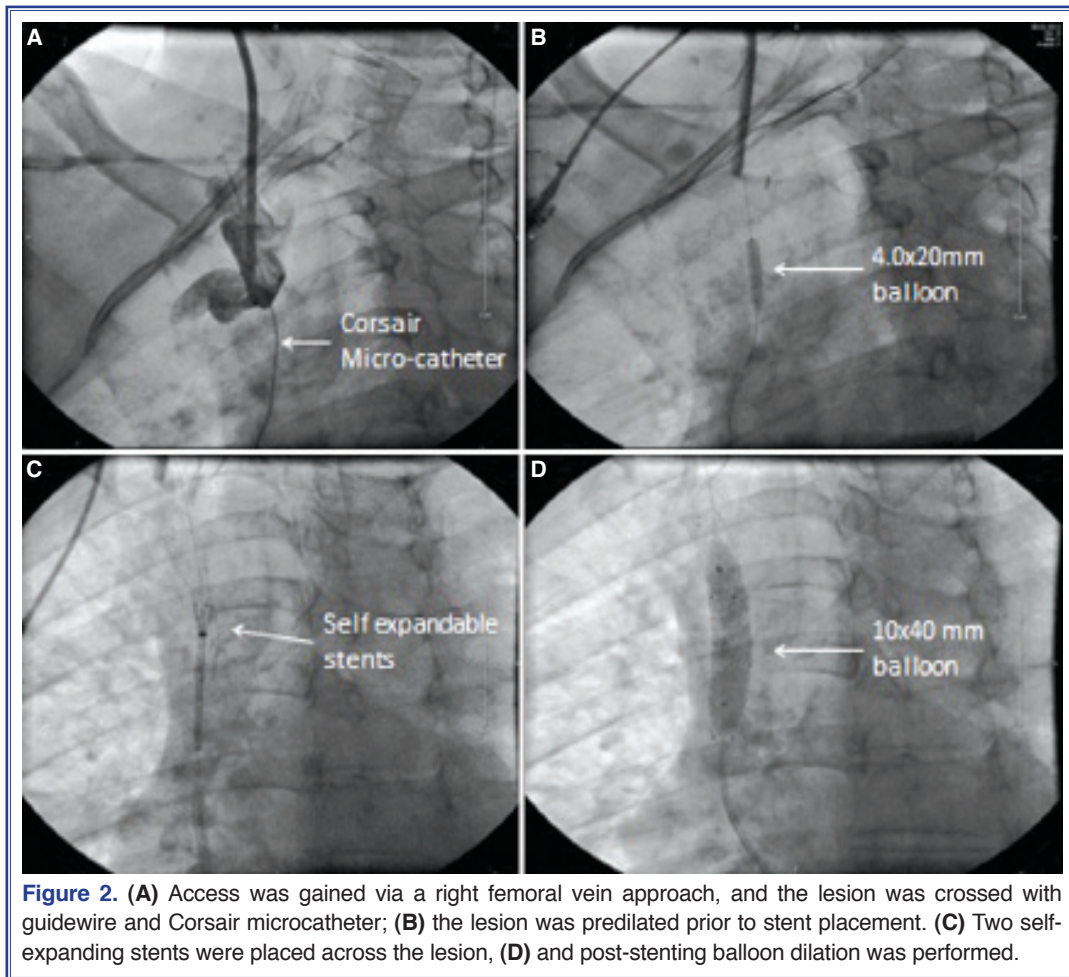
Figure 1. Nonsubtracted venography showing that chronic occlusion was of the superior vena cava. Venogram was performed with femoral and jugular vein approach.

its high overall success rate and low morbidity when compared to medical and surgical treatments.^[1] We present a case of successful stenting of SVC obstruction as a result of chronic thrombosis.

CASE REPORT

A 48-year-old woman had been diagnosed with thrombosis of the SVC one year before. The patient had hyperlipidemia, but there was no history of hypertension, diabetes mellitus or smoking. Despite using warfarin therapy for one year, the patient's symptoms progressively increased, and she finally presented with swelling of the face and both upper extremities. She had no history of central venous catheter, pacemaker, malignancy, trauma, or radiotherapy. There was no evidence of mass on the chest radiography or thoracoabdominal computed tomography (CT). On the physical examination, her vital signs were normal. Swelling of the face and fullness in her neck were noted. Multiple dilated tortuous veins were noticed on her upper chest and across her abdominal wall. The laboratory parameters were normal except for mildly elevated liver transaminase levels. The CT demonstrated obstruction of the SVC and extensive venous collateral circulation. Bilateral peripheral venography was then performed. Venography via right internal jugular and right common femoral vein approach demonstrated obstruction of

the SVC with venous collateral development (Fig. 1). Venography also revealed that the length of the lesion was approximately 4.5 cm. The pressure gradient between the right internal jugular vein and distal SVC was 21 mmHg. It was decided to treat the patient with percutaneous angioplasty and stenting. For the intervention, a multipurpose guiding catheter was introduced via the right femoral vein, and a sheath was placed in the right jugular vein. A 0.014" Fielder XT wire (Asahi Intec), with the help of a Corsair microcatheter (Asahi Intec), was used for crossing the occlusion. Since the wire could not cross the lesion, the Fielder XT wire was then changed sequentially with Miracle 3-g, Miracle 6-g and then Miracle 12-g wires (Abbott Vascular). Finally, the Miracle 12-g wire and Corsair microcatheter were passed through the entire obstruction (Fig. 2a), and dilatation was done with a 4-mm diameter balloon (Fig. 2b). Finally, two overlapping 9x40 mm self-expandable stents were implanted (Fig. 2c). Post-dilatation of the stent was then performed using a 10x40 mm balloon catheter (Fig. 2d). Good angiographic results were obtained (Fig. 3). After stent placement, the pressure gradient decreased to 6 mmHg. The patient's clinical symptoms improved immediately after stent implantation. The patient was discharged on clopidogrel and warfarin. She was asymptomatic six months after the intervention.



DISCUSSION

The SVC is the major drainage vessel for venous blood from the head, neck, upper extremities, and upper thorax. Obstruction of its flow increases venous pressure, which results in interstitial edema and retrograde collateral flow.^[3] More than 80% of cases of SVCS are caused by malignant lung tumors and lymphoma. Mediastinal fibrosis, aortic aneurysm, infections, benign mediastinal tumors, and thrombosis can also cause SVCS.^[4,5]

Upper extremity deep vein thrombosis may be primary or secondary. Secondary thromboses are those found in the presence of known risk factors, and are considerably more common than primary thromboses. In the past decade, the incidence of SVC thrombosis was found to be increasing due to the increased prevalence of indwelling catheters, cardiac pacemakers, and implantable central venous access devices for dialysis, chemotherapy, bone marrow transplantation,

and parenteral nutrition.^[1,6] The remaining cases of chronic upper extremity venous obstruction are related most commonly to hypercoagulable syndromes, malignancy, extrinsic compression, tumor invasion (Pancoast), trauma, and radiation.^[7] Primary thrombosis is rare and predominantly affects younger patients. Primary thrombosis includes those that develop from extrinsic compression of the axillary or subclavian veins by tendons, muscles, or bony thorax in the subcoracoid or costoclavicular spaces (Paget-Schroetter syndrome) or activities requiring repetitive motion.^[1] In our case, the cause of secondary thrombosis is not known. Occlusion of the SVC at the level of the azygos vein contributes to the appearance of collateral veins on the chest and abdominal walls, and venous blood flows via these collaterals into the inferior vena cava.^[4] In our case, there were diffuse collateral veins on the chest and abdominal walls.

Duplex ultrasound is the initial imaging test for diagnosis of chronic UEDVT and SVCS. Magnetic resonance angiography and CT angiography are accurate, noninvasive methods for detecting central venous stenosis or obstruction. Venography may be necessary to confirm the diagnosis of UEDVT or SVCS if clinical suspicion remains high despite negative duplex ultrasound evaluation. Venography is mandatory prior to interventions such as venoplasty or stent placement.

The treatment of chronic UEDVT and SVCS depends on the underlying cause, chronicity, and clinical presentation. In cases of acute thrombosis (with symptom onset of less than 2 days), thrombolytic therapy followed by anticoagulation, mechanical thrombectomy or catheter-directed thrombolysis is recommended. However, anticoagulation and catheter-directed or mechanical thrombolysis are less effective in chronic thrombosis (with onset of symptoms of more than 10 days) due to the organization of the thrombus.^[8] In malignant central venous obstruction, radiotherapy or chemotherapy is recommended, which is effective in 90% of cases.^[9] Endovascular or surgical intervention is often needed to treat SVCS related with dialysis access.

Tissue diagnosis is often necessary to direct treatment decisions.^[3] However, percutaneous venous angioplasty with the use of intravenous stents is a simple and safe method and provides nearly instantaneous symptomatic relief with high long-term patency in SVCS.^[4] Stenting in SVCS can be especially use-

ful when urgent intervention is indicated for patients with SVCS caused by malignant diseases without a tissue diagnosis. Stent migration can sometimes occur, but is less likely with self-expanding stents that are appropriately sized.^[10] In our case, we did not use thrombolytic or anticoagulant therapy or mechanical thrombectomy due to chronic thrombosis.

In conclusion, endovascular treatment of chronic SVC obstruction with venoplasty and stent placement is simple and safe. It also provides an effective symptomatic relief with high long-term patency in most of the SVCS's.

Conflict-of-interest issues regarding the authorship or article: None declared.

REFERENCES

1. Warren P, Burke C. Endovascular management of chronic upper extremity deep vein thrombosis and superior vena cava syndrome. *Semin Intervent Radiol* 2011;28:32-8. [CrossRef](#)
2. Greenspon AJ, Ruggiero II NJ, Gardiner GA. Percutaneous treatment of symptomatic superior vena cava syndrome following permanent pacemaker implantation. *The Journal of Innovations in Cardiac Rhythm Management* 2011;2:358-61.
3. Wilson LD, Detterbeck FC, Yahalom J. Clinical practice. Superior vena cava syndrome with malignant causes. *N Engl J Med* 2007;356:1862-9. [CrossRef](#)
4. Shaheen K, Alraies MC. Superior vena cava syndrome. *Cleve Clin J Med* 2012;79:410-2. [CrossRef](#)
5. Markman M. Diagnosis and management of superior vena cava syndrome. *Cleve Clin J Med* 1999;66:59-61. [CrossRef](#)
6. Hill SL, Berry RE. Subclavian vein thrombosis: a continuing challenge. *Surgery* 1990;108:1-9.
7. Joffe HV, Kucher N, Tapson VF, Goldhaber SZ; Deep Vein Thrombosis (DVT) FREE Steering Committee. Upper-extremity deep vein thrombosis: a prospective registry of 592 patients. *Circulation* 2004;110:1605-11. [CrossRef](#)
8. Akoglu H, Yilmaz R, Peynircioglu B, Arici M, Kirkpantur A, Cil B, et al. A rare complication of hemodialysis catheters: superior vena cava syndrome. *Hemodial Int* 2007;11:385-91.
9. Rösch J, Bedell JE, Putnam J, Antonovic R, Uchida B. Gianturco expandable wire stents in the treatment of superior vena cava syndrome recurring after maximum-tolerance radiation. *Cancer* 1987;60:1243-6. [CrossRef](#)
10. Bravo SM, Reinhart RD, Meyerovitz MF. Percutaneous venous interventions. *Vasc Med* 1998;3:61-6. [CrossRef](#)

Key words: Angioplasty, ballon; chronic thrombosis; stents; superior vena cava syndrome.

Anahtar sözcükler: Anjiyoplasti, balon; kronik tromboz; stentler; süperiyör vena kava sendromu.