

Thrombus attached to suture materials successfully thrombolysed with low-dose tissue plasminogen activator

Dikiş materyaline tutunmuş trombüsün düşük doz doku plazminojen aktivatörü ile başarılı şekilde eritilmesi

Macit Kalçık, M.D., Ozan Mustafa Gürsoy, M.D.,
Süleyman Karakoyun, M.D., Mehmet Özkan, M.D.

Department of Cardiology, Koşuyolu Kartal Heart Training and Research Hospital, Istanbul

Summary– Mechanical prosthetic heart valve thrombosis is one of the most common complications of valve surgery. We herein describe an unusual clinical vignette. A 60-year-old man who underwent prosthetic mitral valve reoperation suffered from nonobstructive thrombus attached to the elongated suture materials in the postoperative sixth month. The thrombus was precisely depicted by two- and three-dimensional transesophageal echocardiography and was successfully lysed with low-dose slow infusion of tissue plasminogen activator after failed heparin treatment.

Özet– Mekanik kapak trombozu kapak cerrahisinin en sık komplikasyonlarından biridir. Bu yazıda nadir bir olgu sunumuna yer verildi. Altmış yaşında bir erkek hastada yeniden yapılan kapak protezi ameliyatı sonrası altıncı ayda uzunca bırakılmış dikiş materyali arasına tutunmuş trombüs saptanmıştır. Trombüs iki ve üç boyutlu transözafajiyal ekokardiyografi ile net olarak gösterilmiş ve başarısız heparin tedavisi sonrası düşük dozda doku plazminojen aktivatörünün yavaş olarak infüzyonuyla başarılı şekilde eritilmiştir.

Mechanical prosthetic heart valve thrombosis is one of the most common complications of valve surgery. We herein describe an unusual clinical vignette.

CASE REPORT

A 60-year-old man, who had mechanical mitral valve replacement nine years ago, underwent surgical repair of a mitral prosthetic paravalvular leak related to infective endocarditis. Early postoperative two-dimensional (2D) and real-time three-dimensional (RT-3D) transesophageal echocardiography (TEE) revealed a normally functioning prosthesis with no residual leak. However, the suture material was significantly long (Figs. 1a, b). Six months later, the patient was admitted to the hospital with atypical symptoms and

subtherapeutic level of international normalized ratio (INR) for the last three months. Clinical and

Abbreviations:

2D	Two-dimensional
INR	International normalized ratio
RT-3D	Real-time three-dimensional
TEE	Transesophageal echocardiography

laboratory findings were not consistent with infective endocarditis. The transthoracic echocardiography was unremarkable. Nevertheless, 2D and RT-3D TEE were performed based on the subtherapeutic level of INR, and revealed a mobile thrombus measuring 15 mm (Figs. 1c, d), attached to the two suture materials. The patient was unresponsive to five days of heparin infusion. Due to the risk of thromboembolism, he underwent thrombolysis with low-dose (25 mg), slow-infusion (6 hours) tissue plasminogen activator (tPA), as previously reported by our group,^[1] resulting in a successful outcome.

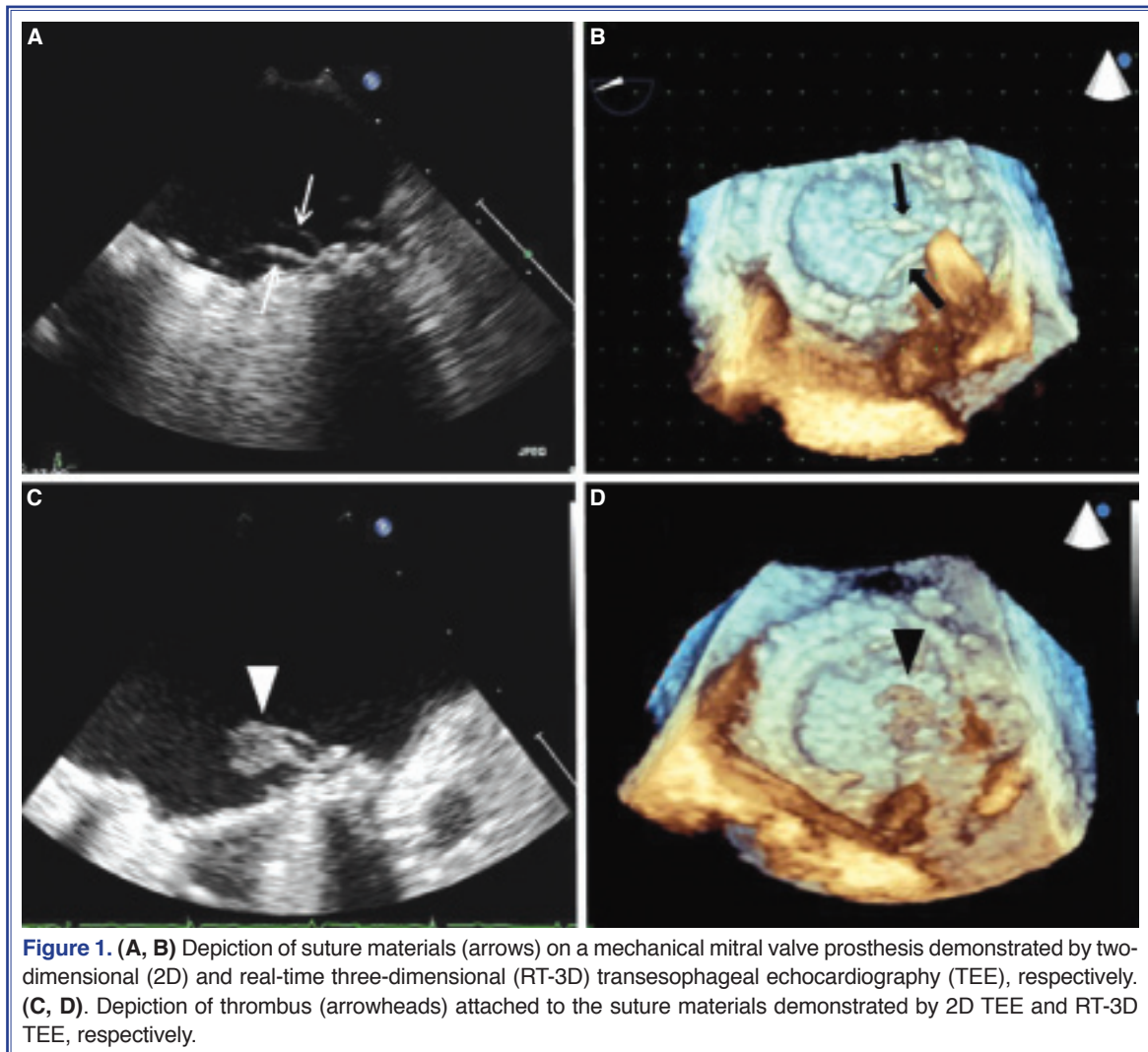
Received: April 29, 2013 Accepted: May 15, 2013

Correspondence: Dr. Ozan Mustafa Gürsoy. Denizler Caddesi, Cevizli Kavsığı, No: 2,
34846 Cevizli, Kartal, İstanbul.

Tel: +90 216 - 500 15 00 e-mail: m.ozangursoy@yahoo.com

© 2014 Turkish Society of Cardiology





DISCUSSION

The potential risk of thromboemboli due to suture material, especially when relatively long, should be kept in mind. Thrombolysis has emerged as an attractive treatment in prosthetic valve thrombosis.^[1-3] Most of the mobile nonobstructive thrombi can be thrombolysed with negligible embolic risk, especially when heparin treatment fails.^[3] There is no consensus regarding the dose, route of administration or optimal duration of thrombolytic therapy, although low-dose, slow-infusion t-PA may induce thrombolysis with lower risk of hemorrhage and embolization.^[1] RT-3D TEE, a recently introduced imaging method, is a useful complementary diagnostic tool in the delineation of prosthetic valve dysfunctions.^[4,5]

Although any foreign body within the heart, including sutures, can serve as a nidus, this is the first report of a thrombus attached to the suture materials in a patient with mitral prosthesis.

Conflict-of-interest issues regarding the authorship or article: None declared.

REFERENCES

- Özkan M, Gündüz S, Biteker M, Astarcioglu MA, Çevik C, Kaynak E, et al. Comparison of different TEE-guided thrombolytic regimens for prosthetic valve thrombosis: the TROIA trial. *JACC Cardiovasc Imaging* 2013;6:206-16. [CrossRef](#)
- Ozkan M, Kaymaz C, Kirma C, Sönmez K, Ozdemir N, Balkanay M, et al. Intravenous thrombolytic treatment of mechanical prosthetic valve thrombosis: a study using serial transesophageal echocardiography. *J Am Coll Cardiol*

- 2000;35:1881-9. [CrossRef](#)
3. Lengyel M, Horstkotte D, Völler H, Mistiaen WP; Working Group Infection, Thrombosis, Embolism and Bleeding of the Society for Heart Valve Disease. Recommendations for the management of prosthetic valve thrombosis. *J Heart Valve Dis* 2005;14:567-75.
 4. Pattabiraman V, Nanda NC, Iqbal F, Singh P, Koneru J, Akins C. Incremental value of three-dimensional over two-dimensional transesophageal echocardiography in the assessment of acute dysfunction of mechanical mitral valve prosthesis. *Echocardiography* 2010;27:885-7. [CrossRef](#)
 5. Ozkan M, Kaya H, Biteker M, Duran NE. Prosthetic mitral valve thrombosis demonstrated by real-time 3D transesophageal echocardiography. *Turk Kardiyol Dern Ars* 2009;37:209.
-
- Key words:** Echocardiography, three-dimensional/methods; echocardiography, transesophageal; heart valve prosthesis; sutures.
- Anahtar sözcükler:** Ekokardiyografi, üç-boyutlu/yöntem; ekokardiyografi, transözofajiyal; kalp kapak protezi; dikişler.