

## Aortic knob calcification and coronary artery lesion complexity in non-ST-segment elevation acute coronary syndrome patients

### ST-segment yükselmesi olmayan akut koroner sendromlu hastalarda aort topuzu kalsifikasyonu ile koroner lezyonunun kompleksliği arasında ilişki

Levent Korkmaz, M.D., Adem Adar, M.D., Ayça Ata Korkmaz, M.D.,<sup>#</sup>

Hakan Erkan, M.D., Mustafa Tarık Ağa, M.D., Zeydin Acar, M.D., Ali Rıza Akyüz, M.D.,

Hüseyin Bektaş, M.D., Şükrü Çelik, M.D.

Ahi Evren Thoracic and Cardiovascular Surgery Training and Research Hospital, Trabzon;

<sup>#</sup>Akcaabat Hackalı Baba State Hospital, Trabzon

#### ABSTRACT

**Objectives:** Coronary artery lesion complexity is important for risk stratification of acute coronary syndrome (ACS) patients undergoing cardiac catheterization. SYNTAX score is a pure angiographic measure of anatomic coronary complexity. Chest radiography is a routine examination for evaluating patients with chest pain. There have been no studies to date exploring the relation between aortic knob calcification (AKC) and coronary lesion complexity assessed by SYNTAX score.

**Study design:** 135 consecutive patients with first time diagnosis of non-ST segment elevation ACS were enrolled. SYNTAX score was calculated by dedicated computer software. Aortic calcification was assessed visually.

**Results:** Patients with AKC had higher SYNTAX score compared to those without AKC (16±6 vs. 11±7, p=0.019). Also, patients with AKC had higher TIMI risk score and were more elderly. Linear regression analysis demonstrated AKC (95% confidence interval [CI] 1.7-6.9, p=0.002), diabetes (95% CI, 1.1-5.7, p=0.005), and smoking (95% CI, 1.2-13.5, p=0.004) as independent determinants of SYNTAX score.

**Conclusion:** Aortic calcification detected on chest X-ray is an independent predictor of complex coronary artery lesions in patients with ACS.

Identification of acute coronary syndrome (ACS) patients with higher cardiovascular risk is important in estimating the prognosis and triage of these patients. Current risk scores are based on clinical, biochemical, and/or electrocardiographic variables.<sup>[1,2]</sup> Beyond

#### ÖZET

**Amaç:** Koroner arter lezyonunun kompleksliği akut koroner sendromlu (AKS) hastalarda risk katmanlaması için önemlidir. SYNTAX skoru koroner anatomisinin kompleksliğini gösteren bir parametredir. Akciğer grafisi göğüs ağrısı olan hastaların değerlendirilmesinde rutin olarak yapılan bir incelemedir. Teleradyografide aort topuzu kalsifikasyonu (ATK) ile koroner lezyon kompleksliği arasındaki ilişkiyi inceleyen herhangi bir SYNTAX skoru çalışması yoktur.

**Çalışma planı:** Çalışmaya ST-yükselmesi olmayan AKS tanısıyla başvuran ardışık 135 hasta alındı. SYNTAX skoru bilgisayar programı ile hesaplandı. ATK akciğer grafisinde değerlendirildi.

**Bulgular:** SYNTAX skoru ATK'si olanlarda olmayanlara göre daha yüksek idi (16±6 ve 11±7, p=0.019). Ayrıca ATK'si olan hastaların TIMI risk skoru daha yüksek ve yaşları daha ileri idi. Lineer regresyon analizinde ATK (%95 Güven Aralığı [GA] 1.7-6.9, p=0.002) diyabet (%95 GA, 1.1-5.7, p=0.005) ve sigara içimi (%95 GA, 1.2-13.5, p=0.004) SYNTAX skorunun bağımsız öngördürücüleri idi.

**Sonuç:** Akciğer grafisinde ATK'nin varlığı AKS'li hastalarda kompleks koroner lezyonlarının bağımsız bir öngördürücüsüdür.

the known clinical and laboratory predictors, baseline angiographic markers of disease burden, calcification, lesion severity and morphological characteristics have important independent predictive value for 30-day and 1-year ischemic outcomes in ACS patients.<sup>[3]</sup>

Received: March 19, 2012 Accepted: July 26, 2012

Correspondence: Dr. Levent Korkmaz, Ahi Evren Göğüs Kalp Damar Cerrahisi Eğitim ve Araştırma Hastanesi, Trabzon, Turkey.

Tel: +90 462 - 231 19 07 e-mail: l.korkmaz@yahoo.com

© 2012 Turkish Society of Cardiology

The SYNTAX score is a comprehensive angiographic scoring system that is derived entirely from the coronary anatomy and lesion characteristics.<sup>[4-6]</sup>

Chest radiography is routinely ordered during emergency evaluations of patients with suspected myocardial angina to screen for other causes of undifferentiated chest pain such as pneumothorax, aortic dissection, abdominal free air, or pneumonia. Recently, it has been shown that aortic knob calcification (AKC) assessed on chest radiography is closely related to significant coronary artery stenosis and is a reliable predictor of multivessel coronary artery disease in patients with unstable angina.<sup>[7]</sup> However, thus far, no study has examined the association between AKC and coronary lesion complexity determined by SYNTAX score. Therefore, the main purpose of the present study was to investigate the relationship between AKC and coronary artery lesions complexity in non-ST segment elevation acute coronary syndromes (NSTEMI-ACS).

## PATIENTS AND METHODS

### Patients

Consecutive patients with first time diagnosis of NSTEMI-ACS undergoing coronary angiography and intervention were enrolled into the study. NSTEMI-ACS was diagnosed when an elevation of troponin T level ( $>0.01$  ng/mL in any sample during the admission) and/or a typical CKMB curve occurred, with or without ST/T changes in the ECG, in the absence of any other demonstrable cause for the chest pain. None of the patients had a history of cardiovascular events or coronary revascularization. In our institute, chest X-ray is routinely ordered and SYNTAX score is calculated for every ACS patients undergoing coronary revascularization. Thus, we did not apply for a statement of patient consent or the approval of Internal Review Boards.

Patients with a history of myocardial infarction, valvular disease, acute or chronic heart failure, cardiomyopathy, systolic dysfunction, ejection fraction  $<50\%$ , known or suspected infectious or inflammatory conditions, need of urgent coronary angiography and intervention, renal, hepatic, or neoplastic diseases were excluded. Patients with ST-elevations on admission ECG, new left bundle branch block or new Q waves on the evolution of ECG were also excluded

from the study. Moreover, we excluded patients whose chest X-ray was not properly centered, if there was any deviation of the trachea or shift of the mediastinum, and if there was any known disease in the aorta such as aortitis.

### Abbreviations:

ACS	Acute coronary syndrome
AKC	Aortic knob calcification
MACE	Major adverse cardiac events
NSTEMI	Non-ST segment elevation
PCI	Percutaneous coronary intervention

### Coronary angiography and SYNTAX score

Coronary angiography was performed by the Judkins technique and analyzed by two experienced observers. Each angiogram was analyzed independently by two experienced interventional cardiologists who were blinded to the patients clinical data. In cases of disagreement, the decision of a third observer was obtained and the final decision was made by consensus. Each coronary lesion producing 50% diameter stenosis in vessels greater than 1.5 mm was scored separately and added together to provide the overall SYNTAX score, which was calculated prospectively using the SYNTAX score algorithm.<sup>[6]</sup>

### Assessment of aortic knob calcification

All patients underwent a chest radiography in the posteroanterior (PA) view. An examiner who was unaware of the clinical and angiographic data reviewed the chest radiography. Patients with small spots or a single thin area of calcification are considered to have AKC (Fig. 1).

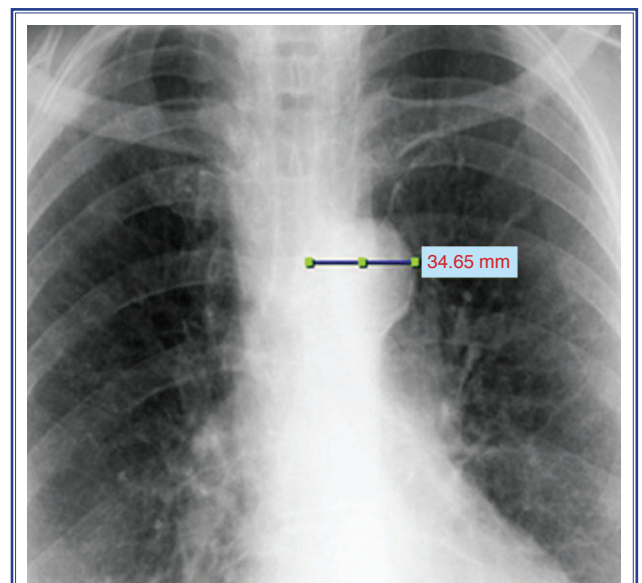


Figure 1. Measurement of aortic knob.

**Table 1. Baseline characteristics of study population**

	n	%	Mean±SD
Age (years)			62±11
Gender (male)	95	70	
BMI (kg/m <sup>2</sup> )			27±3.3
Dyslipidemia	78	57	
Diabetes mellitus	56	41	
Smoking	64	47	
Hypertension	73	54	
Presence of AKC	74	55	
SYNTAX Score			14±7
TIMI risk score			3.6±0.9
TIMI (0-2)	16	12	
TIMI (3-4)	74	55	
TIMI (5-7)	45	33	
Number of diseased vessel			
One vessel	54	40	
Two vessels	46	34	
Three vessels	35	26	

BMI: Body mass index; AKC: Aortic knob calcification;  
TIMI: Thrombolysis in myocardial infarction.

### Statistical analysis

Continuous variables were expressed as mean ± standard deviation (SD) and categorical variables were expressed as a percentage. An analysis of normality

of the continuous variables was performed with the Kolmogorov-Smirnov test. Student's t-test and the Mann-Whitney U-test were used in order to compare continuous variables between groups. Categorical variables were compared by chi-square test. Linear regression analysis was done to determine independent predictors of AKC. Variables with a *p* value <0.1 for correlation with AKC were added to the multiple linear regression analysis. Statistical analysis was performed using SPSS for Windows 14.0 and a *p* value ≤0.05 was considered statistically significant.

### RESULTS

Clinical and laboratory characteristics of the study population are reported in Table 1. AKC was detected in 74 patients (55%). Patients with AKC had higher SYNTAX score compared to those without AKC (16±6 vs. 11±7, *p*=0.019) (Table 2). Also, patients with AKC had higher TIMI risk score and were older.

There was a statistically significant correlation between SYNTAX score and age (*r*=0.35, *p*<0.001), diabetes (*r*=0.24, *p*=0.005), smoking (*r*=0.31, *p*<0.001), and AKC (*r*=0.36, *p*<0.001) (Table 3). Linear regression analysis demonstrated AKC (95% confidence interval [CI] 1.7-6.9, *p*=0.002), diabetes (95% CI, 1.1-5.7, *p*=0.005) and smoking (95% CI, 1.2-13.5, *p*=0.004) as independent determinants of SYNTAX score (Table 3).

**Table 2. Comparison of study population**

	AKC (-) (n=61)			AKC (+) (n=74)			<i>p</i>
	n	%	Mean±SD	n	%	Mean±SD	
Age (years)			56±10			66±9	<0.001
Gender (male)	43	71		52	70		0.37
BMI (kg/m <sup>2</sup> )			27±4.1			27±3.7	0.42
Dyslipidemia	38	62		40	54		0.33
Diabetes mellitus	21	34		35	47		0.13
Smoking	30	49		34	46		0.08
Hypertension	31	51		42	57		0.72
SYNTAX score			11±7			16±7	0.01
TIMI risk score			3.3±0.9			3.9±0.8	0.02
Number of diseased vessel			1.7±0.8			2±0.8	0.26

AKC: Aortic knob calcification; BMI: Body mass index; TIMI: Thrombolysis in myocardial infarction.

**Table 3. Correlation and linear regression analysis of variables and SYNTAX score**

	r	p	$\beta$	p	95% CI
Age	0.35	<0.001	0.11	0.08	-0.1–0.23
Gender (male)	0.09	0.11	–	–	–
Dyslipidemia	0.1	0.24	–	–	–
Diabetes mellitus	0.24	0.005	0.23	0.005	1.1–5.7
Smoking	0.31	<0.001	0.22	0.004	1.2–13.5
Hypertension	0.07	0.4	–	–	–
TIMI risk score	0.04	0.7	–	–	–
AKC	0.36	<0.001	0.28	0.002	1.7–6.9

CI: Confidence interval; AKC: Aortic knob calcification.

## DISCUSSION

In the present study, we have demonstrated an independent and significant association between AKC and coronary artery lesion complexity. Another important finding is that a well known risk stratification marker, TIMI risk score, could not provide predictive information on coronary lesion complexity in our analysis.

The SYNTAX score is widely accepted as a CAD complexity marker and its prognostic value has been demonstrated in a variety of different clinical situations. Patients with the highest tertile SYNTAX score experience significantly more major adverse cardiac events (MACEs).<sup>[8–10]</sup> Wykrzykowska et al.<sup>[11]</sup> demonstrated the independent predictive value of SYNTAX score for MACEs and mortality not only in selected patient groups, but also in all CAD treated by percutaneous coronary intervention (PCI). Moreover, SYNTAX score has a role in the risk stratification of patients with STEMI having primary PCI and is a useful tool that provides additional risk stratification according to known risk factors of long-term mortality and MACEs.<sup>[11,12]</sup> The clinical significance of SYNTAX score also has been shown in NSTEMI patients with ACS.<sup>[13]</sup> Patients with higher SYNTAX score had increased rates of all-cause mortality, cardiac mortality, and myocardial infarction both within the first 30 days after PCI and between 30 days and 1 year. These early and late MACEs in patients with higher SYNTAX score may be due to the increased periprocedural risks associated with complex lesions and diffuse atherosclerosis.

The aortic knob is a radiographic structure that is formed by the foreshortened aortic arch and a portion

of the descending aorta. Aortic calcification has an underlying atherosclerosis process and calcification in extracoronary arterial beds indicates the extent of atherosclerotic lesions.<sup>[14–17]</sup> Also, extracoronary calcification is associated with increased risk of cardiovascular events.<sup>[18–20]</sup> AKC is one form of extracoronary arterial calcification and its detection on chest X-ray increases risk for CAD.<sup>[21]</sup> Also, AKC is an independent predictor of cardiovascular events beyond traditional cardiovascular risk factors.<sup>[22]</sup> Yun et al.<sup>[7]</sup> demonstrated the positive predictive value of AKC as a marker of significant and multi-vessel coronary artery stenosis in unstable angina pectoris patients. Although there have been no studies comparing different scores in terms of coronary lesion complexity that take into account lesion properties such as bifurcation or trifurcation, lesion length, severe angulation and calcification, thrombus, or vessel diameter, some previously used classification systems may be too simplistic in comparison to the detailed analysis summarized by the SYNTAX score.

## Limitations

Our study has several limitations. First of all, the study population is relatively small. Also, we excluded patients with previous CAD or having any coronary revascularization. Moreover, we included only those who underwent coronary catheterization and subsequent revascularisation. Therefore, our study cannot represent the entire ACS population. Another important limitation is the cross-sectional study design, which prevents us from determining whether patients with higher SYNTAX score face increased MACE incidence in short and long term of follow-up. Moreover, we did not quantify AKC, not only because

of the small size of study population and its dependence on the operator, but also with the aim of simple and easy evaluation of the aortic knob.

In conclusion, evaluation of chest radiographs for AKC adds no cost and is exceptionally simple. Our preliminary findings may give further utility to the chest radiograph as a screening examination and, if confirmed, could assist risk stratification in patients with ACS.

**Conflict-of-interest issues regarding the authorship or article: None declared**

## REFERENCES

- Antman EM, Cohen M, Bernink PJ, McCabe CH, Horacek T, Papuchis G, et al. The TIMI risk score for unstable angina/non-ST elevation MI: A method for prognostication and therapeutic decision making. *JAMA* 2000;284:835-42.
- Eagle KA, Lim MJ, Dabbous OH, Pieper KS, Goldberg RJ, Van de Werf F, et al. A validated prediction model for all forms of acute coronary syndrome: estimating the risk of 6-month postdischarge death in an international registry. *JAMA* 2004;291:2727-33.
- Lansky AJ, Goto K, Cristea E, Fahy M, Parise H, Feit F, Clinical and angiographic predictors of short- and long-term ischemic events in acute coronary syndromes: results from the Acute Catheterization and Urgent Intervention Triage strategy (ACUITY) trial. *Circ Cardiovasc Interv* 2010;3:308-16.
- Sianos G, Morel MA, Kappetein AP, Morice MC, Colombo A, Dawkins K, et al. The SYNTAX Score: an angiographic tool grading the complexity of coronary artery disease. *Euro-Intervention* 2005;1:219-27.
- Serruys PW, Onuma Y, Garg S, Sarno G, van den Brand M, Kappetein AP, et al. Assessment of the SYNTAX score in the Syntax study. *EuroIntervention* 2009;5:50-6.
- SYNTAX Working Group. SYNTAX score calculator. Available at: <http://www.syntaxscore.com>. Accessed 15 september 2011.
- Yun KH, Jeong MH, Oh SK, Park EM, Kim YK, Rhee SJ, et al. Clinical significance of aortic knob width and calcification in unstable angina. *Circ J* 2006;70:1280-3.
- Valgimigli M, Serruys PW, Tsuchida K, Vaina S, Morel MA, van den Brand MJ, et al. Cyphering the complexity of coronary artery disease using the syntax score to predict clinical outcome in patients with three-vessel lumen obstruction undergoing percutaneous coronary intervention. *Am J Cardiol* 2007;99:1072-81.
- Serruys PW, Morice MC, Kappetein AP, Colombo A, Holmes DR, Mack MJ, et al. Percutaneous coronary intervention versus coronary-artery bypass grafting for severe coronary artery disease. *N Engl J Med* 2009;360:961-72.
- Serruys PW, Onuma Y, Garg S, Vranckx P, De Bruyne B, Morice MC, et al. 5-year clinical outcomes of the ARTS II (Arterial Revascularization Therapies Study II) of the sirolimus-eluting stent in the treatment of patients with multivessel de novo coronary artery lesions. *J Am Coll Cardiol* 2010;55:1093-101.
- Wykrzykowska JJ, Garg S, Girisic C, de Vries T, Morel MA, van Es GA, et al. Value of the SYNTAX score for risk assessment in the all-comers population of the randomized multicenter LEADERS (Limus Eluted from A Durable versus ERodable Stent coating) trial. *J Am Coll Cardiol* 2010;56:272-7.
- Magro M, Nauta S, Simsek C, Onuma Y, Garg S, van der Heide E, et al. Value of the SYNTAX score in patients treated by primary percutaneous coronary intervention for acute ST-elevation myocardial infarction: The MI SYNTAXscore study. *Am Heart J* 2011;161:771-81.
- Garg S, Sarno G, Serruys PW, Rodriguez AE, Bolognese L, Anselmi M, et al. Prediction of 1-year clinical outcomes using the SYNTAX score in patients with acute ST-segment elevation myocardial infarction undergoing primary percutaneous coronary intervention: a substudy of the STRATEGY (Single High-Dose Bolus Tirofiban and Sirolimus-Eluting Stent Versus Abciximab and Bare-Metal Stent in Acute Myocardial Infarction) and MULTISTRATEGY (Multicenter Evaluation of Single High-Dose Bolus Tirofiban Versus Abciximab With Sirolimus-Eluting Stent or Bare-Metal Stent in Acute Myocardial Infarction Study) trials. *JACC Cardiovasc Interv* 2011;4:66-75.
- Palmerini T, Genereux P, Caixeta A, Cristea E, Lansky A, Mehran R, et al. Prognostic value of the SYNTAX score in patients with acute coronary syndromes undergoing percutaneous coronary intervention: analysis from the ACUITY (Acute Catheterization and Urgent Intervention Triage Strategy) trial. *J Am Coll Cardiol* 2011;57:2389-97.
- Wexler L, Brundage B, Crouse J, Detrano R, Fuster V, Madhavi J, et al. Coronary artery calcification: pathophysiology, epidemiology, imaging methods, and clinical implications. A statement for health professionals from the American Heart Association. Writing Group. *Circulation* 1996;94:1175-92.
- Papanas N, Symeonidis G, Maltezos E, Giannakis I, Mavridis G, Lakasas G, et al. Evaluation of aortic arch calcification in type 2 diabetic patients. *Vasa* 2005;34:113-7.
- Simon A, Giral P, Levenson J. Extracoronary atherosclerotic plaque at multiple sites and total coronary calcification deposit in asymptomatic men. Association with coronary risk profile. *Circulation* 1995;92:1414-21.
- Iijima K, Hashimoto H, Hashimoto M, Son BK, Ota H, Oga S, et al. Aortic arch calcification detectable on chest X-ray is a strong independent predictor of cardiovascular events beyond traditional risk factors. *Atherosclerosis* 2010;210:137-44.
- Witteaman JC, Kok FJ, van Saase JL, Valkenburg HA. Aortic

- calcification as a predictor of cardiovascular mortality. *Lancet* 1986;2:1120-2.
20. Cohen A, Tzourio C, Bertrand B, Chauvel C, Bousser MG, Amarenco P. Aortic plaque morphology and vascular events: a follow-up study in patients with ischemic stroke. FAPS Investigators. French Study of Aortic Plaques in Stroke. *Circulation* 1997;96:3838-41.
21. Yamamoto H, Shavelle D, Takasu J, Lu B, Mao SS, Fischer H, et al. Valvular and thoracic aortic calcium as a marker of the extent and severity of angiographic coronary artery disease. *Am Heart J* 2003;146:153-9.
22. Li J, Galvin HK, Johnson SC, Langston CS, Sciamberg J, Preston CA. et al. Aortic calcification on plain chest radiography increases risk for coronary artery disease. *Chest* 2002;121:1468-71.

---

*Key words:* Acute coronary syndrome; aortic diseases/radiography; calcinosis; coronary artery disease; SYNTAX score; vascular calcification.

*Anahtar sözcükler:* Akut koroner sendrom; aort hastalıkları/radyografi; kalsinosis; koroner arter hastalığı; SYNTAX skoru; vasküler kalsifikasyon.