



## “Face of the Giant Panda” Sign in Wilson Disease *Wilson Hastalığında “Dev Pandanın Yüzü” İşareti*

✉ Mehmet Atalar<sup>1</sup>, ✉ Nisa Başpınar<sup>2</sup>

<sup>1</sup>Cumhuriyet University Faculty of Medicine, Department of Radiology, Sivas, Turkey

<sup>2</sup>Nazilli State Hospital, Clinic of Radiology, Aydin, Turkey

**Keywords:** Face of giant panda sign, magnetic resonance imaging, tegmentum, Wilson disease

**Anahtar Kelimeler:** Dev pandanın yüzü işareti, manyetik rezonans görüntüleme, tegmentum, Wilson hastalığı

Dear Editor,

Wilson disease (hepatolenticular degeneration) is an autosomal recessive disorder caused by mutations of the Wilson disease (ATP7B) protein produced by chromosome 13. It manifests with an inability to excrete copper in bile, and copper deposition in liver, brain, and other organs. Clinical signs and symptoms include liver function and psychiatric disorders. Although copper accumulation mostly occurs in the basal ganglia, it may involve all parts of the brain. Brain magnetic resonance imaging (MRI) is a useful diagnostic tool and helps determine disease severity and treatment response (1,2,3).

A 7-year-old boy was referred by an outside center with jaundice, hypoalbuminemia, dystonia, and tremor. His past and family histories were non-remarkable. His physical examination revealed extreme weakness, pallor, and icterus affecting the sclerae and entire body. His liver was palpable but there was no splenomegaly. His laboratory investigations revealed the following: serum copper 67 (normal: 85-150) mg/dL, serum ceruloplasmin 5.5 (normal: 15-60) mg/dL, and 24-hour urinary copper 120 (normal: 50-70) mg/day. Other routine blood chemistry investigations were all within the normal range. In addition to other diagnostic markers such as serum copper, ceruloplasmin, and urinary copper, the patient also showed MRI signs. On T2-weighted MRI images, there was a hyperintense region in the tegmentum. The red nuclei, substantia nigra, and superior colliculi were spared. Additionally, a thin hyperintense rim was observed in the

claustrum. The MRI signs appeared as the “face of the giant panda” sign (Figure 1). The patient was treated with penicillin and zinc.

In patients with neurologic symptoms, T2 hyperintensity is noted in the putamen, caudate nucleus, thalamus, midbrain, and pons. Atrophy of the brain and brain stem may occur in long-standing cases. The “face of the giant panda” sign was first described in 1991 by Hitoshi et al. (1) in patients with Wilson disease. This sign is caused by a combination of signal intensity changes at the level of the midbrain on T2-weighted MR images. The sign results from a higher signal intensity in the tegmentum, and additionally, normal signal intensity in the red nucleus (panda’s eyes) and the lateral part of the pars reticularis of the substantia nigra (panda’s ears), as well as hypointensity of the superior colliculi (panda’s chin). The exact pathogenesis of superior colliculus hypointensity is unknown. It has been proposed that the paramagnetic effect of heavy metal accumulation (for example, copper, iron) may be responsible for this condition. In Wilson disease, iron deposition is more important for forming T2 hypointensity than iron (1,2,3,4,5).

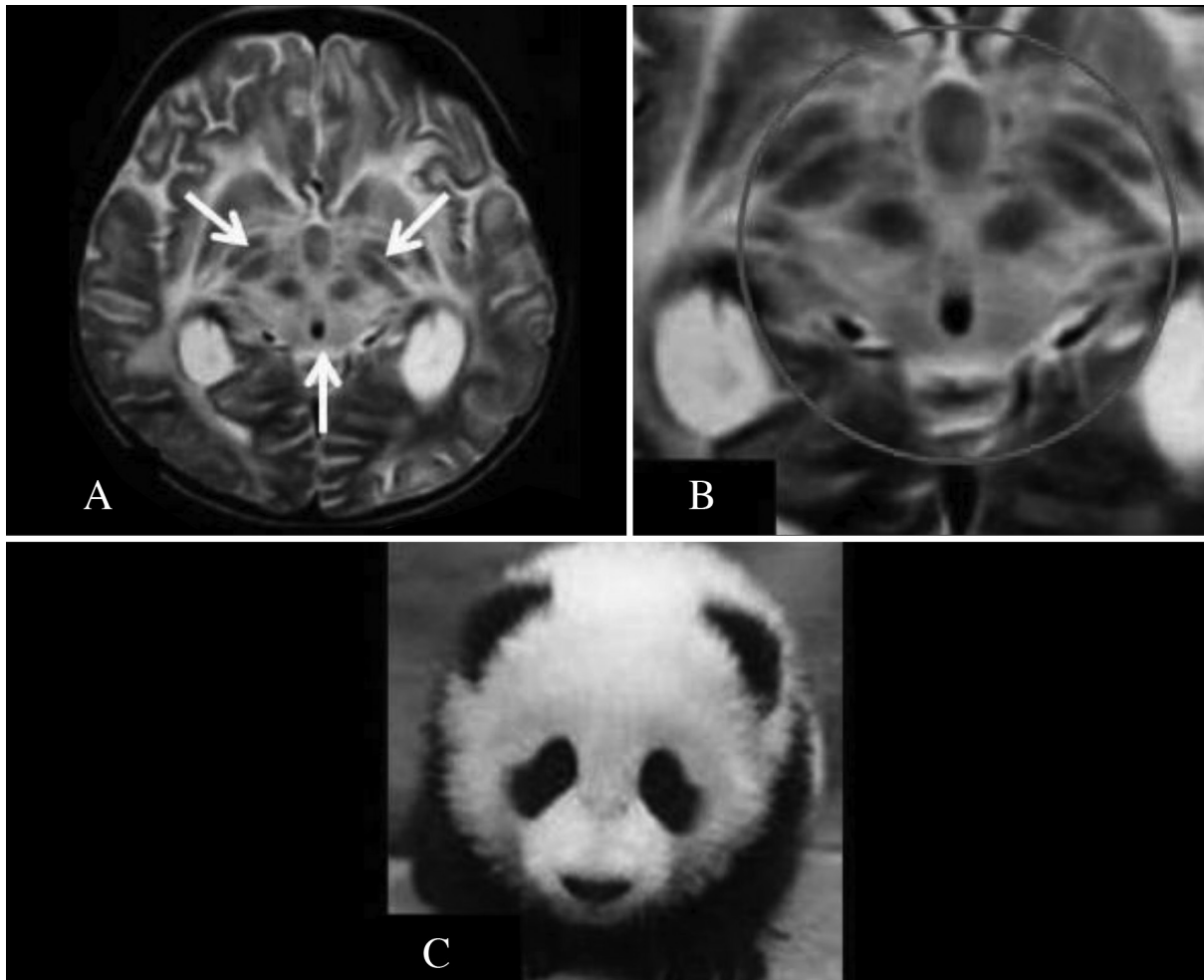
The face of the giant panda is rarely observed. In a study comprising 100 patients, it was found in 12% of subjects (4). Neuroimaging signs resembling those of Wilson disease may also be detected in other conditions such as Leigh disease, hypoxic-ischemic encephalopathy, methyl alcohol intoxication, Japan B encephalitis, and extrapontine myelinolysis. The characteristic clinical features of those conditions distinguish them from Wilson disease (1,2,3).

**Address for Correspondence/Yazışma Adresi:** Mehmet Atalar MD, Cumhuriyet University Faculty of Medicine, Department of Radiology, Sivas, Turkey

Phone: +90 542 574 73 13 E-mail: mhatalar@gmail.com ORCID: orcid.org/0000-0003-3076-8072

**Received/Geliş Tarihi:** 28.12.2018 **Accepted/Kabul Tarihi:** 03.03.2019

©Copyright 2019 by Turkish Neurological Society  
Turkish Journal of Neurology published by Galenos Publishing House.



**Figure 1.** (A) Axial T2-weighted magnetic resonance image shows hyperintensity of the midbrain. It is also shown that the hypointensity of the red nucleus, superior colliculus, part of the pars reticularis of the substantia nigra, and the aqueduct were relatively spared (white arrows). (B) The magnified image of the image in (A) (red circle). (C) A photograph of a giant panda

#### Ethics

**Informed Consent:** Consent form was filled out by all participants.

**Peer-review:** Internally peer-reviewed.

#### Authorship Contributions

Surgical and Medical Practices: M.A., N.B., Concept: M.A., Design: M.A., Data Collection or Processing: M.A., N.B., Analysis or Interpretation: M.A., N.B., Literature Search: M.A., Writing: M.A., N.B.

**Conflict of Interest:** No conflict of interest was declared by the authors.

**Financial Disclosure:** The authors declared that this study received no financial support.

#### References

1. Hitoshi S, Iwata M, Yoshikawa K. Mid-brain pathology of Wilson's disease: MRI analysis of three cases. *J NeurolNeurosurg Psychiatry* 1991;54:624-626.
2. Vella S, Grech R. Highlighting an atypical cause of the Face of the Giant Panda sign. *BJR Case Rep* 2017;4:20170046.
3. Panda AK, Mehta VJ, Dung AA, Kushwaha S. Face of giant panda sign in Wilson's disease. *J Assoc Physicians India* 2014;62:707-708.
4. Gupta A, Chakravarthi S, Goyal MK. 'Face of giant panda': a rare imaging sign in Wilson's disease. *QJM* 2014;107:579.
5. Sinha S, Taly AB, Ravishankar S, Prashanth LK, Venugopal KS, Arunodaya GR, et al. Wilson's disease: Cranial MRI observations and clinical correlation. *Neuroradiology* 2006;48:613-621.