



Neurological Manifestation of Legionnaire's Disease *Lejyoner Hastalığının Nörolojik Belirtisi*

✉ Burcu Işık, ✉ Ferhat Arslan

Istanbul Medeniyet University, Goztepe Training and Research Hospital, Clinic of Infectious Diseases and Clinical Microbiology, Istanbul, Turkey

Keywords: Corpus callosum splenium, transient ischemia, *Legionella* spp., Legionnaires' disease

Anahtar Kelimeler: Korpus kallosum splenium, geçici iskemi, *Legionella* spp., Lejyoner hastalığı

Dear Editor,

A 48-year-old male patient was admitted to the emergency room with symptoms of fever, malaise, ataxic gait, slurred speech, and urinary incontinence, which abruptly started in one day. He was conscious, oriented, and cooperative. His vital signs were normal except for high-grade fever. We auscultated basal crackles on his right lung. In the laboratory analysis, white blood cells: 4600/mm³ (84% neutrophils), C-reactive protein: 25 mg/dL (normal:

0-0.5 mg/dL), creatinine: 0.9 mg/dL, aspartate transaminase: 181 U/L, and alanine transaminase: 79 U/L were detected. Chest X-ray and computed tomography showed pneumonic infiltration in the right lower lobe (Figure 1). Diffusion magnetic resonance imaging (MRI) revealed a hyperintense lesion in diffusion-weighted images and a hypointense lesion in the corpus callosum splenium, consistent with a slightly restricted diffusion pattern in the apparent diffusion coefficient map (Figure 2A, 2B, 2C). Empirical

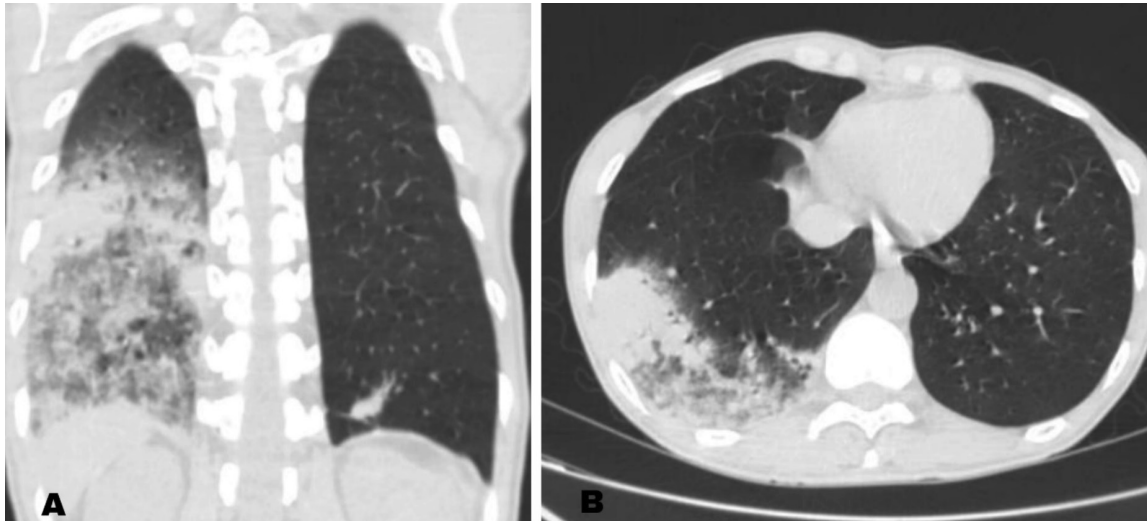


Figure 1. A, B) Coronal and axial non-contrast computed tomography images show diffuse pneumonic consolidation appearance in the lower lobe and the middle lobe of the right lung

Address for Correspondence/Yazışma Adresi: Burcu Işık MD, Istanbul Medeniyet University, Goztepe Training and Research Hospital, Clinic of Infectious Diseases and Clinical Microbiology, Istanbul, Turkey

Phone: +90 546 594 62 91 E-mail: burcu091991@gmail.com ORCID ID: orcid.org/0000-0002-0428-857X

Received/Geliş Tarihi: 22.09.2018 **Accepted/Kabul Tarihi:** 07.01.2019

©Copyright 2019 by Turkish Neurological Society
Turkish Journal of Neurology published by Galenos Publishing House.

ampicillin-sulbactam 2 g every 6 hours and clarithromycin 500 mg intravenous every 12 hours were started for presumed community-acquired pneumonia. Few epithelia, leukocyte, and no microorganisms were reported in bronchoalveolar lavage (BAL) Gram staining. There was no growth in BAL aerobic, anaerobic, and tuberculosis cultures. On the second day of treatment, all neurologic findings were resolved. A *Legionella* urinary antigen test was positive after one week. Antibiotherapy was continued to ten days and the patient was discharged without neurologic sequelae. After a month, the lesion in the splenium of the corpus callosum resolved completely in follow-up diffusion-weighted MRI (Figure 2B, 2C, 2D, 2E, 2F).

Legionnaires' disease is a systemic infectious disease caused by *Legionella* spp. (1). *Legionella* spp. cause community and nosocomial pneumonia. Besides pneumonia, the disease may also present with many extrapulmonary manifestations. It is very difficult for physicians to think of Legionnaires' disease in the differential diagnosis when a patient manifests with

neurologic symptoms. In this report, we aim to raise awareness of atypical presentation of Legionnaires' disease in a patient with the initial symptoms of ataxic gait, slurred speech, and urinary incontinence.

Neurologic involvement in Legionnaires' disease includes encephalitis, meningitis, peripheral nerve disease, and brain stem abnormalities. Patients may present with altered consciousness, hallucinations, delirium, and cerebellar ataxia (2). Transient corpus callosum splenium lesions have been identified in many infectious and non-infectious diseases (3). Cytotoxic corpus callosum lesions (CCCL) is a restricted diffusion pattern in the corpus callosum on MRI due to miscellaneous conditions. The corpus callosum, especially the splenium, has higher concentrations of cytokines and glutamate receptors than the other brain regions. Researchers claim that cytotoxic edema is the main mechanism related to cell-cytokine interaction in neurons and microglial cells (4). Physicians should consider Legionnaires' disease in patients in whom both pneumonic infiltration and CCCL are detected.

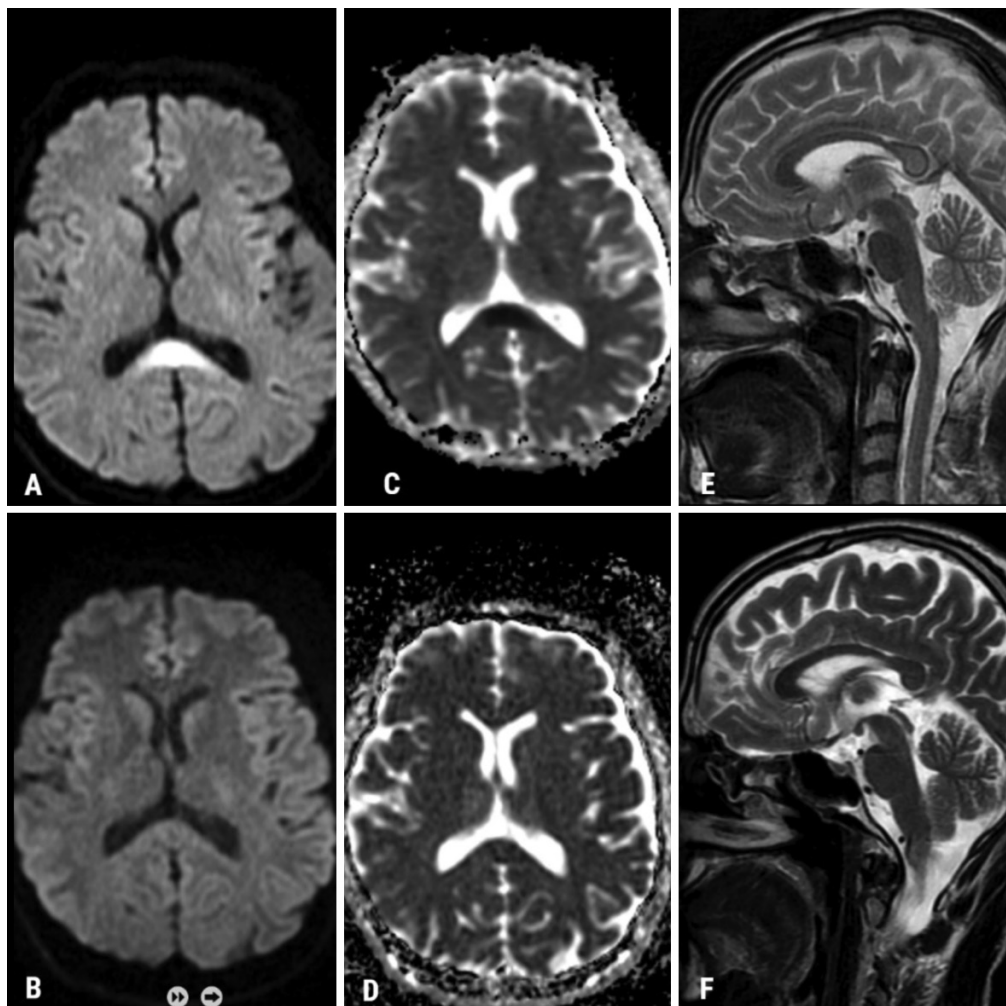


Figure 2. Diffusion restriction in the splenium of the corpus callosum is seen in axial diffusion-weighted images (A, C). There is also seen hyperintensity in the corpus callosum splenium in T2-weighted sagittal image (E). Follow-up magnetic resonance imaging performed approximately one month later shows that all findings were completely disappeared (B, D, F)

Ethics

Informed Consent: Consent form was filled out by all participants.

Peer-review: Internally peer-reviewed.

Authorship Contributions

Surgical and Medical Practices: B.I., F.A., Concept: B.I., F.A., Design: B.I., F.A., Data Collection or Processing: B.I., F.A., Analysis or Interpretation: B.I., F.A., Literature Search: B.I., F.A., Writing: B.I., F.A.

Conflict of Interest: No conflict of interest was declared by the authors.

Financial Disclosure: The authors declared that this study received no financial support.

References

1. Herwaldt LA, Marra AR. Legionella: a reemerging pathogen. *Curr Opin Infect Dis* Ağustos 2018;31:325-333.
2. Halperin JJ. Nervous System Abnormalities and Legionnaire's Disease. *Infect Dis Clin North Am* 2017;31:55-68.
3. Mild encephalitis/encephalopathy with reversible splenial lesion (MERS) in adults-a case report and literature review. Yuan J, Yang S, Wang S, Qin W, Yang L, Hu W. *BMC Neurol* 2017;17:103.
4. Starkey J, Kobayashi N, Numaguchi Y, Moritani T. Cytotoxic Lesions of the Corpus Callosum That Show Restricted Diffusion: Mechanisms, Causes, and Manifestations. *Radiogr Rev Publ Radiol Soc N Am Inc* 2017;37:562-576.