



Cerebral Venous Sinus Thrombosis Presenting as Cortical Blindness

Kortikal Körlük ile Prezente Olan Serebral Venöz Sinüs Trombozu

Harpreet Singh, Ekal Arora, Manoj Yadav, Jasminder Singh, Kiran Basavaraju, Neeraj Kumar

Pandit Bhagwat Dayal Sharma Post Graduate Institute of Medical Sciences, Department of Medicine, Rohtak, India

Keywords: Stroke, cerebral venous sinus, thrombosis, occipital infarct

Anahtar Kelimeler: İnme, serebral venöz sinüs, tromboz, oksipital infarkt

Dear Editor,

A 30-year-old male, alcoholic, smoker presented with a headache of moderate intensity, associated with multiple episodes of vomiting, which he had for the past three days. The headache was associated with bilateral vision loss that started one day ago before admission.

On examination, the patient was conscious and well oriented to time place and person. The vitals of the patient was normal. On neurologic examination, higher mental functions were intact. Ophthalmologic examination revealed that visual acuity was reduced to a perception of light bilaterally, both eyes exhibited normal pupillary reflex without movement restriction. The patient's fundus examination showed bilateral hyperaemic discs and a mildly swollen left disc (Figure 1).

Bilateral plantar reflexes were flexor, and the rest of the neurologic examination was unremarkable. The patient's routine blood parameters (hematologic and biochemical) were normal. A contrast-enhanced computed tomography scan of the brain showed a non-enhancing hypodensity in the bilateral occipital and left parieto-temporal region involving both gray and white matter not restricted to an arterial territory (1). The patient's brain magnetic resonance imaging (MRI) and MRI venography was performed, which showed acute infarct in the bilateral parieto-occipital region (Figure 2).

MRI venography revealed diffuse attenuation of flow-related enhancement of the right transverse, right sigmoid sinus, proximal part of left transverse sinus and right internal jugular vein suggestive of thrombosis (Figure 3).

Treatment with body weight-adjusted low-molecular-weight heparin (2) initially and followed later by warfarin resulted in partial recovery of vision and relief of headache. Currently, the patient is on our regular follow-up, and he has been advised against alcohol intake. Later an extensive search for any underlying hypercoagulable state (3) was performed including protein C and S level, anti-thrombin three levels, factor 5 Leiden and prothrombin gene mutations, anti-phospholipids antibodies, anti-nuclear

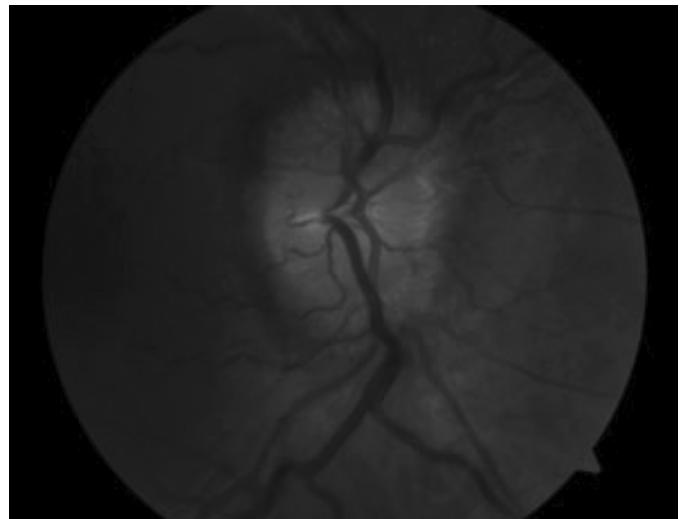


Figure 1. Fundoscopic view of the left disc revealed papilledema

Address for Correspondence/Yazışma Adresi: Harpreet Singh MD, Pandit Bhagwat Dayal Sharma Post Graduate Institute of Medical Sciences, Department of Medicine, Rohtak, India

Phone: +09991421334 E-mail: yadavmanoj49508@gmail.com ORCID ID: orcid.org/0000-0001-6971-283X

Received/Geliş Tarihi: 16.08.2017 **Accepted/Kabul Tarihi:** 01.11.2017

©Copyright 2018 by Turkish Neurological Society
Turkish Journal of Neurology published by Galenos Publishing House.

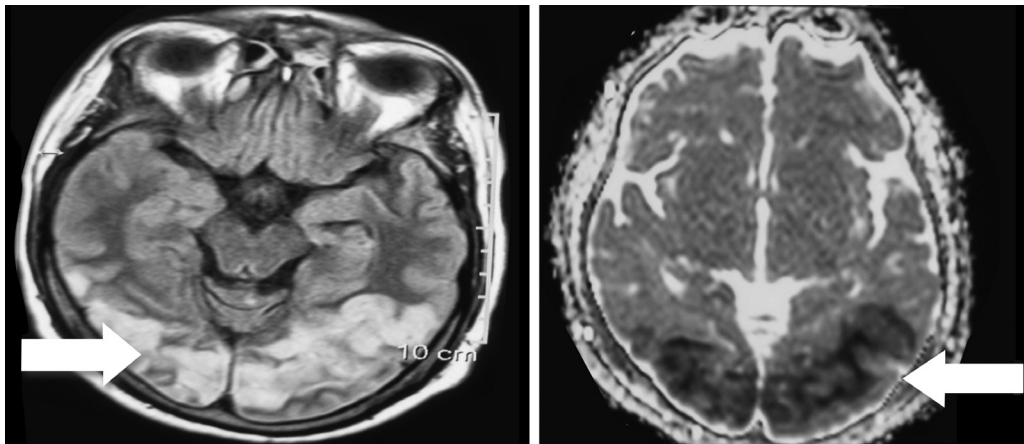


Figure 2. Brain magnetic resonance imaging showing infarct in bilateral occipital and left temporoparietal area, which is not limited to a single arterial territory

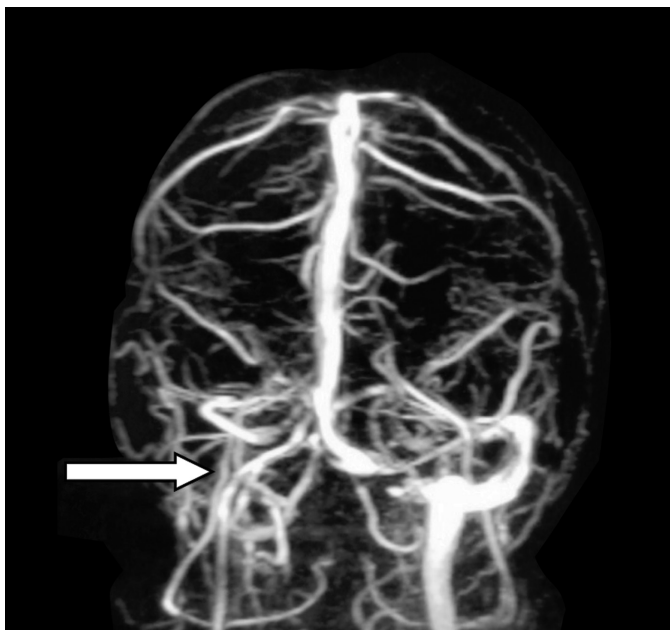


Figure 3. Magnetic resonance venography showing thrombosis of right sigmoid sinus, transverse sinus and internal jugular vein.

antibody, and serum homocysteine level, but no abnormality could be demonstrated.

Ethics

Informed Consent: Consent form was filled out by all participants.

Peer-review: Internally peer-reviewed.

Authorship Contributions

Surgical and Medical Practices: H.S., E.A., M.Y., J.S., K.B., N.K., Concept: H.S., M.Y., N.K., Design: E.A., J.S., K.B., Data Collection or Processing: H.S., M.Y., K.B., Analysis or Interpretation: H.S., E.A., N.K., Literature Search: E.A., M.Y., J.S., K.B., Writing: H.S., M.Y., J.S., N.K.

Conflict of Interest: No conflict of interest was declared by the authors.

Financial Disclosure: The authors declared that this study received no financial support.

References

1. Gerbasi FR, Bottoms S, Farag A, Mammen EF. Changes in hemostasis activity during delivery and the immediate postpartum period. *Am J Obstet Gynecol* 1990;162:1158-1163.
2. de Bruijn SF, Stam J. Randomized, placebo-controlled trial of anticoagulant treatment with low-molecular-weight heparin for cerebral sinus thrombosis. *Stroke* 1999;30:484-488.
3. Deschiens MA, Conard J, Horellou MH, Ameri A, Preter M, Chedru F, Samama MM, Bousser MG. Coagulation studies, factor V Leiden, and anticardiolipin antibodies in 40 cases of cerebral venous thrombosis. *Stroke* 1996;27:1724-1730.