



Pregnancy-induced Susac Syndrome: A Case Report

Gebeliğin Tetiklediği Susac Sendromlu Bir Olgu Sunumu

● Nuray Can Usta¹, ● Cavit Boz², ● Mehmet Özmenoğlu²

¹University of Health Sciences Trabzon Kanuni Training and Research Hospital, Clinic of Neurology, Trabzon, Turkey

²Karadeniz Technical University Faculty of Medicine, Department of Neurology, Trabzon, Turkey

Keywords: Susac syndrome, pregnancy, encephalopathy
Anahtar Kelimeler: Susac sendromu, gebelik, ensefalopati

Dear Editor,

In the 14th week of gestation, a 19-year-old female patient presented to a peripheral hospital with worsening of her symptoms of headache and meaningless somniloquy at nights. She was referred to our center after detecting extensive hyperintense lesions (most of them showing diffusion restriction) in T2 and fluid attenuated inversion recovery sections on brain magnetic resonance imaging (also including the corpus callosum) performed nearly one month after the onset of symptoms (Figure 1). The patient's presenting neurologic examination revealed impairment in orientation to place, bilateral extensor plantar response, and hyperactive deep tendon reflexes.

During follow-up her electroencephalograph findings were consistent with encephalopathy showing generalized slow (delta-theta) activity (Figure 2). Her audiogram demonstrated sensorineural hearing loss in the low frequencies. The fundus fluorescein angiography examination revealed occlusion in many branches of the central retinal artery (Figure 3). In cerebrospinal fluid, the protein level was 210 mg/dL, glucose concentration was normal, and oligoclonal band was negative.

Her symptoms were relieved after treatment with 1 g/day methylprednisolone and 300 mg/day acetylsalicylic acid for seven days. No fetal anomaly was diagnosed during follow-up.

Susac syndrome, usually seen in young females, is an angiopathy of unknown etiology that presents with various signs including ataxia, vertigo, pyramidal signs, and epileptic seizures due to extensive white and gray matter involvement. As in many

autoimmune diseases, steroids, immunosuppressive drugs, and intravenous immunoglobulin are used in the treatment of Susac syndrome (1,2,3).

Susac syndrome is less prevalent among pregnant women because immune-mediated clinical conditions are less common during pregnancy. In the literature, patients diagnosed as having Susac syndrome during pregnancy are limited in number (4,5). The first case was a 35-year-old pregnant woman presenting with acute bilateral loss of vision and the second had presented with confusion and loss of hearing and vision during pregnancy (5,6).

The fact that immune-mediated clinical conditions are less common during pregnancy makes a disease with a low incidence far less prevalent during pregnancy. For this reason, we wanted to present this case, which presented with an uncommon disease in a period when the disease is far less prevalent.

Ethics

Informed Consent: Consent forms were completed by all participants.

Peer-review: Internally peer-reviewed.

Authorship Contributions

Surgical and Medical Practices: N.C.U., C.B., M.Ö., Concept: N.C.U., C.B., M.Ö., Design: N.C.U., C.B., M.Ö., Data Collection or Processing: N.C.U., C.B., M.Ö., Analysis or Interpretation: N.C.U., C.B., M.Ö., Literature Search: N.C.U., C.B., M.Ö., Writing: N.C.U., C.B., M.Ö.

Address for Correspondence/Yazışma Adresi: Nuray Can Usta MD, University of Health Sciences, Trabzon Kanuni Training and Research Hospital, Clinic of Neurology, Trabzon, Turkey

Phone: +90 505 886 06 08 E-mail: dr.nuraycan@hotmail.com ORCID ID: orcid.org/0000-0001-9238-1194

Received/Geliş Tarihi: 12.03.2017 **Accepted/Kabul Tarihi:** 01.10.2017

©Copyright 2018 by Turkish Neurological Society
Turkish Journal of Neurology published by Galenos Publishing House.

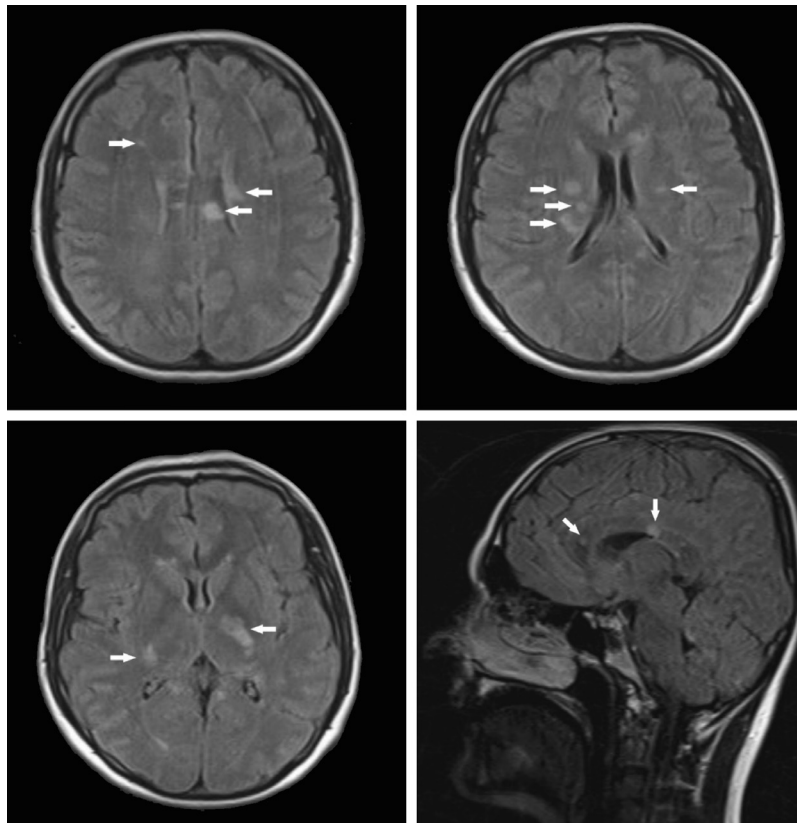


Figure 1. Periventricular (including corpus callosum) hyperintense lesions

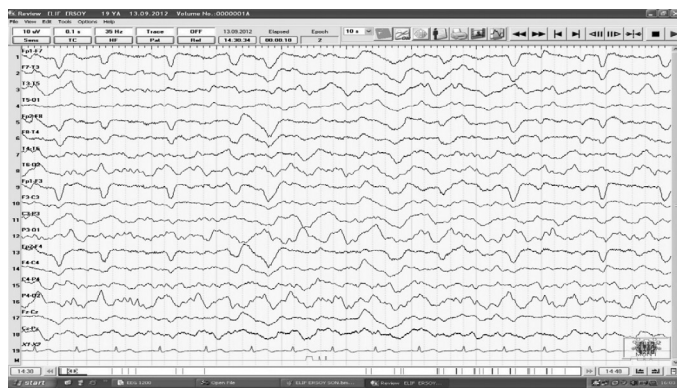


Figure 2. Diffuse slowing of the background rhythm on electroencephalograph

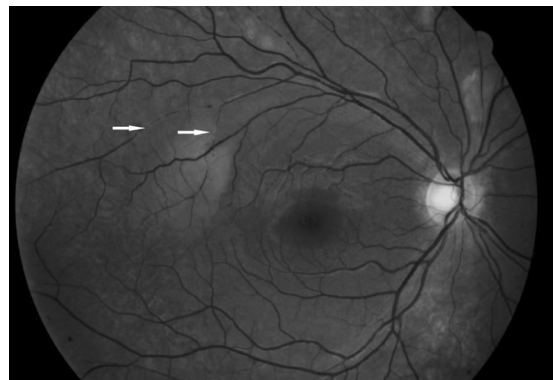


Figure 3. Central retinal artery occlusions on fundus fluorescein angiography

Conflict of Interest: No conflict of interest was declared by the authors.

Financial Disclosure: The authors declared that this study received no financial support.

References

1. Susac JO, Hardman JM, Selhorst JB. Microangiopathy of the brain and retina. *Neurology* 1979;29:313-316.
2. Rennebohm RM, Egan RA, Susac JO. Treatment of Susac's Syndrome. *Curr Treat Options Neurol* 2008;10:67-74.

3. Kleffner I, Duning T, Lohmann H, Deppe M, Basel T, Promesberger J, Dörr J, Schwint W, Ringelstein EB. A brief review of Susac syndrome. *J Neurol Sci* 2012;322:35-40.
4. Rennebohm RM, Susac JO. Treatment of Susac's syndrome. *J Neurol Sci* 2007;257:215-2520.
5. Finis D, Stammen J, Gonnermann J. [Retinal arteritis in pregnancy]. *Ophthalmologe* 2011;108:676-682.
6. Deane KD, Tyler KN, Johnson DW, Tanabe JL, Oskarrson BE, Nitka EE, Brass E, Davies JK, Striebich CC. Susac syndrome and pregnancy: disease management. *J Clin Rheumatol* 2011;17:83-88.