



Aortic Dissection Cases Presenting with Neurological Deficit

Nörolojik Bozulma ile Baş Gösteren Aort Diseksiyonu Olguları

Sibel Mumcu, Mücella Akgün, Dilek Necioğlu Örken

Şişli Hamidiye Etfal Training and Research Hospital, Department of Neurology, Istanbul, Turkey

Summary

Aortic dissection can be fatal in case of a missed diagnosis underdiagnosis, and early treatment is crucial to prevent mortality. Even though acute onset of chest or back pain is the most common presenting symptom, some patients might present with atypical findings such as acute stroke, mesenteric ischemia, renal failure or myocardial infarction. Here, we report two cases from the emergency room presenting with atypical findings of aortic dissection in which the diagnosis was made during etiologic work up for ischemic stroke. (Turkish Journal of Neurology 2014; 20:49-51)

Key Words: Aortic dissection, ischemic stroke

Özet

Aort diseksiyonu tanı konulmadığında ölümcül seyreden ve acil tedavi gerektiren bir hastalıktır. Aort diseksiyonunun en sık semptomları, ani göğüs veya sırt ağrısı olmakla birlikte bazı vakaların ağrısız olabileceği ve akut inme, mezenter iskemisi, renal yetmezlik, miyokard enfarktüsü gibi atipik bulgularla prezente olabileceği bilinmektedir. Biz, acil servise atipik semptomlarla başvuran, iskemik inme tanısı ile kliniğimizde takip edilmekte iken, etiyojolojiye yönelik yapılan tetkikler sonucunda aort diseksiyonu tanısı alan iki olguyu bildiriyoruz. (Türk Nöroloji Dergisi 2014; 20:49-51)

Anahtar Kelimeler: Aort diseksiyonu, iskemik inme

Introduction

Aortic dissection is described as the separation of tunica media with blood where the blood pools outside of lumen between the layers of aorta. Aortic dissection is sudden, powerful, piercing pain in the chest, back and abdomen. The patients can also consult with syncope, hemiparesis-hemiplegia, paraparesis-paraplegia, myocardial infarction findings, dysphagia, side pain and gastrointestinal problems. In this paper, we discuss two aortic dissection cases that were admitted to Şişli Etfal Training and Research Hospital.

Case 1

Forty six year old male patient without a history of chronic illnesses was previously taken to another center when his family failed to wake him up one morning. The records from that event indicated that he was intubated because of his unconscious state

and extubated 12 hours after. He was referred to our clinic to be seen by a neurologist and his neurological examination was seen to be normal. In his vitals, his blood pressure was 90/60 mmHg, his temperature 36.2°C, and pulse 80 rpm. Electrocardiography (ECG) was in normal sinus rhythm. There were acute infarct findings in his right cerebellar hemisphere in the magnetic resonance imaging (MRI) (Figure 1). He was started on antiaggregant treatment due to these findings. In the Doppler ultrasonography (USG), there were dissections in right brachiocephalic truncus and both carotid communis arteries (CCA), and subclavian steal syndrome in the right vertebral artery, which then prompted thoracic computerized tomography (CT) angiography (Figure 2). In the CT angiography, dissection findings along both arteria carotis interna (ICA) and CCA, as well as ascending aorta, aortic arch and descending aorta were seen (Figure 3). The patient was transferred to another center. The patient died during cardiac surgery.

Address for Correspondence/Yazışma Adresi: Sibel Mumcu MD, Şişli Hamidiye Etfal Training and Research Hospital, Department of Neurology, Istanbul, Turkey
Phone: +90 212 373 63 87 E-mail: mumcu.sibel@gmail.com

Received/Geliş Tarihi: 03.02.2013 **Accepted/Kabul Tarihi:** 06.02.2014

Case 2

A seventy-year-old woman came to our clinic with the complains of slurred speech and decreased strength on her left arm. It was learned that she came to the emergency room the day before with stomach and back pain and was given peptic ulcer treatment. Her neurology examination showed dysarthria and left hemiparesis. Her vitals were 140/80 mmHg for blood pressure, 36.8°C body temperature, and 72 rpm pulse. There was T negativity in her V1-V6 deviations in her ECG. Her MRI showed acute infarct findings on both cerebellar hemispheres and right centrum semiovale (Figure 4). After the start of the antiaggregant treatment, the patient went under CT angiography due to the subclavian steal syndrome in the right vertebral artery revealed by Doppler USG. Ascending aorta, aortic arch and descending aortic dissection findings were found (Figure 5). She was referred for cardiac surgery but she refused the surgical operation and was instead monitored with medical treatment.

Discussion

Aortic dissection is a life threatening condition characterized by sudden chest and/or back pain. The disease is twice as likely in

men than in women (1). It should be noted that aortic dissection is painless in 10%-55% of the cases (2-4). These cases may often present with stroke, coma or spinal cord ischemia, acute renal insufficiency, myocardial infarction and mesenteric system findings (5,6). The first case did not report having pain. He was monitored in an intensive care unit after being intubated and was then referred to a neurology clinic for a follow-up on his recent

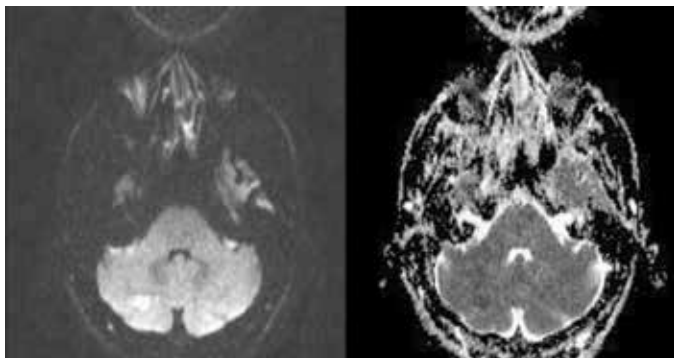


Figure 1. Diffusion obstruction compatible with acute infarction in the right cerebellar hemisphere seen in the cranial diffusion-weighted MRI of the first case

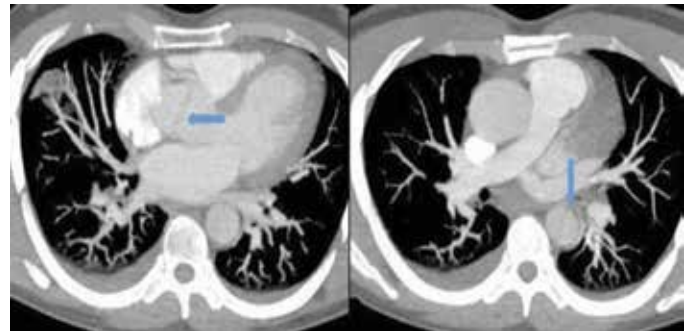


Figure 3. The dissection findings in the ascending and descending aorta seen in the first case's CT angiography

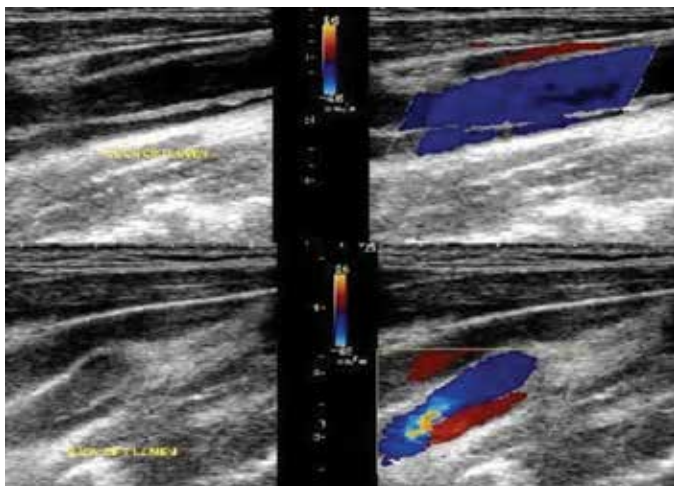


Figure 2. Carotid Doppler study of the first case showing the double-lumen in the right arteria carotis communis and arteria carotis interna

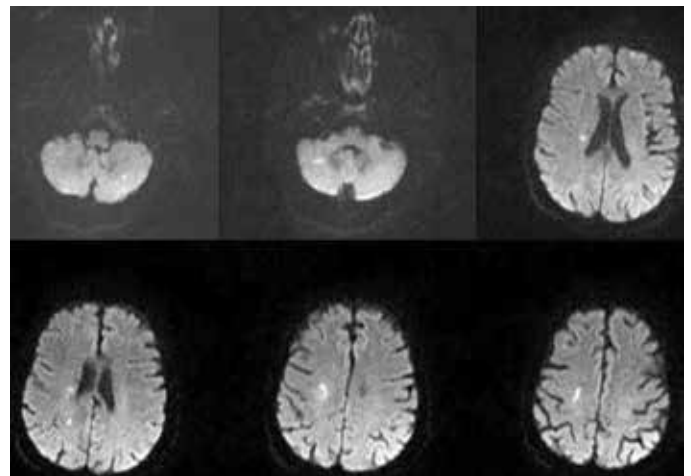


Figure 4. Diffusion obstruction in the bilateral cerebella hemisphere and right centrum semiovale that is compatible with multiple acute infarction areas seen in the diffusion-weighted MRI of the second patient

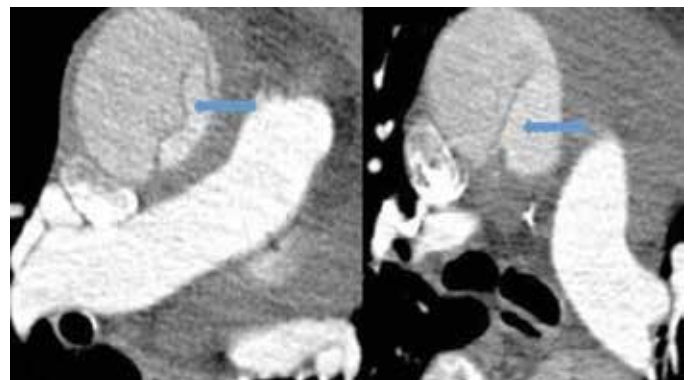


Figure 5. Aortic dissection of the second case seen in CT angiography

bout of unconsciousness, while his ongoing hypotension was not properly addressed. The second case came to emergency room with stomach pain a day before his consultation and sent home after a symptomatic treatment plan was arranged. Neither of these cases had the acute chest, back and stomach pains typically seen in aortic dissection. In both cases, BT angiography conducted upon the detection of dissection-related findings seen in the color Doppler of carotid and vertebral arteries confirmed the dissection diagnosis.

Cerebral ischemic events can be seen in 5%-10% of aortic dissection cases (2-7). We found infarctions in the right cerebellar hemisphere in the first case and infarctions on the right centrum semiovale level in the second case. The first case was lost during the surgical operation. The second case did not consent to surgery and preferred non-invasive medical treatment.

The most important factor in the diagnosis of aortic dissection is the inclusion of dissection into the diagnostic table (8). The clinical findings in our cases did not involve any of the typical clinical findings of aortic dissection. For that reason, people who come to emergency rooms with symptoms that are uncommon for aortic dissection, such as syncope, changes in consciousness, hypotension, atypical stomach pain and loss of strength in the

extremities, should be evaluated for aortic dissection as well. We wanted to draw attention to aortic dissection with these two cases.

References

1. Donovan EM, Seidel GK, Cohen A. Painless aortic dissection presenting as high paraplegia: a case report. *Arch Phys Med Rehabil* 2000;81:1436-1438.
2. Güven FMK, Korkmaz İ, Doğan Z, Döleş KA, Eren ŞH. Akut Aort Diseksiyonu: Atipik Başvurular. *Tr J Emerg Med* 2009;9:79-83.
3. Vecht RJ, Besterman EM, Bromley LL, Eastcott HH, Kenyon JR. Acute aortic dissection. *Chest* 2002;122:311-328.
4. Cohen S, Litmann D. Painless dissection aneurysm of the aorta. *N Engl J Med* 1964;271:143-145.
5. Demircan A, Aksay E, Ergin M, Bildik F, Keles A, Aygencel G. Painless aortic dissection presenting with acute ischaemic stroke and multiple organ failure. *Emerg Med Australas* 2011;23:215-216.
6. Park SW, Hutchison S, Mehta RH, Isselbacher EM, Cooper JV, Fang J, Evangelista A, Llover A, Nienaber CA, Suzuki T, Pape LA, Eagle KA, Oh JK. Association of painless acute aortic dissection with increased mortality. *Mayo Clin Proc* 2004;79:1252-1257.
7. Khan IA, Nair CK. Clinical, diagnostic, and management perspectives of aortic dissection. *Chest* 2002;122:311-328.
8. Demir FC, Artaş H. Sol Kolda Tekrarlayan Monopleji Kliniği ile Başvuran Spontan Aort Diseksiyonu Olgu Sunumu. *The Eurasian Journal of Medicine* 2007;39:151-153.