

# Posterior reversible leukoencephalopathy syndrome in children with hematologic disorders

*Hematolojik hastalığı olan çocuklarda posterior geri dönüşümlü lökoensefalopati sendromu*

Barış Malbora<sup>1</sup>, Zekai Avcı<sup>1</sup>, Fulden Dönmez<sup>2</sup>, Bülent Alioğlu<sup>1</sup>, Esra Baskın<sup>3</sup>, Füsün Alehan<sup>4</sup>, Namık Özbek<sup>1</sup>

<sup>1</sup>Department of Pediatric Hematology, Başkent University Faculty of Medicine, Ankara, Turkey

<sup>2</sup>Department of Radiology, Başkent University Faculty of Medicine, Ankara, Turkey

<sup>3</sup>Department of Pediatric Nephrology, Başkent University Faculty of Medicine, Ankara, Turkey

<sup>4</sup>Department of Pediatric Neurology, Başkent University Faculty of Medicine, Ankara, Turkey

## Abstract

**Objective:** Posterior reversible leukoencephalopathy syndrome (PRES) is characterized by headache, altered mental status, cortical blindness, and seizures associated with neuroradiological findings. It involves predominantly white matter of the parieto-occipital lobes. Several medications and disorders play a role in the etiology of PRES. In this study, we aimed to show how the prognosis of PRES in hematological diseases of childhood might be according to the etiological factors.

**Materials and Methods:** Here, we report PRES in six patients, aged 4 to 14 years, with diagnoses of leukemia and aplastic anemia.

**Results:** Suggested causes in our patients were chemotherapeutics, hypertension, infection and antimicrobial drug administration, tumor lysis syndrome, acute renal failure and hemodialysis, immunosuppressive drug administration, and hypomagnesemia. One of the patients died of sepsis, renal failure and pulmonary hemorrhage and another died of relapse after total recovery from PRES. The other four patients are under follow-up without problems.

**Conclusion:** We suggest that PRES can recover fully with early diagnosis and treatment whereas it can show poor prognosis depending on the etiology. (*Turk J Hematol 2010; 27: 168-76*)

**Key words:** Acute leukemia, aplastic anemia, posterior reversible leukoencephalopathy syndrome, tumor lysis syndrome

Received: November 6, 2009

Accepted: April 30, 2010

## Özet

**Amaç:** Posterior geri dönüşümlü lökoensefalopati sendromu (PGDLS) nöroradyolojik bulgularla birlikte baş ağrısı, bilinç değişiklikleri, kortikal körlük ve nöbet ile seyreden bir sendromdur. Hastalık ağırlıklı olarak parieto-okspital lobların beyaz cevherini tutar. Çeşitli ilaçlar ve hastalıklar PGDLS etiolojisinde

rol oynar. Bu çalışmada, çocukluk çağı hematolojik hastalıklarında altta yatan nedenlere göre PGDLS'nun nasıl seyrettiğini göstermeyi amaçladık.

**Yöntem ve Gereçler:** Burada, yaşları 4 ile 14 arasında olan, lösemi ve aplastik anemi tanıları ile izlenen PGDLS'lu 6 hastayı sunduk.

**Bulgular:** Hastalarımızda kemoterapötikler, hipertansiyon, infeksiyon, antimikrobiyal ilaç kullanımı, tümör lizis sendromu, akut böbrek yetmezliği, hemodiyaliz, immünsüpresif ilaç kullanımı ve hipomagnezemi PGDLS nedenleri olarak tespit ettik. Hastalarımızdan birini sepsis, böbrek yetmezliği ve pulmoner hemaraji nedenleriyle, bir diğerini ise PGDLS tamamen düzeldikten sonra relaps nedeniyle kaybettik. Diğer dört hastamız herhangi bir problemi olmaksızın izlenmektedir.

**Sonuç:** PGDLS erken tanı ve tedavi ile tamamen düzeltilebilir bir hastalık olmasına rağmen altta yatan nedene bağlı olarak kötü seyirli de olabilen bir sendromdur. (*Turk J Hematol 2010; 27: 168-76*)

**Anahtar kelimeler:** Akut lösemi, aplastik anemi, posterior geri dönüşümlü lökoensefalopati sendromu, tümör lizis sendromu

Geliş tarihi: 6 Kasım 2009

Kabul tarihi: 30 Nisan 2010

## Introduction

Posterior reversible leukoencephalopathy syndrome (PRES) is a disorder that typically presents with headache, nausea and vomiting, visual disturbances, a disturbed level of consciousness, seizures, and occasionally focal neurologic deficits often in the setting of accelerated hypertension [1]. The entity has become increasingly recognized over recent years, with the term PRES first being used in 1996 [1]. Some of the suspected factors in the etiology of this syndrome are sickle cell disease, severe hypertension, solid organ and bone marrow transplantation, acute renal failure, tumor lysis syndrome (TLS), immunosuppressive/cytotoxic drugs, and chemotherapeutic agents [2-5]. The pathophysiology of this complex syndrome is still unknown. In uncomplicated patients, magnetic resonance imaging (MRI) of the brain illustrates edema primarily in the cortex and subcortical white matter of posterior brain regions, such as the occipital lobes and posterior parietal lobes. These findings generally resolve with normalization of blood pressure or discontinuation of the offending drugs [6]. Although recognized to occur in pediatric patients, PRES has not been well evaluated in this age group [7]. The aim of this study was to analyze a group of pediatric patients with hematologic disorders who developed PRES. We also aimed to identify possible predisposing factors and describe the common clinical and radiographic features.

## Materials and Methods

### Patient 1

A five-year-old male had been diagnosed with T-cell acute lymphoblastic leukemia (ALL) (initial white blood cell (WBC) count:  $450 \times 10^9/L$ ), and

ALL-BFM 90 chemotherapy protocol had been started at a local center. He had been given oral low-dose steroid and intrathecal methotrexate. Although alkali hydration and oral allopurinol for TLS prophylaxis were administered, he had developed acute renal failure after administration of intravenous vincristine. Biochemical analysis at that time revealed the following values: blood urea nitrogen (BUN): 83 mg/dl (normal range, 6-21 mg/dl), creatinine: 1.27 mg/dl (normal range, 0.5-1.0 mg/dl), sodium (Na): 130 mmol/L (normal range, 135-146 mmol/L), potassium (K): 7.1 mmol/L (normal range, 3.5-5.2 mmol/L), uric acid: 5.2 mg/dl (normal range, 2.5-6 mg/dl), calcium (Ca): 6.2 mg/dl (normal range, 8.5-10.5 mg/dl), and phosphorus: 16 mg/dl (normal range, 3-6 mg/dl). He had developed TLS and was referred to our hospital for hemodialysis on the third day of chemotherapy. The physical examination at admission revealed normal blood pressure (90/60 mmHg), confusion, lethargy, and abdominal distention due to hepatomegaly. Complete blood count showed hemoglobin (Hb): 7.4 g/dl, WBC count  $40.4 \times 10^9/L$ , and platelet count:  $54 \times 10^9/L$ , and biochemical analysis revealed BUN 85 mg/dl, creatinine 1.3 mg/dl, Ca 5.6 mg/dl, phosphorus 11.9 mg/dl, uric acid 9.7 mg/dl, Na 135 mmol/L, K 4 mmol/L, total protein 5.7 g/dl (normal range, 6-8 g/dl), albumin 3.3 g/dl (normal range, 3.5-5.5 g/dl), and total cholesterol 160 mg/dl (normal range 140-200 mg/dl). For the treatment of TLS, intravenous alkali hydration, allopurinol and calcium-acetate were administered. He also had hemodialysis treatment six times until his biochemical values returned to normal. Imipenem and amikacin were started because of neutropenic fever. On the fourth day of hospitalization, vomiting, headache, focal seizures, and paresis on the right arm were observed. The physical examina-

tion revealed blood pressure 120/80 mmHg and right hemiparesis. Brain MRI disclosed bilateral hyperintense signal changes at the bilateral frontoparietal, occipital and temporal areas on fluid-attenuated inversion recovery (FLAIR) and T2-weighted images, consistent with vasogenic edema. Diffusion-weighted imaging (DWI) confirmed the presence of vasogenic edema (Figure 1a). Electroencephalogram (EEG) showed epileptiform activity in the right temporal lobe. Phenytoin was started; however, due to insistent seizures, phenobarbital was added to the treatment. On the eighth day of the treatment, the neurological findings began to regress. The follow-up MRI performed 15 days after the first seizure showed almost complete regression of the initial findings (Figure 1b). His seizures did not recur, so phenobarbital and phenytoin were stopped five and six weeks after the initiation of the antiepileptic therapy, respectively. He completed the chemotherapy protocol three years ago, and has had no problems over the last four years.

### Patient 2

A 12-year-old male had been admitted to a local center with the diagnosis of abdominal Burkitt lym-

phoma. The physical examination had revealed a mass of 10x10 cm in diameter at the upper right quadrant of the abdomen. His blood pressure was normal. Complete blood count at the time showed Hb: 9.4 g/dl, WBC count:  $14.7 \times 10^9/L$ , and platelet count:  $613 \times 10^9/L$ . Biochemical analysis was normal except for lactate dehydrogenase (LDH) (3235 U/L [normal range: 120-300 U/L]) and aspartate aminotransferase (AST) (65 U/L [normal range: 0-40 U/L]). Following the intravenous alkali hydration and oral allopurinol, he had been given intravenous cyclophosphamide. Immediately after cyclophosphamide treatment, he developed anuria and hypertension (150/100 mmHg) and tumor lysis syndrome (TLS) within 24 hours. The biochemical analysis at the time revealed BUN 53 mg/dl, creatinine 2.25 mg/dl, Ca 7.6 mg/dl, phosphorus 13 mg/dl, uric acid 8.4 mg/dl, Na 131 mmol/L, K 3.5 mmol/L, total protein 5.9 g/dl, and albumin 3.2 g/dl. After administration of captopril and furosemide, the patient was referred to our hospital for hemodialysis treatment. At admission, his blood pressure was 145/95 mmHg. The complete blood count revealed Hb 9.1 g/dl, WBC count  $13.3 \times 10^9/L$  and platelet count  $683 \times 10^9/L$ .

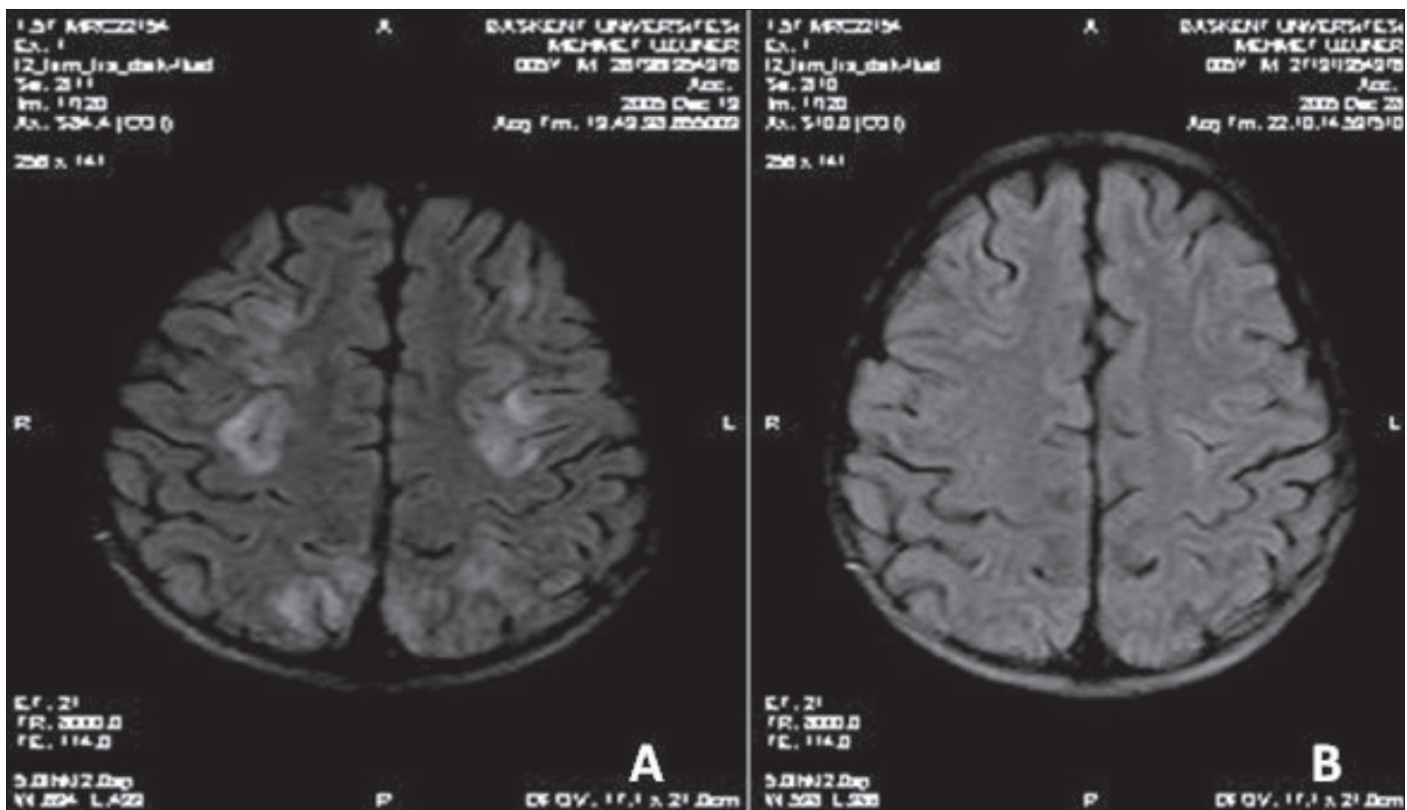


Figure 1. There are hyperintensities on both frontal and parietal white matter, consistent with vasogenic edema on initial axial FLAIR image (A). There are also similar signal changes in temporal lobes (not shown). On follow-up MRI, the FLAIR image shows regression of the edema at the frontal and parietal lobes (B)

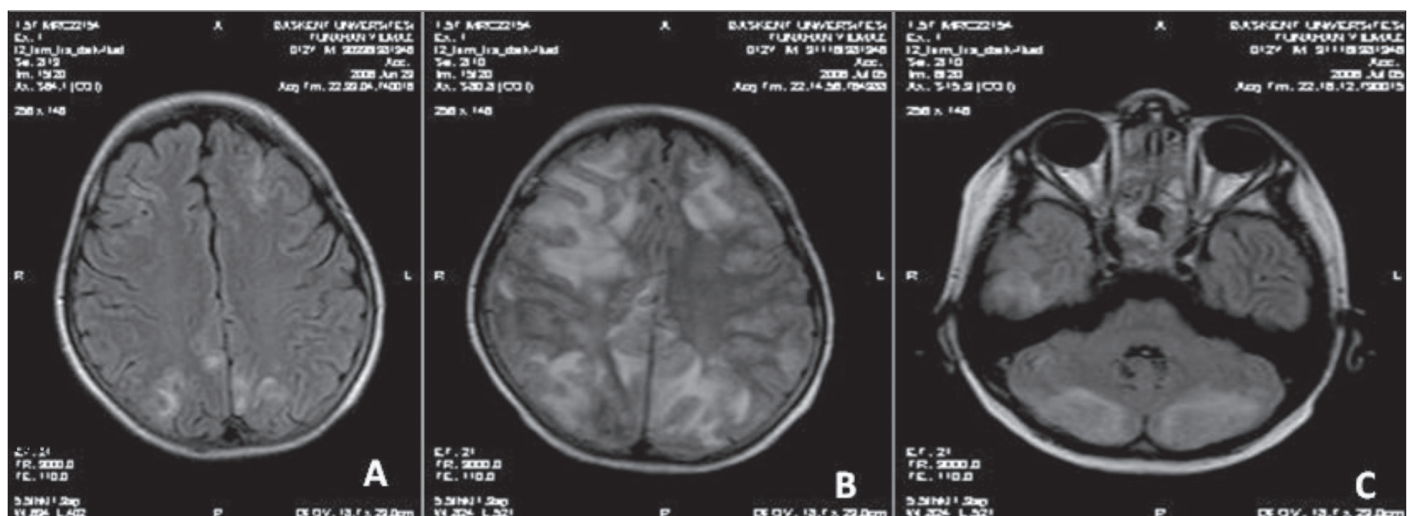


Biochemical analysis showed BUN 23 mg/dl, creatinine 3.73 mg/dl, Na 135 mmol/L, K 3.5 mmol/L, uric acid 1.3 mg/dl, Ca 8.7 mg/dl, phosphorus: 4.1 mg/dl, magnesium (Mg) 1.5 mg/dl, total protein: 5.7 g/dl, albumin: 2.9 g/dl, AST 25 U/L, alanine aminotransferase (ALT) 10 U/L, and LDH: 693 U/L. Amlodipine was added to the anti-hypertensive therapy due to persisting high blood pressure. Renal function had partially improved. He received hemodialysis treatment 12 times over 20 days, and his NHL BFM 90 course AA protocol (doses adjusted for creatinine clearance) was started due to the enlargement of the abdominal mass. At the time, he developed febrile neutropenia and intravenous broad-spectrum antibiotics (cefepime and amikacin) were started. On the second day of the antibiotic treatment, generalized tonic-clonic seizure and lateral deviation on the left eye were observed. His general status was poor on his physical examination with continuing high blood pressure. He had hyperreactive deep tendon reflexes (DTR) with additional clonus on his right lower extremity. His biochemical analysis disclosed the following values: BUN: 41 mg/dl, creatinine: 1.97 mg/dl, Mg: 0.9 mg/dl (normal range, 1.6-3 mg/dl), albumin: 2.9 mg/dl, Na: 132 mmol/L, K: 3.9 mmol/L, Ca: 9.4 mg/dl, phosphorus: 3 mg/dl, AST: 27 U/L, ALT: 16 U/L, and total cholesterol: 162 mg/dl. Brain MRI showed bilateral patchy increase in signal intensity of the cortical and subcortical areas on the parietal and frontal lobes on FLAIR images (Figure 2a). Dexamethasone and phenytoin were started for his convulsions. Due to persistent seizures, valproic acid was added to the

treatment; however, the seizures were refractory to both agents so additional midazolam and thiopental infusions were started. The brain MRI performed one week later showed progressive findings on FLAIR and T2-weighted images. Although the lesions were increased in distribution, no evidence of cytotoxic edema was found on DWI (Figure 2b, 2c). Twenty days after beginning anti-epileptic therapy, the patient died due to sepsis, renal failure and pulmonary hemorrhage.

### Patient 3

A 10-year-old male had been admitted to a local center with polyuria and swelling of the eyelids. Blood pressure had been measured as 130/90 mmHg on physical examination. Complete blood count had shown Hb: 10.6 g/dl, WBC count:  $43.2 \times 10^9/L$ , and platelet count:  $89 \times 10^9/L$  with 65% blasts on peripheral blood smear. Diffuse L-3 type blastic infiltration was present on bone marrow smear and biopsy. Biochemical analysis had shown BUN: 49.7 mg/dl, creatinine: 1.4 mg/dl, uric acid: 15.6 mg/dl, total protein: 6.1 g/dl, albumin: 3.8 g/dl, ALT: 99 U/L, AST: 129 U/L, Na: 133 mmol/L, K: 4.1 mmol/L, Ca: 9.3 mg/dl, phosphorus: 3.1 mg/dl, and Mg: 2.1 mg/dl. With these findings, the patient had been diagnosed with ALL and acute renal failure due to TLS. Alkali hydration, allopurinol and low-dose dexamethasone (0.5 mg/d) were administered. Despite this therapy, the patient's WBC count had increased, and blood pressure had risen, and he developed dyspnea secondary to hypervolemia and impaired renal functions. The patient was then



**Figure 2.** Axial initial FLAIR image shows mild signal increase on the frontal and parietal lobes (A). On follow-up MRI, FLAIR images show severe progression of the lesions on bilateral frontal, parietal and temporal lobes and new lesions are seen on bilateral cerebellar hemispheres (B,C)

referred to our hospital for hemodialysis. The biochemical analysis at that time revealed BUN: 31 mg/dl, creatinine: 2.75 mg/dl, uric acid: 9.5 mg/dl, total protein: 6.1 g/dl, albumin: 3.3 g/dl, ALT: 30 U/L, AST: 61 U/L, Na: 128 mmol/L, K: 3.2 mmol/L, Ca: 8.1 mg/dl, phosphorus: 8.5 mg/dl, Mg: 1.5 mg/dl, and LDH 3080 U/L. Low-dose dexamethasone (1 mg/d) and allopurinol were started. He received hemodialysis treatment 4 times over 4 days. After hemodialysis, the patient's blood pressure levels normalized. He was given NHL BFM 95 prephase block and immediately after the prephase, Course AA block was started. On the third day of his chemotherapy, he developed visual disturbance, headache and vomiting before etoposide and cytarabine treatment. At the time, his blood pressure was 150/95 mmHg. Six hours later he had generalized tonic-clonic seizures. On MRI, FLAIR images showed diffuse signal increase in the cortex and subcortical white matter of the bilateral frontal, parietal and temporal lobes, and also in bilateral cerebellar hemispheres, which was demonstrated as vasogenic edema on DWI. Serum methotrexate level (42<sup>nd</sup> hour of methotrexate infusion) was 2.4  $\mu$ mol/L. EEG was normal. Chemotherapy was stopped and phenytoin was given. Fifteen days after PRES, the patient had no neurological problems and his chemotherapy was re-started. MRI performed two months after the diagnosis showed disappearance of all of the lesions; no evidence of signal changes was found. Three months after PRES, phenytoin dose was decreased gradually and then stopped.

#### **Patient 4**

A 14-year-old girl had been diagnosed with AML-M2 at a local center. AIE block of AML BFM 93 treatment protocol including cytosine arabinoside, idarubicin and etoposide had been started. Due to febrile neutropenia and invasive pulmonary aspergillosis, voriconazole, meropenem and metronidazole had been administered. She had developed visual disturbance and weakness in both lower extremities, in addition to cerebellar findings (hypometria, incompetency in knee-toe test). She developed generalized convulsions three times after cerebellar findings. The patient had been normotensive during this period. At the time, Hb was 9.2 g/dl, WBC count was 0.82x10<sup>9</sup>/L and platelet count was 21.0x10<sup>9</sup>/L; the biochemical analysis showed total cholesterol of 88 mg/dl, Ca 6.9 mg/dl and albu-

min 2.2 g/dl. The patient was referred to our hospital with these findings for intensive care. Brain MRI revealed symmetrical hyperintensities in the bilateral thalami and frontal lobes on FLAIR and T2-weighted sequence. As this kind of localization is rare, she was diagnosed as atypical PRES. Her EEG was normal. Phenytoin was started initially; however, due to persistent convulsions, phenobarbital was added. From the 10<sup>th</sup> day of the anti-epileptic treatment, neurologic symptoms started to improve and at the end of the second week, the symptoms had totally regressed. One month later, the follow-up MRI showed marked regression of the lesions. The neurologic symptoms and the invasive fungal infection had regressed, so the chemotherapy protocol was continued. Anti-epileptic treatment was stopped at the 4<sup>th</sup> month. Her chemotherapy was completed and she has been in remission for the last six months.

#### **Patient 5**

A four-year-old male was given St. Jude Total XIII I/H risk chemotherapy protocol with the diagnosis of Pre-B ALL. On the 15<sup>th</sup> day of induction therapy, vincristine, prednisolone, daunorubicin, and L-asparaginase were administered. Seven days after this treatment, generalized tonic-clonic seizure had occurred. The patient was monitored with mechanical ventilation because of status epilepticus. The physical examination revealed blood pressure of 125/95 mmHg. His Hb was 8.7 g/dl, WBC count 3.2x10<sup>9</sup>/L and platelet count 112x10<sup>9</sup>/L; the biochemical analysis was normal. On cranial MRI, there were asymmetric cortico-subcortical hyperintense signal changes at bilateral occipital and parietal areas on FLAIR images. DWI also showed vasogenic edema. EEG revealed bilateral temporal irregular background activity. The chemotherapy protocol was stopped and carbamazepine was administered. On the 7<sup>th</sup> day of the anti-epileptic treatment, the neurological symptoms recovered. Two months after the anti-epileptic treatment, follow-up cranial MRI revealed that the lesions had totally regressed. His seizures did not recur, so the anti-epileptic treatment was stopped and the chemotherapy was continued. At the 93<sup>rd</sup> week of the maintenance chemotherapy, he developed a bone marrow relapse. During the administration of relapse protocol, he died of sepsis.

### Patient 6

A 13-year-old girl had received a treatment protocol consisting of anti-thymocyte globulin, cyclosporine, danazol, prednisolone, and filgrastim for severe acquired aplastic anemia. During the 2<sup>nd</sup> month of the treatment, headache, contractions of the right arm and staring at a point had developed. Physical examination revealed blood pressure of 140/85 mmHg and DTR were hyperactive. Complete blood count showed Hb: 7.38 g/dl, WBC count:  $7.2 \times 10^9/L$  and platelet count:  $149 \times 10^9/L$ . Biochemical analysis revealed BUN 21 mg/dl, creatinine 0.49 mg/dl, Ca 8.5 mg/dl, Na 132 mmol/L, K 4.4 mmol/L, AST 30 U/L, ALT 188 U/L, gamma-glutamyl transpeptidase (GGT) 34 U/L, alkaline phosphatase (ALP) 217 U/L, total cholesterol 186 mg/dl, and Mg 1.5 mg/dl. Brain MRI showed hyperintense signal changes on the posterior-inferior part of the right cerebellar hemisphere and right parietal subcortical white matter at the level of the vertex on FLAIR and T2-weighted sequences, which were confirmed to be vasogenic edema on DWI. During this period, the serum level of cyclosporine was found to be high (530 ng/ml; normal range: 100-400 ng/ml) and it was then stopped. Phenytoin was started for the convulsions and following the treatment, there was no convulsion recurrence. The brain MRI performed five months after anti-epileptic treatment showed that edema had regressed; however, hemorrhage was observed in the subcortical white matter of the bilateral frontal lobes and right posterior parietal and left occipital lobes on gradient-echo images. The control EEG was normal. During the follow up, phenytoin treatment was stopped after one year. The patient has been in partial remission for the last three years.

### Results and Discussion

Various factors have been defined in the etiology of PRES. The most common factors are immunosuppressive drugs (cyclosporine, anti-thymocyte globulin, tacrolimus, rituximab, interferon), and chemotherapeutic agents (methotrexate, L-asparaginase, adriamycin, cyclophosphamide, cytosine arabinoside, vincristine) [2,4,7,8-11]. Sickle cell disease, hypertension, acute blood pressure changes, renal failure, TLS, infection, sepsis, shock, and organ transplantation are some factors that can also cause PRES [3,5,12-15]. The exact etiopathogenesis of posterior leukoencephalopathy syn-

drome is still unknown. Two opposing hypotheses are commonly cited, but the issue is controversial. The more popular theory suggests that severe hypertension exceeds the limits of autoregulation, with injury to the capillary bed and hyperperfusion leading to breakthrough brain edema [16]. Another theory suggests that hypertension leads to cerebral autoregulatory vasoconstriction, ischemia and subsequent cytotoxic edema and then extracellular edema [1,17].

On computerized tomography (CT)/MRI, the brain typically demonstrates focal regions of symmetric hemispheric edema. The parietal and occipital lobes are most commonly affected, followed by the frontal lobes, the inferior temporal-occipital junction and the cerebellum [10]. Lesion confluence may develop as the extent of edema increases. DWI was instrumental in establishing and consistently demonstrating that the areas of abnormality represent vasogenic edema [18]. Focal/patchy areas of PRES vasogenic edema may also be seen in the basal ganglia, brain stem, and deep white matter [18-20]. In our patients, frontal lobe (n=4), parietal lobe (n=5), occipital lobe (n=4), temporal lobe (n=2), cerebellum (n=2), and thalamus (n=1) were involved. (Table 1) The above-mentioned abnormalities were bilaterally symmetric in five patients (not in Case 6). Research indicates that imaging abnormalities in posterior leukoencephalopathy syndromes are often symmetrical; however, asymmetrical involvement is not unusual [1,10].

In our patients, chemotherapeutics (n=5), hypertension (n=5), infection and antimicrobial drug administration (n=3), acute renal failure and hemodialysis with TLS (n=3), and immunosuppressive drug administration and hypomagnesemia (n=1) were suggested to be the causes of PRES (Table 2). The blood pressures according to age, sex and height of all our patients were high in our patient group with the exception of Case 4. PRES may also develop and reverse in the face of systemic toxicity but in the absence of hypertension. In 20-30% of patients who develop PRES, blood pressure is essentially normal at toxicity [8]. The blood pressure of Case 4 was in normal ranges. In this patient, intravenous and intrathecal cytosine arabinoside, idarubicin, etoposide, and antibiotics for the treatment of febrile neutropenia may have been the causative factors for PRES.

Infection and/or inflammation are some other factors accused in the pathogenesis of PRES. The

**Table 1. Distribution of lesions with regard to the brain lobes on initial and follow-up magnetic resonance imagings**

Case	Parietal	Occipital	Frontal	Temporal	Cerebellar	Talamus	Control MRI
1	Bilateral	Bilateral	Bilateral	Bilateral	N	N	Regression
2	Bilateral	Bilateral	Bilateral	N	N	N	No regression
3	Bilateral	Bilateral	Bilateral	Bilateral	Bilateral	N	N
4	N	N	Bilateral	N	N	Bilateral	N
5	Bilateral asymmetric	Bilateral asymmetric	N	N	N	N	N
6	Right	N	N	N	Right	N	Regression (New hemorrhagic areas)

MRI: magnetic resonance imaging; N: normal

**Table 2. Demographic and clinical data for the 6 patients of posterior leukoencephalopathy syndrome**

Case	Age (Year)	Sex	Disease	Medication	Mean arterial BP syst/diast (mmHg)	TLS	Infection	EEG	Treatment	Signs and symptoms	Outcome
1	5	M	T-ALL	Prednisolone Vincristin, MTX (I.T.) Allopurinol Ca-asetat, Imipenem Amicasin	125/85*	+	+	AN	Phenytoin	Vomiting Headache Focal seizure Paresis on the right arm	Remission without neurologic sequel
2	12	M	Burkitt lymphoma	Prednisolone Cytarabine, Ifosfamid, Etoposid, Cefepime, Amikacin, Amlodipine, Captopril, Allopurinol	150/100*	+	+	NA	Phenytoin Dexamethasone Valproic acid Midazolam Thiopental	GTC Lateral deviation on the left eye Hyperactive DTR Clonus on right lower extremity	Died due to sepsis, renal failure and pulmonary hemorrhage
3	10	M	ALL L-3	Dexametasone, Ifosfamid, Vincristin MTX, MTX (IT), Cytarabine (IT), Prednisolone (IT)	150/95*	+	-	N	Phenytoin	Vomiting Headache GTC	Chemotherapy continues without neurologic sequel
4	14	F	AML	Cytarabine Idarubicin, Etoposid, Meropenem, Metronidazole, Voriconazole	100/60	-	+	N	Phenytoin Phenobarbital	Visual disturbance Hypometry, Incompetency in knee-toe test GTC	Remission without neurologic sequel
5	4	M	Pre-B ALL	Prednisolone, Vincristin, Daunorubicin, L-asparaginase	125/95*	-	-	AN	Carbamazepine	GTC	Died due to sepsis
6	13	F	Aplastic anemia	Cyclosporin, ATG, G-CSF, Danazol, Prednisolone	140/85*	-	-	N	Phenytoin	Headache, Contractions at the right arm, Staring to a point, Hyperactive, DTR	Partially remission without neurologic sequel

M: male; F: female; ALL: Acute lymphoblastic leukemia; AML: Acute myeloblastic leucemia; ATG: antitumocyte globulin; BP: blood pressure; Ca: calcium; DTR: deep tendon reflex; EEG: electroencephalogram; G-CSF: granulocyte- colony stimulating factor; GTC: generalized tonic-clonic convulsions; IT: intrathecal; NA: non available; AN: abnormal; N: normal; MTX: methotrexate; TLS: tumor lysis syndrome

\* Increased blood pressure according to age, sex and height



septic shock response likely reflects systemic toxicity similar to systemic inflammatory response syndrome or multiorgan dysfunction syndrome and bacteremia, or endotoxins/exotoxins are considered as potential triggers [21,22]. Cytokine response (tumor necrosis factor [TNF]- $\alpha$ , interleukin [IL]-1) plays a critical role in development of this effect [23]. Gram-positive organisms are commonly obtained in infection/sepsis/shock-associated PRES [14]. In our study, three of our patients had infection. Case 4 was in febrile neutropenia, receiving antibiotics and antifungals after the treatment, when she developed neurologic findings. However, during this period, all the cultures were negative.

An alternative mechanism of PRES also implicates endothelial dysfunction, such a notion underpinning the treatment of affected individuals with immunosuppressive therapy, mainly cyclosporine [1]. Immunosuppressive agents could damage the blood-brain barrier by various means: direct toxic effects on the vascular endothelium, vasoconstriction caused by elaboration of endothelin and microthrombosis [1]. The situation for bone marrow transplant recipients who feature cyclosporine neurotoxicity may be related to abnormalities of the blood-brain barrier, increased blood pressure and renal failure prior to the onset of various neurological symptoms [13]. Under most circumstances, the neurological symptoms and signs associated with cyclosporine use are reversible when the drug's administered dosage is decreased or stopped, but symptoms may recur when the drug is reintroduced. Although neurotoxicity appears to be more frequent when blood cyclosporine levels are substantially elevated, neurotoxicity may also occur when the drug is administered within the normal therapeutic range [1]. Hypocholesterolemia and hypomagnesemia are found in more than 50% of patients with cyclosporine neurotoxicity [2]. The steroids administered simultaneously with cyclosporine can also aggravate the neurologic complications of cyclosporine [9]. In Case 6, blood cyclosporine level (530 ng/ml) was only marginally above the recommended normal range (200-400 ng/ml). This patient also had a low magnesium level (1.5 mg/dl); however, the cholesterol level was normal. Additionally, this patient was receiving both prednisolone and cyclosporine, and both may have contributed to PRES.

There are reports on the development of PRES in patients with TLS. TLS causes hypertension and

various electrolyte imbalances, which result in PRES. Recent literature reports PRES patients secondary to TLS, seen after chemotherapy administration for hematologic malignancies, similar to our patients (Cases 1, 2, and 3) [3,10,11].

In summary, PRES is a multi-factorial syndrome. As in our patients, one or more factors such as TLS, chemotherapeutics, immunosuppressive drugs, and sepsis may cause PRES. This syndrome usually improves without any complications. However, it may progress to irreversible neurologic deficits, even death, depending on the severity of the primary disease and delays in diagnosis and treatment.

#### Acknowledgement

Oral and written informed consent was taken from the parents. This study conforms to the principles outlined in the Declaration of Helsinki (1975) and later revisions, and was approved by Ethical Committee of Baskent University Faculty of Medicine, Ankara, Turkey.

#### Conflict of interest

No author of this paper has a conflict of interest, including specific financial interests, relationships, and/or affiliations relevant to the subject matter or materials included in this manuscript.

#### References

1. Hinchey J, Chaves C, Appignanin B, Breen J, Pao L, Wang A, Pessin MS, Lamy C, Mas JL, Caplan LR. A reversible posterior leukoencephalopathy. *N Engl J Med* 1996; 334: 494-500.
2. Gupta A, Swaroop C, Rastogi R, Garg R, Bakhshi S. Simultaneous occurrence of posterior reversible leukoencephalopathy syndrome in two cases of childhood acute lymphoblastic leukemia induction chemotherapy. *Pediatr Hematol Oncol* 2008;25:351-8.
3. Ozkan A, Hakyemez B, Ozkalemkas F, Ali R, Ozkocaman V, Ozcelik T, Taskapilioglu O, Altundal Y, Tunali A. Tumor lysis syndrome as a contributory factor to the development of reversible posterior leukoencephalopathy. *Neuroradiology* 2006;48:887-92.
4. Saito B, Nakamaki T, Nakashima H, Usui T, Hattori N, Kawakami K, Tomoyasu S. Reversible posterior leukoencephalopathy syndrome after repeat intermediate-dose cytarabine chemotherapy in a patient with acute myeloid leukemia. *Am J Hematol* 2007;82:304-6.
5. Frye RE. Reversible posterior leukoencephalopathy syndrome in sickle-cell anemia. *Pediatr Neurol* 2009;40:298-301.
6. Pavlakis SG, Frank Y, Chusid R. Hypertensive encephalopathy, reversible occipitoparietal encephalopathy, or



- reversible posterior leukoencephalopathy: three names for an old syndrome. *J Child Neurol* 1999;14:277-81.
7. Suminoe A, Matsuzaki A, Kira R, Fukunaga N, Nishio T, Hoshina T, Hara T. Reversible posterior leukoencephalopathy syndrome in children with cancers. *J Pediatr Hematol Oncol* 2003;25:236-9.
  8. Bartynski WS, Zeigler Z, Spearman MP, Lin L, Shaddock RK, Lister J. Etiology of cortical and white matter lesions in cyclosporin-A and FK-506 neurotoxicity. *AJNR Am J Neuroradiol* 2001;22:1901-14.
  9. Durrant S, Chipping PM, Palmer S, Gordon-Smith EC. Cyclosporin A, methylprednisolone, and convulsions. *Lancet* 1982;2:829-30.
  10. Lee VH, Wijdicks EM, Manno EM, Rabinstein AA. Clinical spectrum of reversible posterior leukoencephalopathy syndrome. *Arch Neurol* 2008;65:205-10.
  11. Honkaniemi J, Kahara V, Dastidar P, Latvala M, Hietaharju A, Salonen T, Keskinen L, Ollikainen J, Vähämäki L, Kellokumpu-Lehtinen P, Frey H. Reversible posterior leukoencephalopathy after combination chemotherapy. *Neuroradiology* 2000;42:895-9.
  12. Servillo G, Bifulco F, De Robertis E, Piazza O, Striano P, Tortora F, Striano S, Tufano R. Posterior reversible encephalopathy syndrome in intensive care medicine. *Intensive Care Med* 2007;33:230-6.
  13. Sloane JP, Lwin KY, Gore ME, Powles RL, Smith JF. Disturbance of blood-brain barrier after bone marrow transplantation. *Lancet* 1985;2:280-1.
  14. Bartynski WS, Boardman JF, Zeigler ZR, Shaddock RK, Lister J. Posterior reversible encephalopathy syndrome in infection, sepsis, and shock. *AJNR Am J Neuroradiol* 2006;27:2179-90.
  15. Alehan F, Erol I, Agildere AM, Ozcay F, Baskin E, Cengiz N, Alioglu B, Haberal M. Posterior leukoencephalopathy syndrome in children and adolescents. *J Child Neurol* 2007;22:406-13.
  16. Schwartz RB, Jones KM, Kalina P, Bajakian RL, Mantello MT, Garada B, Holman BL. Hypertensive encephalopathy: findings on CT, MR imaging, and SPECT imaging in 14 cases. *AJR Am J Roentgenol* 1992;159:379-83.
  17. Bartynski WS. Posterior reversible encephalopathy syndrome, part 2: controversies surrounding pathophysiology of vasogenic edema. *AJNR Am J Neuroradiol* 2008;29:1043-9.
  18. Covarrubias DJ, Luetmer PH, Campeau NG. Posterior reversible encephalopathy syndrome: prognostic utility of quantitative diffusion-weighted MR images. *AJNR Am J Neuroradiol* 2002;23:1038-48.
  19. Oliverio PJ, Restrepo L, Mitchell SA, Tornatore CS, Frankel SR. Reversible tacrolimus-induced neurotoxicity isolated to the brain stem. *AJNR Am J Neuroradiol* 2000;21:1251-4.
  20. Casey SO, Truwit CL. Pontine reversible edema: a newly recognized imaging variant of hypertensive encephalopathy? *AJNR Am J Neuroradiol* 2000;21:243-5.
  21. Munford RS. Sepsis, severe sepsis and septic shock. In: Mandell GL, Bennett JE, Dolin R, eds. *Principles and Practice of Infectious Disease*. 6th ed. Philadelphia: Elsevier Churchill Livingstone, 2005:906-26.
  22. Varon J, Marik PE. Multiple organ dysfunction syndrome. In: Irwin RS, Rippe JM, eds. *Irwin and Rippe's Intensive Care Medicine*. 5th ed. Philadelphia: Lippincott-Williams & Wilkins, 2003:1834-8.
  23. McGuire TR, Bociek GR, Pavletic SZ, Hock L, Lynch J, Schneider J, Hoie EB, Tarantolo S, Haire WD. Organ dysfunction following stem cell transplantation: relationship to plasma cytokine concentrations. *Bone Marrow Transplant* 2001;28:889-93.