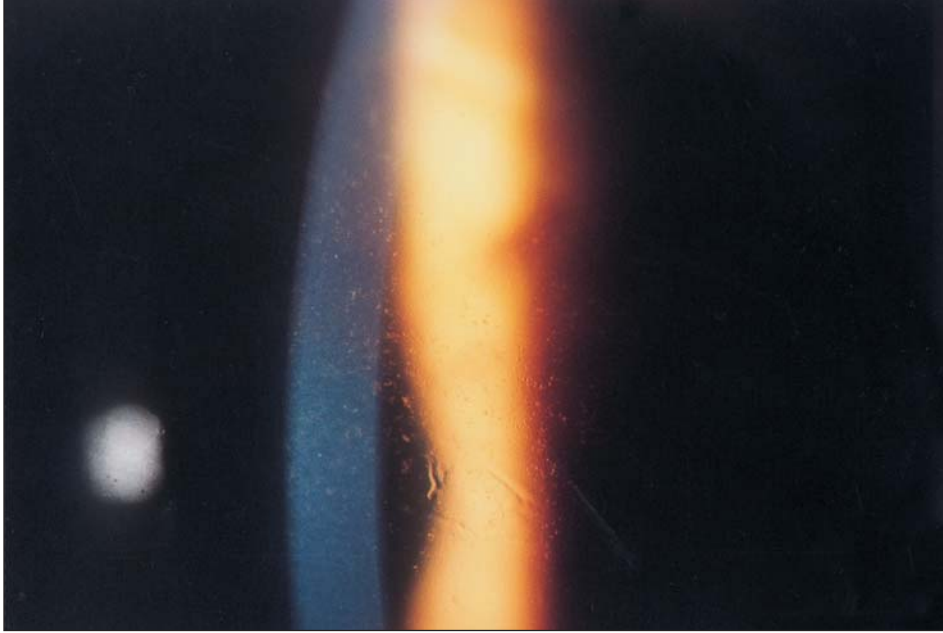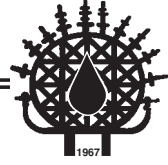


# Images in Haematology

Edited by: Hamdi Akan M.D.



A 32 years old woman with acute myelogenous leukemia in remission received high-dose intravenous cytarabine (HIDAC; 2 g/m<sup>2</sup>/every 12 hours for 12 doses). In spite of the prophylactic use of steroid eye drops, she developed photophobia. Keratitis (punctate epithelial erosions) was detected by biomicroscopy. Topical corticosteroids, however significantly reduced both the intensity and duration of ARA-C induced signs and symptoms of corneal toxicity.

**Naci TİFTİK, Kaan ÜNLÜ, Orhan AYYILDIZ,  
Ekrem MÜFTÜOĞLU**

Departments of Haematology and Oncology  
Medical School, University of Dicle  
21280, Diyarbakır, TURKEY

Answer to the question in Vol 18 No1 was “extramedullary hematopoiesis presenting as a posterior mediastinal mass in a patient with thalassemia major”.