
Griscelli's Syndrome: Clinical and Immunological Features of Two Siblings

Türkan PATIROĐLU*, Mehmet Akif ÖZDEMİR*, Tahir Ercan PATIROĐLU**

* Department of Pediatrics, Medical School, Erciyes University,

** Department of Pathology, Medical School, Erciyes University, Kayseri, TURKEY

ABSTRACT

Two siblings diagnosed with Griscelli's syndrome (GS) are presented. The clinical features were partial albinism, silvery hair and absence of giant granules in the white blood cells. The diagnosis of GS was confirmed at the ages of nine months and two months by the demonstration of irregular clumps of pigment in the hair shaft, a finding characteristic of this syndrome. The patients had hepatosplenomegaly and bone marrow examinations revealed lymphohistiocytosis. Immunological studies revealed normal serum immunoglobulin levels and normal T and B lymphocyte counts. Skin tests were positive for phytohemagglutinin and PPD in the first patient. Phagocytosis was studied by flow cytometry using Mo Ab (DCFH, PMA oxidative burst, Coulter) in the second sibling and it was found as normal. Splenectomy was performed in the second sibling because of excessive splenomegaly at the age of six months but she died two months later. The first sibling died at the age of 18 months because of infection. Postmortem examination of the siblings revealed lymphohistiocytosis in the liver and spleen.

Key Words: Griscelli's Syndrome, Immunodeficiency, Albinism, Lymphohistiocytosis

Turk J Haematol 2000;17(2):85-87.

A syndrome was described by Griscelli et al in 1978^[1]. The clinical features were partial albinism and immunodeficiency. Patients have silvery hair, large pigment agglomerations in hair shafts and an abundance of mature melanosomes in melanocytes with reduced pigmentation of adjacent keratinocytes and absence of giant granules in the white blood cells^[2-4]. Immunologic abnormalities most often include impaired natural killer cell activity, absent delayed-type hypersensitivity and impaired responses to mitogens. Impaired helper

T cell function and hypogammaglobulinemia have also been described^[5,6]. Patients may develop progressive neurological deterioration and lymphohistiocytosis and usually die of these complications^[4,7,8].

We present two siblings with Griscelli's syndrome diagnosed in our hospital because of extreme rarity.

CASE 1

A 12-month-old boy was admitted to the Department of Pediatric Hematology at Erciyes University Medical Faculty because of abdominal distention and fever. The parents of the patient were first cousins. Physical examination revealed silvery hair and hepatosplenomegaly (Figure 1). He had a moderate anemia and thrombocytopenia. The pathognomonic granules of Chediak-Higashi syndrome were not observed in peripheral blood smear. Serum immunoglobulin levels and T-cell numbers were also within normal limits. Delayed type skin sensitivity tests were positive with phytohemagglutinin and PPD. The chemotactic response and result of nitroblue tetrazolium (NBT) test were normal. Examination of the hair under light microscopy revealed irregular clumps of pigment in the hair shaft (Figure 2).

The patient developed jaundice two months after diagnosis and serum bilirubin and transaminase levels were elevated. He died later of hepatic insufficiency. Postmortem examination revealed lymphohistiocytosis in the liver (Figure 3).

CASE 2

A four month-old girl presented to the department of Pediatric Hematology of Erciyes University Medical Faculty with fever and convulsions. Physical examination showed partial albinism and hepatosplenomegaly. Family history revealed sibling deaths.

Laboratory examination showed: hemoglobin of 8 g/dL, white blood cell count 7300/mm³, platelet count 76000/mm³, serum total and direct bilirubin 2.6/1.1 mg/dL, serum ferritin 286 ng/dL, serum fibrinogen 388 mg/dL, serum triglycerides 496 mg/dL, serum cholesterol 223 mg/dL, and serum transaminase values were normal. Cerebrospinal fluid examination was normal.

The serum immunoglobulin levels, T-cell numbers, chemotactic response and result of NBT test were normal.

Phagocytosis was studied by flow cytometry using Mo Ab (DCFH, PMA oxidative burst, Coulter) and was found normal.

Splenectomy was performed because of excessive splenomegaly at the age of six months

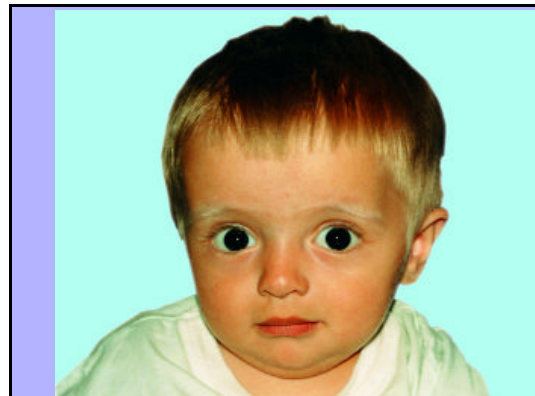

Figure 1. Silvery hair in one sibling

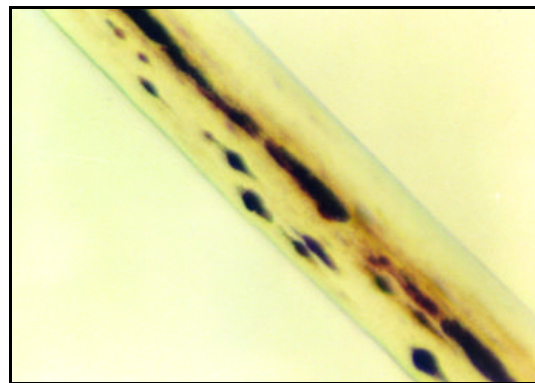


Figure 2. Irregular clumps of pigment in the hair shaft

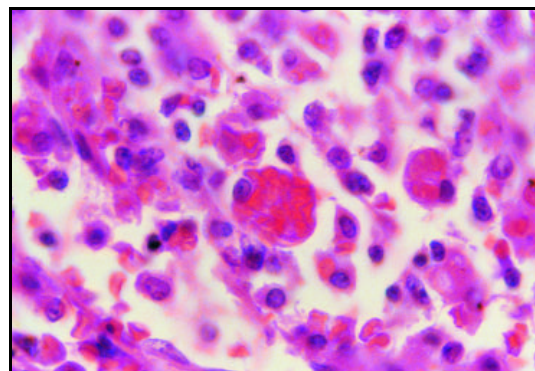


Figure 3. Lymphohistiocytosis in the liver

and histopathologic examination revealed lymphohistiocytosis. She died during follow-up.

DISCUSSION

Griscelli's syndrome can be diagnosed with a typical clinical phenotype such as silvery hair and light skin color. The clinical symptoms of patients with Griscelli's syndrome are similar to that seen in Chediak-Higashi syndrome, but the granulocytes show giant cytoplasmic granules in the latter. In our patients, the absence of giant granules in white blood cells and the microscopic findings of the hair were consistent with Griscelli's syndrome^[1,8].

Vici et al. described a syndrome associating hypopigmentation, combined immunodeficiency, bilateral cataracts, and agenesis of the corpus callosum in two brothers. Immunologically, this syndrome has been characterized by a dysplastic thymus, lymphopenia, decreased CD₄⁺ cell counts, lack of skin delayed-type hypersensitivity, dysfunction of T cell-mediated immunity and normal NK function^[9]. Ozand et al reported a case with mental retardation, abnormal myelination in cerebral hemispheres, and partial albinism who had spontaneous chromosome breaks in peripheral blood lymphocytes^[10]. Chromosome analysis in peripheral blood lymphocytes of our patients was not performed. Our patients had no mental retardation and cataract.

Patients with Griscelli's syndrome had variable immunodeficiency such as absence of delayed-type hypersensitivity and impaired natural killer cell function, secondary hypogammaglobulinemia and impaired major histocompatibility complex-mediated cytotoxic effects^[5].

Delayed type skin sensitivity test of our patients were positive with PHA and PPD and their serum immunoglobulin levels T-cell numbers, chemotactic response and result of NBT test were normal.

Treatment of Griscelli's syndrome has consisted of remission induction with corticosteroids, etoposide and intrathecally administered methotrexate to control central nervous system disease. The curative treatment is bone marrow transplantation^[3,5,7]. Unfortunately bone marrow transplantation could not be performed in our patients and case 1 died of hepatic insufficiency and case 2 died of postsplenectomy infection shortly after diagnosis.

REFERENCES

1. Griscelli C, Durandy A, Guy-Grand D, et al. A syndrome associating partial albinism and immunodeficiency. *Am J Med* 1978;65:691-702.
2. Durandy A, Breton-Gorius J, Guy-Grand D, et al. Prenatal diagnosis of syndromes associating albinism and immunodeficiencies (Chediak Higashi syndrome and variant). *Prenatal Diagnosis* 1993;13:13-20.
3. Mancini AJ, Chan LS, Pallen AS. Partial albinism with immunodeficiency. Griscelli syndrome: Report of a case and review of the literature. *J Am Acad Dermatol* 1998;38:295-300.
4. Salazan-Cabrera AN, Matos-Mantinez M, Sanchez Willegas MC, et al. The Griscelli-Prunieras syndrome: A case report. *Buletin Medico del Hospital Infantil de Mexico*. 1993;50:503-7.
5. Klein C, Philippe N, Le Deist F, et al. Partial albinism with immunodeficiency (Griscelli syndrome). *J Pediatrics* 1994;125:886-95.
6. Sanal O, Küçükali T, Ersoy F, Tınaztepe K, Göğüş S. Griscelli's syndrome. Clinical Features of three siblings. *Turk J Pediatrics* 1993;35:115-9.
7. Hasanođlu A, Aral YZ, Gücüyener K, et al. Griscelli Hastalığı (Bir vaka takdimi). *Anatolian J Pediatr* 1994;3:61-4.
8. Göğüş S, Topçu M, Küçükali T, et al. Griscelli syndrome: Report of three cases. *Pediatr Pathol & Lab Med* 1995;15:309-19.
9. Vici CD, Sabetta G, Gambarara M, et al. Agenesis of the corpus callosum, combined immunodeficiency, bilateral cataract and hypopigmentation in two brothers. *Am J Med Genet* 1998;29:1-8.
10. Ozand PT, Waghray M, Cook JD, et al. Riyadh chromosome breakage syndrome: Mental retardation with depigmentation of the skin and hair. *J Child Neurol* 1992;7:79-82.

Address for Correspondence:

Türkan PATIROĐLU, MD
Department of Pediatrics,
Medical School,
Erciyes University,
Kayseri, TURKEY