

---

# An Extra Benefit of Allogeneic Peripheral Blood Stem Cell Transplantation in a Patient with Lymphoblastic Lymphoma: Cure of Thalassemia Minor

Harika ÇELEBİ\*, Celalettin ÜSTÜN\*, Mutlu ARAT\*, Hamdi AKAN\*,  
Gürol TUNÇMAN\*\*, Tayfun ÖZÇELİK\*\*, H. Şenol COŞKUN\*, Haluk KOÇ\*

\* Department of Hematology and Bone Marrow Transplant Unit, Ibn-i Sina Hospital, Ankara University,  
\*\* Department of Molecular Biology, Bilkent University, Ankara, TURKEY

## ABSTRACT

β thalassemia minor is frequent in mediterranean countries. It is a benign disorder and does not warrant any therapeutical intervention. We transplanted a 25-year-old Turkish male who was diagnosed as lymphoblastic lymphoma and had β thalassemia minor as well. He received peripheral blood stem cells transplantation from his HLA-identical sibling who was not a carrier of β thalassemia. After the allogeneic transplantation we did not only observe remission of the lymphoblastic lymphoma but also the disappearance of β thalassemia minor.

**Key Words:** β thalassemia minor, allogeneic peripheral blood stem cell transplantation, lymphoblastic lymphoma

Turk J Haematol 2000;17(2):77-79.

## INTRODUCTION

Thalassemia, a deficient hemoglobin syndrome, characterized by defective globin synthesis, is one of the most common genetic disorders. β thalassemia is encountered commonly in the Mediterranean countries, including Turkey, Italy, Greece, and some Asian, and African countries<sup>[1,2]</sup>. According to homozygous or heterozygous state of inheritance that determine the quantity of β-chain production, it can be classified as β thalassemia major and minor, respectively. Since β tha-

lassemia minor is rarely associated with significant clinical manifestations, except mild hypochromic microcytic anemia, therapeutical interventions are generally not necessary for these patients.

Currently patients with lymphoblastic lymphoma can be cured by high dose therapies and also by allogeneic hematopoietic stem cell transplantation (alloHSCT) if they have HLA-identical siblings or matched unrelated donors<sup>[3]</sup>.

Here, we present a patient with lymphoblastic lymphoma and b thalassemia minor who underwent allogeneic peripheral blood stem cell transplantation (alloPBSCT). After allogeneic transplantation we did not only observe the remission of the lymphoblastic lymphoma but also the disappearance of b thalassemia minor.

### CASE REPORT

A 25-year-old Turkish male was diagnosed as b thalassemia minor in 1997. At the time of diagnosis, his laboratory examinations were as follows: hemoglobin 140 g/L, red blood cell count:  $7.01 \times 10^{12}/L$ , hematocrit 47.2%, mean corpuscular volume 67 fl, mean corpuscular hemoglobin concentration 29.7 g/dL, red cell distribution width 12.5%, reticulocyte count 1.6%, serum iron 84 mg/dL (40-130), serum iron binding capacity 181 mg/dL (110-330), transferrin saturation 46% (20-55), total bilirubin 0.5 mg/dL (0.1-1.2), lactated dehydrogenase 110 IU/L (90-230). Hemoglobin electrophoresis revealed Hb A 95.49%, Hb A<sub>2</sub> %4.50. A family search was performed for b thalassemia state by hemoglobin electrophoresis, revealed that his mother, two brothers and one sister were also b thalassemia carriers (Figure 1).

The patient developed lymphoblastic lymphoma in November 1997. Daunorubicin 60 mg/m<sup>2</sup>/day I.V. and vincristin 1.4 mg/m<sup>2</sup>/day I.V. for 1<sup>st</sup>, 8<sup>th</sup>, 15<sup>th</sup>, 21<sup>st</sup> days, prednisolone 60 mg/m<sup>2</sup>/day p.o. from day 1 to day 28, L-asparaginase 10.000 IU/day I.V. two days a week for three weeks were given as remission induction therapy. The patient received cyclophosphamide,

cytarabine and 6-mercaptopurine for consolidation. Intrathecal methotrexate (for 6 courses) and cranial radiotherapy were used for central nervous system prophylaxis. He was conditioned with busulfan and cyclophosphamide and then given  $7.17 \times 10^6/kg$  CD34+ cells and  $2.71 \times 10^8/kg$  mononuclear cells in August 1998. Cyclosporine and short term methotrexate were given for graft-versus-host disease prophylaxis. The neutrophil and platelet engraftment occurred on +12<sup>th</sup> day. His MCV level increased to normal levels two months after alloPBSCT (Figure 2). At the 3<sup>rd</sup> month, Hb electrophoresis showed that the Hb A and Hb A<sub>2</sub> levels were 97.2% and 2.8%, respectively. Complete chimerism was documented with short tandem repeats. He is now alive and in complete remission without a sign of the b thalassemia minor.

### DISCUSSION

b thalassemia minor has a heterozygous state for gene complex of b-chain of globin since individuals inherit only one b-chain gene from each parent<sup>[1]</sup>. In our patient, the family survey showed that he inherited the defective b-chain gene complex from his mother. He was not the only member of the family affected, but also his two brothers and one sister were also carrying the defective gene. The molecular pathogenesis of this disorder is very heterogenous, including mutations and deletions that cause diminished b-chain production<sup>[1]</sup>. This imbalance in globin chain synthesis results in ineffective erythropoiesis and also shortens the life span of red blood cells. The hallmark of b thalassemia minor is an elevated level of Hb A<sub>2</sub>.

As in our patient, the carriers may solely have mild hypochromic microcytic anemia. MCHC is generally normal, and microcytosis is much more marked than hypochromia<sup>[1]</sup>.

In contrast to b thalassemia major in which AlloHSCT's were performed successfully<sup>[4,5]</sup>, b thalassemia minor is a benign disorder and does not warrant any therapeutical intervention. However, our patient had to undergo alloPBSCT due to lymphoblastic lymphoma, and his donor was not a b thalassemia carrier. After alloPBSCT, we observed not only the remission of lymphoblastic lymphoma but also the disappearance of b thalassemia minor as well. Therefore, our patient had two gains with one procedure.

There are patients reported in the literature for be-

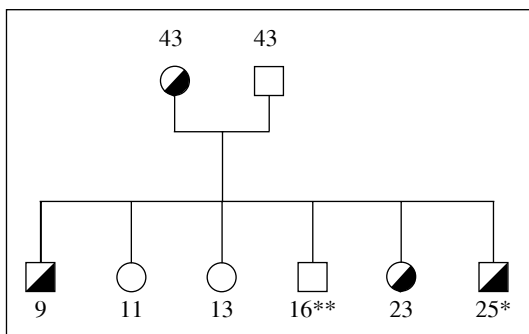
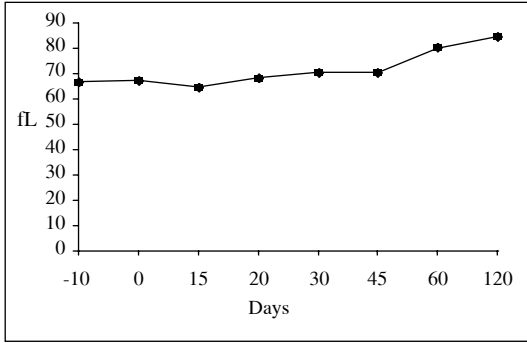


Figure 1. Pedigree of the patient

Mother, two brothers and one sister are affected by thalassemia, but the donor is normal.

Abbreviations: \* Recipient, \*\* Donor, The numbers show the ages of the family members



**Figure 2.** The patient's MCV level increased to normal after transplantation.

ing healed of two different hematological disorders. A SCLL patient who had also the diagnosis of ITP was cured of both clinical conditions after high dose chemotherapy with autologous stem cell rescue<sup>[6]</sup>. On the contrary a CML patient acquired thalassemia minor from his donor who was a thalassemia carrier<sup>[7]</sup>.

## REFERENCES

1. Lukens JN. The thalassemias and related disorders: Quantitative disorders of hemoglobins synthesis. In: Lee GR, Foerster J, Lukens J, Paraskevas F, Greer JP, Rodgers GM (eds.). *Wintrobe's Clinical Hematology*. Williams & Wilkins A Waverly Company 1999; 1405-48.
2. Aydınok Y, Öztıp S, Nişli G, Kavaklı K. Prevalence of beta-thalassaemia trait in 1124 students from Aegean region of Turkey. *J Trop Pediatr* 1997;43: 184-5.
3. De Witte T, Award B, Boezeman J, et al. Role of allogeneic bone marrow transplantation in adolescent or adult patients with acute lymphoblastic lymphoma in first remission. *Bone Marrow Transplant* 1994; 14:767-74.
4. Lucarelli G. Bone marrow transplantation for thalassaemia. *J Intern Med Suppl* 1997;740:49-52.
5. Lucarelli G, Galimberti M, Polchi P, et al. Bone marrow transplantation in adult thalassaemia. *Blood* 1992;15:1603-7.
6. Demirel T, Çelebi H, Arat M, Üstün C, Demirel S, Dilek İ, Özcan M, İlhan O, Akan H, Gürman G, Koç H. Autoimmün trombocytopenia in a patients with small cell lung cancer developing after chemotherapy and resolving following autologous peripheral blood stem cell transplantation. *Bone Marrow Transplant* 1999;24:335-7.
7. Sue YC, Liu TC, Chang CS, Huang SM, Chen TP, Lin SF. Allogeneic bone marrow transplantation of chronic myeloid leukemia from an HLA-matched unrelated donor with the beta-thalassemic trait. *Int J Hematol* 1999;69:200-2.

## Address for Correspondence:

Hamdi AKAN, MD

Ankara University, İbn-i Sina Hospital,  
Dept. of Hematology,  
06100, Ankara, TURKEY