

# Scrotal leiomyosarcoma

## Skrotal leyiomiyosarkom

Sümeyye EKMEKÇİ<sup>1</sup>, Burçin TUNA<sup>2</sup>, Önder ÇINAR<sup>3</sup>, Uđur MUNGAN<sup>3</sup>, Kutsal YÖRÜKOĐLU<sup>2</sup>

<sup>1</sup>Tepecik Eđitim ve Arařtırma Hastanesi, Patoloji Kliniđi, İzmir

<sup>2</sup>Dokuz Eylül Üniversitesi Tıp Fakültesi, Patoloji Anabilim Dalı, İzmir

<sup>3</sup>Dokuz Eylül Üniversitesi Tıp Fakültesi, Üroloji Anabilim Dalı, İzmir

### ABSTRACT

Scrotal leiomyosarcoma is a rare tumour. Long-term follow-up of the patients is mandatory to detect local recurrence and distant metastases that can occur even years after the initial tumoral excision. Distant metastases to the lungs and soft tissues of the neck have been reported.

Here, a case of scrotal leiomyosarcoma (LMS) is presented in a 72 year-old patient. The case has bladder and prostate carcinoma history and radiotherapy was applied to the scrotal region.

The patient is alive without recurrences or metastasis 4 years after the initial diagnosis.

We have presented a rare case of LMS and emphasized its importance in the differential diagnosis of scrotal mesenchymal neoplasms.

**Key words:** Leiomyosarcoma, scrotum

### ÖZET

Skrotal leyomiyosarkom ender bir tümördür. Bu tümörler yıllar içerisinde uzak metastaz ve lokal nüks yapmaları nedeniyle uzun süreli takipleri gereklidir. Akciđer ve boyun yumuřak dokulara uzak metastazları bildirilmiştir.

Burada, 72 yařında skrotal leyomiyosarkom olgusu sunulmaktadır. Olguda mesane ve prostat karsinom öyküsü mevcut olup, skrotal bölgeye radyoterapi tedavisi uygulanmıştır.

Hasta tanı sonrası 4. yılda olup, metastaz ve rekürrens izlenmemiřtir.

Biz burada skrotal LMS'nin skrotal mezenkimal neoplazilerin ayırıcı tanısındaki önemini vurgulamak istedik.

**Anahtar kelimeler:** Leyomiyosarkom, skrotum

**Alındıđı tarih:** 20.02.2015

**Kabul tarihi:** 23.02.2015

**Yazıřma adresi:** Uzm. Dr. Sümeyye Ekmekçi, Tepecik Eđitim ve Arařtırma Hastanesi, Patoloji Kliniđi, İzmir

**e-mail:** ekmekcisumeyye@gmail.com

### INTRODUCTION

Leiomyosarcoma (LMS) accounts for 10-20% of soft tissue sarcomas. However, LMS of the scrotum is rare and only 40 cases located in the scrotum have been reported in the literature so far <sup>(1)</sup>. Scrotal LMSs are slowly growing tumors that present as firm rubbery non-tender irregular masses <sup>(2)</sup>. They may arise from paratesticular soft tissues or scrotal skin. Over 95% of all paratesticular leiomyosarcomas are located in the spermatic cord or epididymis; while their location in the scrotal skin is exceptional <sup>(1)</sup>. They are

often mistaken for a benign condition, with the true diagnosis revealed only on pathologic examination <sup>(3)</sup>. In this article, a case of leiomyosarcoma of the scrotal skin in a 72 year-old man is reported for its rarity.

### CASE REPORT

A 62 year-old man underwent transurethral resection (TUR) for multiple papillary lesions at left and right lateral walls of urinary bladder in 2001. Pathological findings included pTaG1 papillary tran-

sitional cell carcinoma and the patient underwent intravesical 80 mg BCG instillation immunotherapy for six weeks for his multiple papillary pTaG1 tumors. No recurrence was found in the follow-up cystoscopic examinations performed for 8 years. In 2009 although the patient's rectal examination was normal, serum PSA level was 7.7 ng/ml and he underwent transrectal ultrasound-guided prostate biopsy. Adenocarcinoma with a Gleason score of 4+4=8 was diagnosed, and the patient was staged as having cT1cN0M0 prostate cancer. Retropubic radical prostatectomy was performed and pathologic examination revealed pT2cN0M0 prostate adenocarcinoma with a Gleason score of 3+4=7. The apical surgical margin was positive, so the patient underwent adjuvant radiotherapy. On March 2011, the patient was hospitalized for annual cystoscopic control for his bladder cancer. Before cystoscopy the patient was complaining of a small pruritic lesion on penoscrotal junction which expanded and became a nodular protruding lesion about two centimeters with a smooth surface during the period of radiotherapy. This suspect lesion was excised after control cystoscopy.

Macroscopically, the tumoral lesion measuring 1.7x1.2x0.8 cm was solid with grey-white colour. Light microscopy showed the typical interlacing fascicles of neoplastic cells which led to diagnosis of LMS (Figure 1). Immunohistochemical analysis

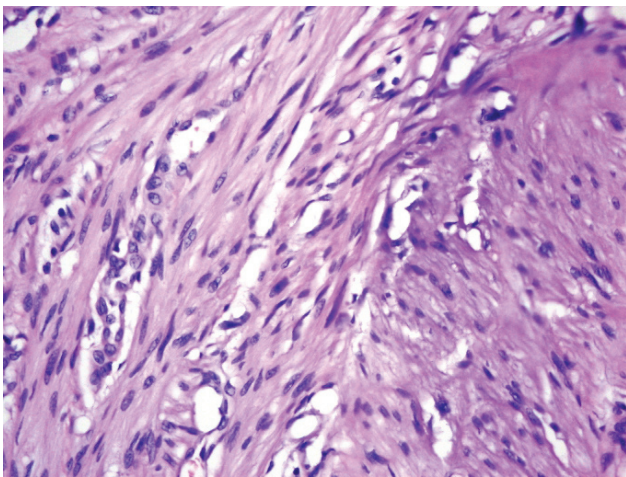


Figure 1. Spindle shaped atypical cells in H&E slide (x40)

showed that tumor cells were diffusely positive for actin, desmin and caldesmon (Figure 2). There was focal positivity for S-100. CD34, HMB 45, c-kit and cytokeratin was negative. Diagnosis of LMS was made with these histopathologic and immunohistochemical findings. Surgical margins were free of tumor. Systemic screening tests did not demonstrate any distant organ metastasis.

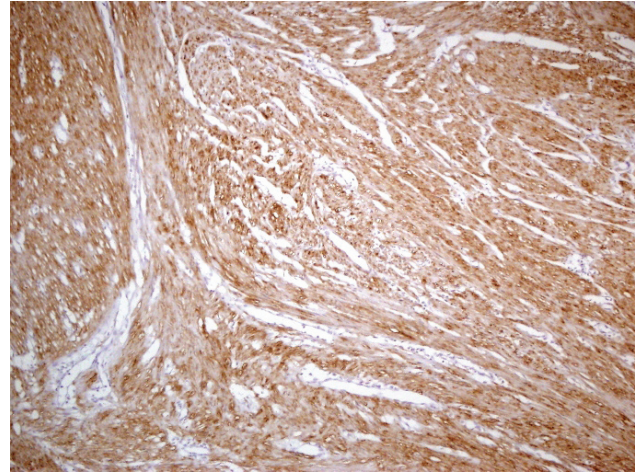


Figure 2. Immunohistochemical analysis of caldesmon in spindle shaped atypical cells (x10)

## DISCUSSION

Subcutaneous LMS accounts for 1 to 2% of all superficial soft tissue malignancies. Among genitourinary sarcomas in adults, leiomyosarcomas are the most common type and arises from the bladder, kidney or prostate <sup>(1)</sup>. Leiomyosarcomas of the scrotum, not involving the testis, epididymis or spermatic cord, are rarely seen <sup>(4)</sup>, and belong to the group of subcutaneous superficial leiomyosarcomas <sup>(5)</sup>. Less than 40 cases located in the scrotum have been reported in the literature so far <sup>(1)</sup>.

They present between the fourth and eight decades of life as a painless, slow-growing skin lesion. The duration of symptoms varies from several months to a few years <sup>(6)</sup>.

Leiomyosarcomas are subdivided topographically into 3 groups: LMS of the deep soft tissue, LMS of the cutaneous and subcutaneous tissue and LMS of vascular origin <sup>(7)</sup>. Paratesticular LMS originates

from the spermatic cord, the scrotum (testicular tunica, dartos muscle and scrotal subcutis) or the epididymis<sup>(8,9)</sup>. The most common type arises from undifferentiated mesenchymal cells of the cremasteric muscle and vas deferens<sup>(8,9)</sup>. The epididymal form is less frequent and arises from the smooth muscle surrounding the basement membrane of the epididymis canal. Scrotal types arise from the dartos layer<sup>(8,9)</sup>.

They usually occur in middle-aged and elderly men<sup>(3)</sup>. Local irradiation is a possible etiologic factor<sup>(10)</sup>.

The differential diagnosis of adult spindle cell tumors in this site includes primarily fibrous mesothelioma, various benign fibrous tumors, pseudotumors, and fibromatosis. Our case had morphological and immunohistochemical profiles characteristic of smooth muscle differentiation.

The primary treatment of scrotal LMS is complete excision including histopathologically proven negative margins<sup>(8)</sup>. These are slow-growing tumors, best treated by wide local excision<sup>(11)</sup>. Its behavior is related to its location, size, depth, histological grade, and the presence of nodal or distant metastases<sup>(8)</sup>. For most patients, local control is improved with preoperative or postoperative radiotherapy<sup>(9)</sup>. The role of chemotherapy for high-risk patients remains controversial, but it is used at several major centres for high-risk patients. Our patient was treated by a wide local excision and adjunctive therapy was not given postoperatively. At 4 years post-surgery he was alive with no evidence of disease.

The prognosis is generally good in the absence of local recurrence(s). A surgically positive margin detected at the first excision dramatically increases the risk of local recurrence<sup>(3)</sup>. Distant metastases to the lungs, liver, bone or lymph nodes have been reported<sup>(12)</sup>. Although its prognosis is generally good, in the absence of local recurrence, long-term follow-up is needed, because local and late recurrences and distant metastasis can occur years after the initial excision. The possibility of LMS should be kept in mind in the differential diagnosis of scrotal masses.

In conclusion, we have presented a rare case of LMS and emphasized its importance in the differential diagnosis of scrotal mesenchymal neoplasms.

## REFERENCES

1. Talikoti MA, Deo SS, Shukla NK, Kallianpur AA, Gupta M. A rare case of giant leiomyosarcoma in a filarial scrotum: a case report. *World Journal of Surgical Oncology* 2011; 9:20. PMID: 21310071  
<http://dx.doi.org/10.1186/1477-7819-9-20>
2. Kumar V, Abbas AK, Fausto N, Mitchell R. Robbins basic pathology. Elsevier; 2007;8:835.
3. John T, Portenier D, Auster B, Mehregan D, Drelichman A, Telmos A. Leiomyosarcoma of scrotum - case report and review of literature. *Urology* 2006;67(2):424. PMID: 16461113  
<http://dx.doi.org/10.1016/j.urology.2005.09.022>
4. Jeddy TA, Vowles RH, Southam JA. Leiomyosarcoma of the dartos muscle. *Br J Urol* 1994;74:129-130. PMID: 8044517  
<http://dx.doi.org/10.1111/j.1464-410X.1994.tb16568.x>
5. Fields JP and Helwig EB. Leiomyosarcoma of the skin and subcutaneous tissue. *Cancer* 1981;47:156-159. PMID:7459804  
[http://dx.doi.org/10.1002/1097-0142\(19810101\)47:1<156::AID-CNCR2820470127>3.0.CO;2-#](http://dx.doi.org/10.1002/1097-0142(19810101)47:1<156::AID-CNCR2820470127>3.0.CO;2-#)
6. Persichetti P, Di Lella F, Marangi GF, Cagli B, Simone P, Tenna S, et al. Leiomyosarcoma of the scrotum arising from the dartos muscle: a rare clinicopathological entity. *In Vivo* 2004;18(5):553-554. PMID: 15523892
7. Alberghini M, Zanella L, Bacchini P, Maltarello MC, Maraldi NM, Bertoni F. Leiomyosarcoma of the spermatic cord: a light and ultrastructural description of one case. *Pathol Res Pract* 2004;200:487-491. PMID:15310153  
<http://dx.doi.org/10.1016/j.prp.2004.04.007>
8. Dangle P, Basavaraj DR, Bhattarai S, Paul AB, Biyani CS. Leiomyosarcoma of the spermatic cord: case report and literature review. *Can Urol Assoc J* 2007;1:55-58. PMID:18542764
9. Fagundes MA, Zietman AL, Althausen AF, Coen JJ, Shipley WU. The management of spermatic cord sarcoma. *Cancer* 1996;77:1873-1876. PMID:8646687  
[http://dx.doi.org/10.1002/\(SICI\)1097-0142\(19960501\)77:9<1873::AID-CNCR17>3.0.CO;2-X](http://dx.doi.org/10.1002/(SICI)1097-0142(19960501)77:9<1873::AID-CNCR17>3.0.CO;2-X)
10. Dalton DP, Rushovich AM, Victor TA, Larson R. Leiomyosarcoma of the scrotum in a man who had received scrotal irradiation as a child. *J Urol* 1988;139:136-138. PMID:3275795
11. Echenique JE, Tully S, Tickman R, Walther MM, O'Brien DP, Judd RL. A 37-pound scrotal leiomyosarcoma: a case report and literature review. *J Urol* 1987;138:1245-1246. PMID:3312643
12. Fisher C, Goldblum JR, Epstein JI, Montgomery E. Leiomyosarcoma of the paratesticular region: a clinicopathologic study. *Am J Surg Pathol* 2001;25(9):1143-1149. PMID: 11688573  
<http://dx.doi.org/10.1097/00000478-200109000-00004>