



Is Paravertebral-Epidural Spread the Underlying Mechanism of Action of Erector Spinae Plane Block?

Sandeep Diwan¹ , Abhijit Nair² 

¹Department of Anaesthesiology, Sancheti Hospital, Pune, Maharashtra State, Pune, India

²Department of Anaesthesiology, Basavatarakam Indo-American Cancer Hospital and Research Institute, Telangana State, Hyderabad, India

Cite this article as: Diwan S, Nair A. Is Paravertebral-Epidural Spread the Underlying Mechanism of Action of Erector Spinae Plane Block? Turk J Anaesthesiol Reanim 2019; DOI: 10.5152/TJAR.2019.81226.

Erector spinae plane block (ESPB) is an ultrasound (US)-guided regional anaesthesia technique. The proposed mechanism of action of ESPB is local anaesthetic spread in a cephalocaudal direction within the fascial plane deep to the erector spinae muscle (ESM) in paraspinal region and towards paravertebral space through inter-transverse soft tissue (1, 2). It remains unclear how the block provides somatic and visceral blockade (3).

Computed tomography (CT) image (Figure 1) shows radio-opaque contrast spread deep to ESM, retrolaminar spread medially, paravertebral spread and posterior epidural spread through the intervertebral foramina space at all levels. With a single injection, the spread was observed up to the lateral epidural space at all levels. The spread is seen across the costotransverse foramen, which could be the mechanism of visceral pathway blockade. In serial CT images, a dorsal rami path was also observed.

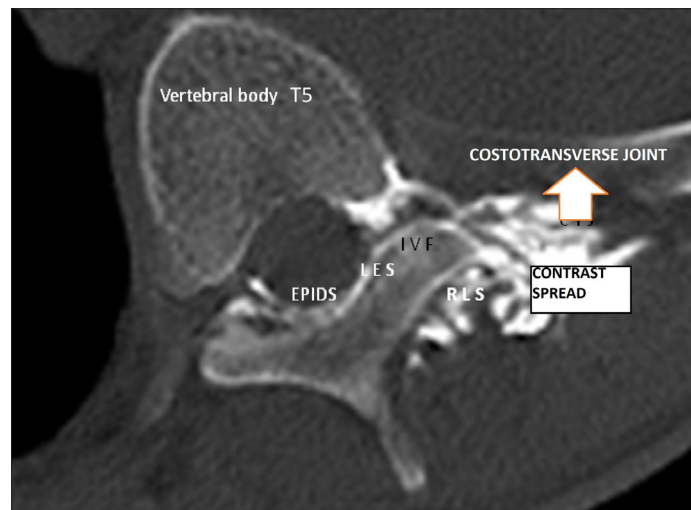


Figure 1. Computed tomography image shows radio-opaque contrast spread deep to the erector spinae muscle, a medial retrolaminar spread, paravertebral spread and posterior epidural spread through the intervertebral foramina space
EPIDS: epidural space; LES: lateral epidural space; IVF: intervertebral foramina; RLS: retrolaminar space

This CT image is of a 65-year-old male with carcinoma right lung who was suffering from severe visceral thoracic pain. Consent was obtained from the patient for using these images. US-guided ESPB was performed on right side at T5 level with 25 mL of 0.25% bupivacaine, 3 mL of iohexol (300 mg iodine/mL) and 40 mg of methylpredisone. Pain score before injection was 8/10 and that after injection was 1/10. The dermatomal level of analgesia achieved after the block was from T2 to T7 on right side. Scan was performed 30 min after the injection.

Informed Consent: Written informed consent was obtained from patient who participated in this study.

Peer-review: Externally peer-reviewed.

Author Contributions: Concept – S.D.; Design – A.N.; Supervision – S.D.; Resources – S.D., A.N.; Materials – A.N.; Data Collection and/or Processing – S.D., A.N.; Analysis and/or Interpretation – S.D.; Literature Search – A.N.; Writing Manuscript – S.D.; Critical Review – A.N.; Image editing and labelling – S.D.

Conflict of Interest: The authors have no conflicts of interest to declare.

Financial Disclosure: The authors declared that this study has received no financial support.

References

1. Forero M, Adhikary SD, Lopez H, Tsui C, Chin KJ. The erector spinae plane block: a novel analgesic technique in thoracic neuropathic pain. *Reg Anesth Pain Med* 2016; 41: 621-7. [\[CrossRef\]](#)
2. Forero M, Rajarathinam M, Adhikary SD, Chin KJ. Erector spinae plane block for the management of chronic shoulder pain: a case report. *Can J Anesth* 2018; 65: 288-93. [\[CrossRef\]](#)
3. Schwartzmann A, Peng P, Maciel MA, Forero M. Mechanism of the erector spinae plane block: insights from a magnetic resonance imaging study. *Can J Anaesth* 2018; 65: 1165-6. [\[CrossRef\]](#)