



# Comparison of Direct and Remote Ischaemic Preconditioning of Renal Ischaemia Reperfusion Injury in Rats

Ratlarda Renal İskemi Reperfüzyon Hasarı Üzerine Direk ve Uzak İskemik Önkoşullamanın Karşılaştırılması

Keziban Oral<sup>1</sup>, Mert Akan<sup>2</sup>, Sevda Özkardeşler<sup>3</sup>, Nilay Boztaş<sup>3</sup>, Bekir Uğur Ergür<sup>4</sup>, Mehmet Ensari Güneli<sup>5</sup>, Çimen Olguner<sup>3</sup>, Hatice Fidan<sup>6</sup>

<sup>1</sup>Department of Anaesthesiology and Reanimation, Katip Çelebi University, İzmir, Turkey

<sup>2</sup>Department of Anaesthesiology and Reanimation, Kent Hospital, İzmir, Turkey

<sup>3</sup>Department of Anaesthesiology and Reanimation, Dokuz Eylül University School of Medicine, İzmir, Turkey

<sup>4</sup>Department of Histology, Dokuz Eylül University School of Medicine, İzmir, Turkey

<sup>5</sup>Laboratory Animal Department, Dokuz Eylül University School of Medicine, İzmir, Turkey

<sup>6</sup>Department of Anaesthesiology and Reanimation, Ereğli Hospital, Zonguldak, Turkey

**Cite this article as:** Oral K, Akan M, Özkardeşler S, Boztaş N, Ergür BU, Güneli ME, et al. Comparison of Direct and Remote Ischaemic Preconditioning of Renal Ischaemia Reperfusion Injury in Rats. Turk J Anaesthesiol Reanim 2018; 46(6): 453-61.

**ORCID IDs of the authors:** K.O. 0000-0002-6422-3663; M.A. 0000-0003-0195-7149; S.Ö. 0000-0001-5654-6262; N.B. 0000-0001-9341-754X; B.U.E. 0000-0002-6448-2593; M.E.G. 0000-0002-1501-8241; Ç.O. 0000-0002-3688-8078; H.F. 0000-0002-8590-2868

**Objective:** One of the methods that can be used to prevent ischaemia reperfusion (IR) injury is ischaemic preconditioning. The aim of this study was to evaluate and compare the effects of remote and direct ischaemic preconditioning (RIPC and DIPC) histopathologically in the rat renal IR injury model.

**Methods:** After obtaining an approval from the Dokuz Eylül University School of Medicine Ethics Committee, 28 Wistar Albino male rats were divided into four groups. In Group I (Sham, n=7), laparotomy and left renal pedicle dissection were performed, but nothing else was done. In Group II (IR, n=7), after 45 minutes of left renal pedicle occlusion, reperfusion lasting 4 hours was performed. In Group III (DIPC+IR, n=7), after four cycles of ischaemic preconditioning applied to the left kidney, renal IR was performed. In Group IV (RIPC+IR, n=7), after three cycles of ischaemic preconditioning applied to the left hind leg, renal IR was performed. All rats were sacrificed, and the left kidney was processed for conventional histopathology.

**Results:** The histopathological injury score of the kidney was significantly lower in the sham group compared with the other groups (p<0.01). The injury scores of the DIPC+IR and RIPC+IR groups were significantly lower than in the IR group (p<0.05). In the RIPC+IR group, the injury score for erythrocyte extravasation was found to be significantly lower than in the DIPC+IR group (p<0.05).

**Conclusion:** In the present study, it was demonstrated that both DIPC and RIPC decreased renal IR injury, but RIPC was found to be more effective than DIPC. This protective effect requires further detailed experimental and clinical studies.

**Keywords:** Kidney, reperfusion injury, ischaemic preconditioning

**Amaç:** Şok, böbrek transplantasyonu, kısmi nefrektomi, kardiyopulmoner bypass, sepsis, ürolojik girişimler ve hidronefroz gibi çeşitli klinik durumlarda, böbrek kan akımının tıkanması sonrası böbrekte iskemik; kan akımının yeniden sağlanması ile reperfüzyon ortaya çıkmaktadır. Böbrek iskemik reperfüzyon hasarı alıcıda gecikmiş greft fonksiyonu yanında çoklu organ yetersizliğine neden olabilir. Reperfüzyon azaltmak amacıyla kullanılan yöntemlerden biri iskemik ön koşullamadır. Bu çalışmanın amacı rat renal iskemik reperfüzyon modelinde tek taraflı alt ekstremiteye uygulanacak uzak İÖK ile böbreğe uygulanacak direkt İÖK'nin etkilerinin karşılaştırılmasıdır.

**Yöntemler:** Dokuz Eylül Üniversitesi Tıp Fakültesi Hayvan Deneyleri Yerel Etik Kurulu onayı alındıktan sonra ağırlıkları 250-300 g arasında değişen 28 adet erkek Wistar Albino rat her birinde 7'şer denek olacak şekilde 4 gruba ayrılmıştır. Tüm gruplara laparotomi uygulanmış ve sol renal pedikül (SRP) diseke edilmiş, Sham Grubu'na (Grup 1) başka bir işlem yapılmamıştır. Grup 2: 45 dk böbrek iskemisi sonrası 4 saat reperfüzyon, Grup 3: 4 döngü böbrekte iskemik ön koşullama sonrası böbrekte iskemik reperfüzyon, Grup 4: sol arka bacağına uygulanan üç döngü iskemik ön koşullama sonrası böbrekte iskemik reperfüzyon gerçekleştirilmiştir. Tüm gruplarda ratların anestezi süresi eşit tutulmuş, histopatolojik değerlendirme için sol böbrek çıkarıldıktan sonra ratlar sakrifiye edilmiştir.

**Bulgular:** Böbrek histopatolojik hasar skoru sham grubunda diğer gruplara göre anlamlı düşük bulunmuştur. İR grubundaki hasar skorları DİÖK+İR ve UİÖK+İR skorlarından yüksek saptanmıştır. UİÖK+İR grubunda ise eritrosit ekstravazasyonu skoru DİÖK+İR skorundan anlamlı olarak daha düşük bulunmuştur.

**Sonuç:** Bu çalışmada UİÖK ve DİÖK'nin böbrek İR hasarını azalttığı, UİÖK'nin ise DİÖK'ya göre daha etkili olduğu gösterilmiştir. Bu olumlu etkinin öncelikle deneysel çalışmalar ile ayrıştırılması gerektiği sonucuna varılmıştır.

**Anahtar Kelimeler:** Böbrek, reperfüzyon hasarı, iskemik önkoşullama

## Introduction

Ischaemia occurs due to temporary cessation of blood flow in several medical conditions, such as renal transplantation, partial nephrectomy, suprarenal aortic surgery, cardiopulmonary bypass and urological procedures, and reperfusion occurs with the re-maintenance of the blood flow. Ischaemia reperfusion (IR) is defined as the diminution or cessation of blood flow to tissues or an organ, followed by the return of blood supply. Restoration of blood supply might cause more damage to the tissues than ischaemic injury (1). Free oxygen radicals (FOR) are produced in the tissue during the ischaemic period. Super-oxide radicals and FOR cause endothelial damage, increased micro vascular permeability, and tissue oedema (2, 3). Systemic inflammatory response might be initiated by activated adhesion molecules and cytokines. All these responses are defined as IR injury (3). Various methods are developed to prevent IR injury. One of these methods is ischaemic preconditioning (IPC), which was described by Murry et al. (4) in 1986 for the heart (4). IPC is defined as the process of increasing the resistance of the tissue to long-duration ischaemia by short ischaemia-reperfusion episodes (5). Another method is the remote ischaemic preconditioning (RIPC). Increasing the resistance of an organ to ischaemia with the application of IR episodes to another organ is called RIPC (6).

Ischaemic preconditioning performed on the kidneys is claimed to repress the inflammatory response caused by reperfusion. Direct ischaemic preconditioning (DIPC) for the kidney is performed by clamping and declamping the renal artery or pedicle, and the most well-accepted method is fourcycles of 4 minutes of clamping (ischaemia) and 11 minutes of reperfusion (7, 8).

The RIPC of skeletal muscles, the kidney, lung, intestines, liver, and brain was demonstrated to decrease tissue injury induced by IR (9-15). A review of the medical databases revealed no study on the comparison of RIPC and DIPC in the rat renal IR injury model.

The aim of this experimental study was to compare and investigate the effects of lower extremity RIPC and renal DIPC on IR injury of the kidneys, and to evaluate the effects of RIPC and DIPC histopathologically in the rat renal IR injury model.

## Methods

The study was conducted on 28 Wistar albino adult male rats weighing between 250 and 300g in Dokuz Eylul University Multidisciplinary Test Animals Laboratory after the approval of Dokuz Eylul University Faculty of Medicine Animal Experiments Local Ethical Committee (30.04.2010 date, 25/2010 protocol no). Rats were fed with standard rat pellets and water, at room temperature (21-22°C), 40%-60% relative humidity, 12-hour light/dark cycles until the beginning

of the study. They were allowed to drink water only 12 hours prior to the surgical procedure.

Anaesthesia was performed using 50 mg kg<sup>-1</sup> ketamine (Ketalar, Pfizer Pharma GMBH, Germany) and 10 mg kg<sup>-1</sup> xylazine hydrochloride (Alfazyne 2%, Alfasan International, Holland) intraperitoneally, and re-administration of half-dose ketamine to maintain the deepness of anaesthesia by checking the reflex responses.

### Groups and protocol

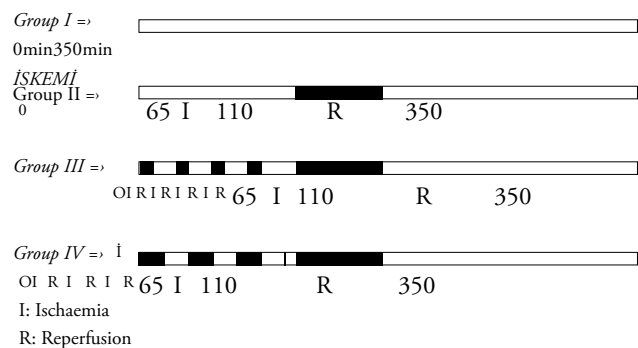
**Group I (Sham, n=7):** Left renal pedicle was dissected after laparotomy, and no further procedure was done.

**Group II (IR, n=7):** 4 hours of reperfusion following 45 minutes of total ischaemia of the left kidney after laparotomy.

**Group III (DIPC+IR, n=7):** Four cycles of 4-minute ischaemia/11-minute reperfusion applied on the left kidney, followed by the same procedure as in Group II, 5 minutes later.

**Group IV (RIPC+IR, n=7):** Three cycles of minute ischaemia/10-minute reperfusion applied on the left lower limb, followed by the same procedure as in Group II, 5 minutes later.

### Schematic view of the research groups



**Group I:** Sham, n=7

**Group II:** Ischaemia reperfusion (IR), n=7

**Group III:** Direct ischaemic preconditioning and ischaemia reperfusion (DIPC+IR), n=7

**Group IV:** Remote ischaemic preconditioning and ischaemia reperfusion (RIPC+IR), N=7

Total working durations were the same (350min) in all groups, and tissue samples were collected at the end of the procedure.

### Experimental IR and DIPC method

An abdominal midline incision was performed on rats in the supine position. The blood supply was stopped to the kidneys by compressing the renal pedicle with a micro-vessel clamp. Four cycles of 4-minute ischaemia/11-minute reperfusion were applied for DIPC. Afterwards, 45 minutes of clamping and 4-hour reperfusion were obtained.

Sufficient occlusion was confirmed with the absence of pulsations of renal pedicle and observed of kidney paleness.

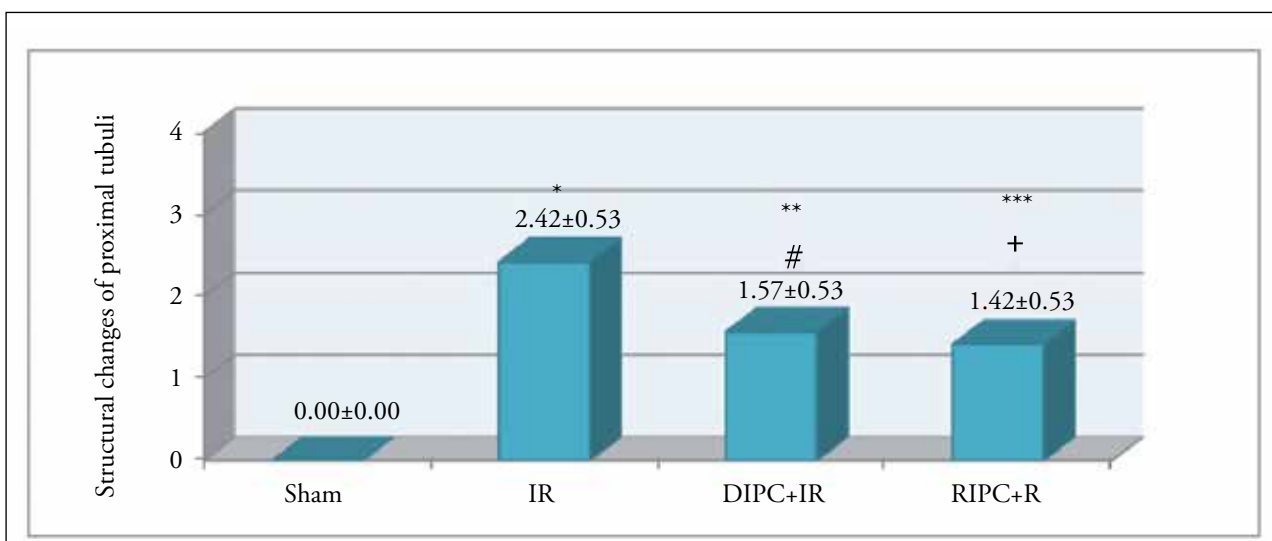


Figure 1. Proximal tubular damage score regarding the histopathological analysis

\*IR Group vs. Sham Group (p<0.01)  
 \*\*DIPC+IR Group vs. Sham Group (p<0.01)  
 \*\*\*RIPC+IR Group vs. Sham Group (p<0.01)

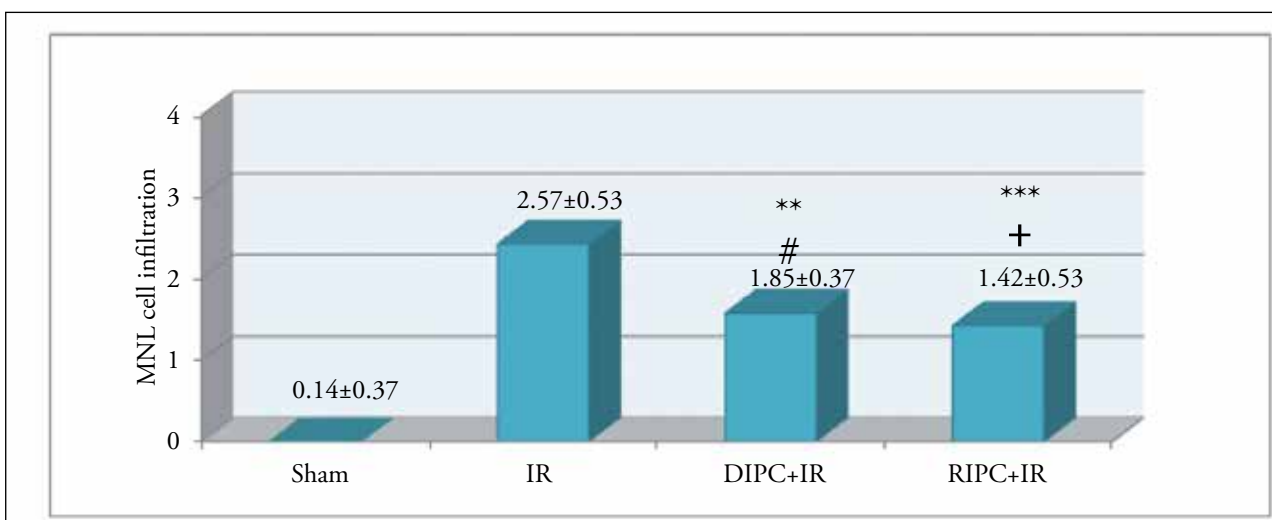


Figure 2. Renal MNL, infiltration scores regarding the renal histopathological analysis

\*IR Group vs. Sham Group (p<0.01)  
 \*\*DIPC+IR Group vs. Sham Group (p<0.01)  
 \*\*\*RIPC+IR Group vs. Sham Group (p<0.01)

**Experimental remote ischaemic preconditioning method**

Three cycles of 10-minute ischaemia/10-minute reperfusion with circular compression obtained with elastic bandage (1 cm wide, 30 cm long) were applied on the left hind leg of the rat (16, 17). The blood flow cessation was confirmed with a laser flow meter (Laser Flo BPM2, Vasamedic, USA).

The operating table was heated with a heating lamp, and 3 mL kg<sup>-1</sup> h<sup>-1</sup> of subcutaneous isotonic fluid solution was administered during the operation to avoid dehydration and hypothermia. The abdomen was covered with a wet sterile gauze and surgical forceps during the reperfusion period. All rats were sacrificed with the exsanguination method (cardiac puncture) after the removal of the left kidney, in all groups.

Tissue samples were fixed inside 10% formaldehyde with a gauze and evaluated histologically for kidney damage.

**Evaluation of renal cellular histopathology**

Renal tissue samples were analysed in the Dokuz Eylul University Medical Faculty Histology Department Laboratory. 5 µm sections were cut from tissue samples that were fixed in 10% formaldehyde and embedded in paraffin, and they were dyed using haematoxylin-eosine, Periodic Acid Schiff and Masson's trichrome triple dye.

Renal tissue samples were analysed blindly, by a histologist working in the Dokuz Eylul University Medical Faculty Histology Department, under a light microscope with regard to

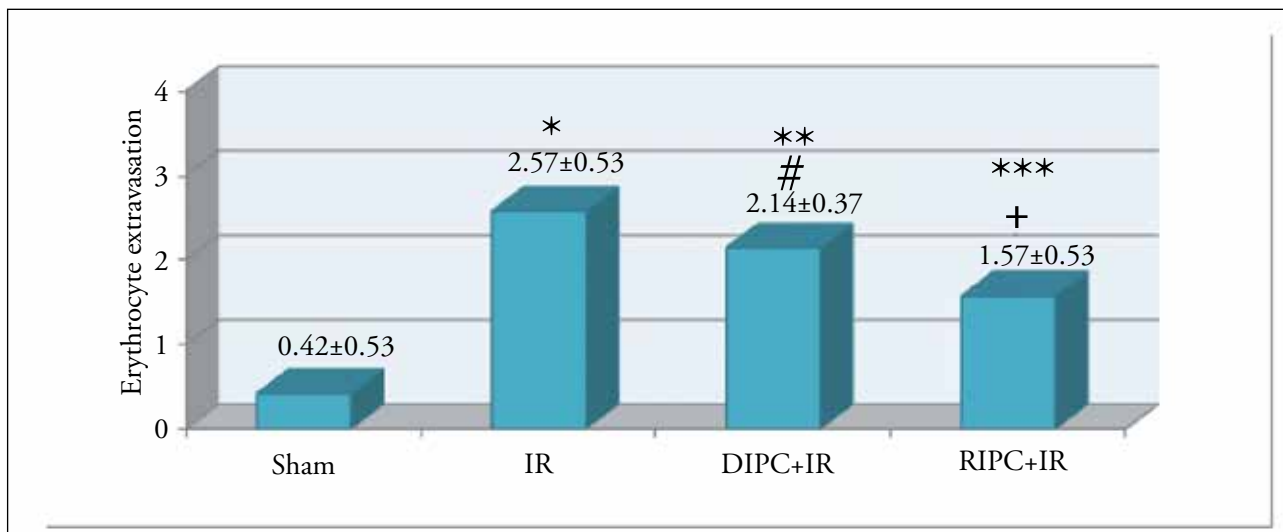


Figure 3. Erythrocyte extravasation scores regarding histopathological kidney analysis

\*IR Group vs. Sham Group (p<0.01)  
 \*\*DIPC+IR Group vs. Sham Group (p<0.01)  
 \*\*\*RIPC+IR Group vs. Sham Group (p<0.01)




Figure 4. Interstitial space damage scores regarding histopathological kidney analysis

\*IR Group vs. Sham Group (p<0.01)  
 \*\*DIPC+IR Group vs. Sham Group (p<0.01)  
 \*\*\*RIPC+IR Group vs. Sham Group (p<0.01)

the structural changes of proximal tubuli (tubular atrophy, tubular brush border loss, tubular dilatation, cast formation, vacuolization), mononuclear cell (MNL) infiltration, erythrocyte extravasation and structural changes of interstitial space. Images acquired from the specimens were scored semi-quantitatively as 0, +, ++, +++, +++++ (0: no change, +: mild, ++: moderate, +++: severe, +++++: very severe changes) (18).

**Statistical evaluation**

The Statistical Package of Social Sciences version 15 (SPSS Inc.; Chicago, IL, USA) programme was used for statistical evaluation. The Kruskal-Wallis variant analysis was for his-

topathological data, and the Mann-Whitney U test was used for comparison among double groups. All values were given as the mean±standard deviation (mean±SD). A p-value 0.05 was considered to be statistically significant. When significant differences were obtained in the Kruskal-Wallis variant analysis, p<0.017 was accepted as significant in pairwise comparisons.

**Results**

A total of 28 rats were included in the study conducted in Dokuz Eylul University Multidisciplinary Animal Testing Laboratory, and all animals completed the study.



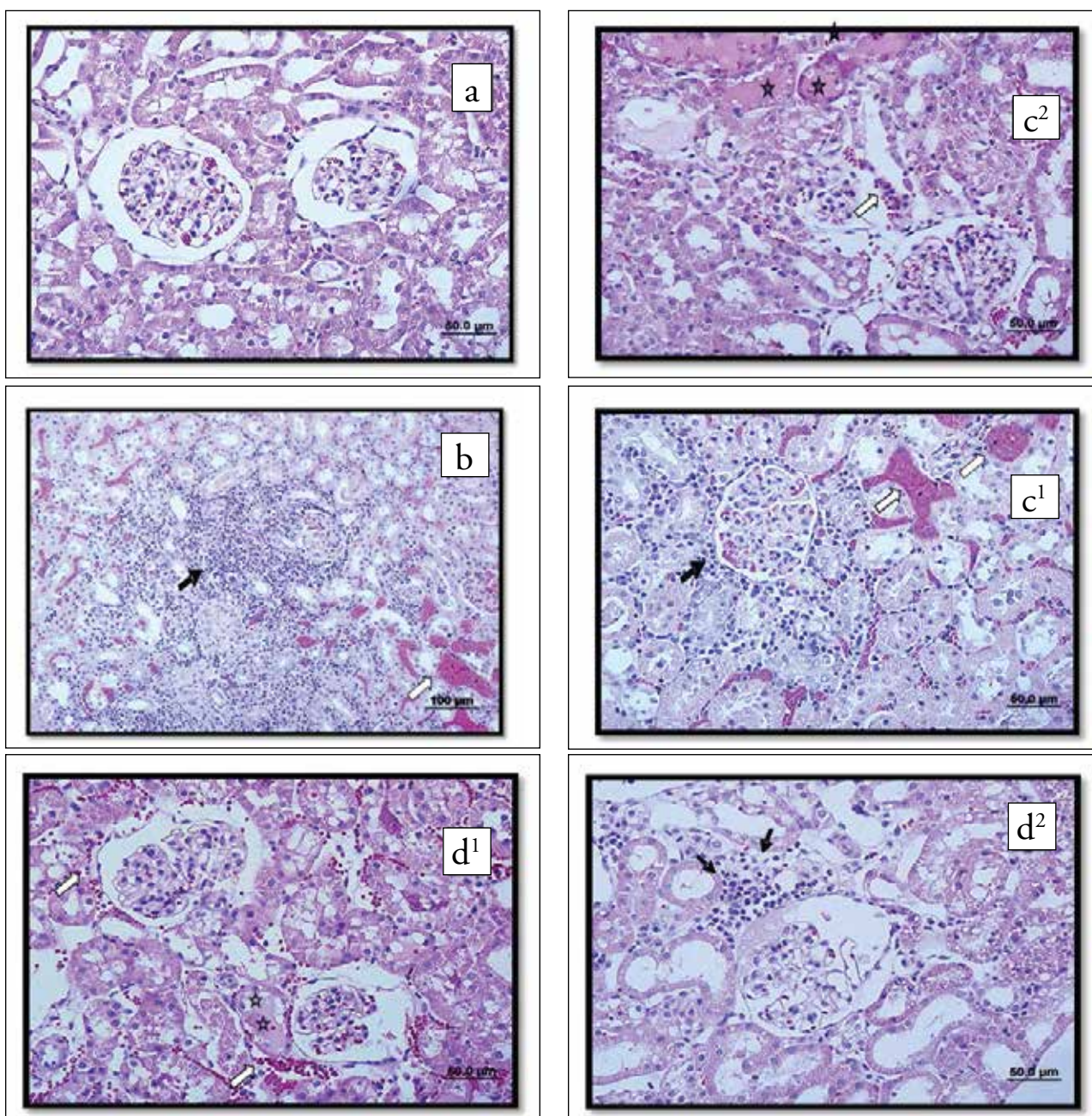


Figure 5. a-d. (a) Images of renal cortex specimens from Sham group stained with H&E (X40). (b) Images of renal tissue collected from IR group, stained with H&E (→) MNL infiltration, (⇨) erythrocyte extravasation (X20, X40). (c) Renal tissue samples from DIPC + IR group stained with H&E (⇨) MNL infiltration, (→) erythrocyte extravasation, (\*) tubular changes (X40). (d) Images of renal tissue collected from RIPC+IR group, stained with H&E (⇨) MNL cell infiltration, (→) erythrocyte extravasation, (\*) tubular changes

**Histopathologic renal damage score**  
**Structural changes of proximal tubules**

Histopathological scores of the sham group were significantly lower compared to the IR, DIPC+IR and RIPC+IR groups, when the sham ( $0.00 \pm 0.00$ ), IR ( $2.42 \pm 0.53$ ), DIPC+IR ( $1.57 \pm 0.53$ ) and RIPC+IR ( $1.42 \pm 0.53$ ) groups were analysed ( $p < 0.01$ ). Scores of the IR, DIPC+IR and RIPC+IR groups were found to be significantly different ( $p < 0.05$ ).

Scores of the IR group were detected to be significantly higher when compared to the DIPC+IR group and RIPC+IR

group ( $p < 0.05$ ), while there was no significant difference between the DIPC+IR group and RIPC+IR group (Figure 1).

**Mononuclear cell infiltration**

Histopathological scores of the sham group were significantly lower compared to IR, DIPC+IR and RIPC+IR groups when sham ( $0.14 \pm 0.37$ ), IR ( $2.57 \pm 0.53$ ), DIPC+IR ( $1.85 \pm 0.37$ ) and RIPC+IR ( $1.42 \pm 0.53$ ) group scores were analysed ( $p < 0.01$ ). Statistically significant difference was observed when the scores of the IR, DIPC+IR and RIPC+IR groups were compared ( $p < 0.01$ ). Scores of the IR, DIPC+IR and

RIPC+IR groups were compared, and the IR group scores were significantly higher ( $p<0.05$ ,  $p<0.01$ , respectively), while no significant difference was observed between the DIPC+IR and RIPC+IR groups (Figure 2).

### Erythrocyte extravasation

Histopathological scores of the sham group were significantly lower compared to the IR, DIPC+IR and RIPC+IR groups when sham ( $0.42\pm 0.53$ ), IR ( $2.57\pm 0.53$ ), DIPC+IR ( $2.14\pm 0.37$ ) and RIPC+IR ( $1.57\pm 0.53$ ) groups scores were analysed ( $p<0.01$ ). A statistically significant difference was observed when the scores of the IR, DIPC+IR, and RIPC+IR groups were compared ( $p<0.05$ ). No significant difference was detected between the IR and DIPC+IR groups, and on the other hand, a significant difference was observed between the IR group and DIPC+IR group, and between the DIPC+IR group and RIPC+IR group ( $p<0.05$ ) (Figure 3).

### Structural changes in interstitial spaces

Histopathological scores of the sham group were significantly lower compared to the IR, DIPC+IR and RIPC+IR groups when sham ( $0.00\pm 0.00$ ), IR ( $1.42\pm 0.53$ ), DIPC+IR ( $1.28\pm 0.48$ ) and RIPC+IR ( $1.28\pm 0.48$ ) group scores were analysed ( $p<0.01$ ). A statistically significant difference was observed when the scores of the IR, DIPC+IR and RIPC+IR groups were compared. A statistically significant difference was not observed when the scores of the IR, DIPC+IR and RIPC+IR groups were compared. No significant difference was observed between the DIPC+IR and RIPC+IR groups (Figure 4).

Cellular infiltration of any kind and the brush-border loss were not observed on the kidney sections obtained from the sham group (Figure 5a).

The MNL filtration, brush-border loss of proximal tubular cells, vasodilatation of cortical vessels and erythrocyte extravasation in the peritubular area specifically intensified in the cortical region were observed in the IR group. Tubular atrophy, tubular dilatation and vacuolization of proximal tubules were rarely seen in some areas.

Cellular debris in the tubular lumen along with proteinaceous substance collection was observed in some of the tubules (Figure 5b).

A decrease in the MNL filtration in the cortical area, especially the peritubular region, and the brush-border loss of proximal tubules in DIPC+IR group was observed, while on the other hand, erythrocyte extravasation in the cortex was not observed compared to the IR group.

Tubular atrophy in proximal tubules, tubular dilatation, vacuolization with proteinaceous substance deposition in the tubules, and cellular debris in tubular lumen that were seen in the IR group were observed to be reduced when compared to the DIPC+IR group (Figure 5c).

A decrease in the MNL infiltration in the cortical area, especially in the peritubular region, the brush-border loss of proximal tubules, and erythrocyte extravasation in the cortex in the RIPC+IR group was observed. On the other hand, only erythrocyte extravasation was observed to be less in the RIPC+IR group compared to the DIPC+IR group.

Tubular atrophy in the proximal tubules, tubular dilatation and vacuolization with the proteinaceous substance deposition in the tubules and cellular debris in tubular lumen that are seen in the IR group were observed to be less when compared to the RIPC+IR group (Figure 5d).

## Discussion

In this experimental study, it was histopathologically demonstrated that RIPC and DIPC reduce IR damage to the kidneys in the rat renal IR model, and RIPC, which had improved three out of four measured parameters, is more efficient compared to DIPC, which had improved two out of four parameters.

Ischaemia is commonly seen, especially in vascular and transplantation surgery. The energy supply and the removal of toxic metabolites are maintained with reperfusion. But the return of toxic metabolites to the systemic perfusion causes severe metabolic outcomes, and reperfusion aggravates local tissue damage. Reperfusion of ischaemic tissue results with myonephropathic metabolic syndrome, which is a group of systemic problems characterised by metabolic acidosis, hyperkalaemia, myoglobinaemia, myoglobulinurea and renal insufficiency (19). Toxic products emerging with multiple mechanisms activated with reperfusion damage distant organs, first the lungs, then the heart, brain and liver, and they might cause a multiple-organ failure that can lead to a long-term intensive care monitoring (20, 21).

Different ischaemia and reperfusion intervals were applied in the formation of experimental renal IR damage models. Williams et al. (22) collected blood and tissue samples at 0, 0.5, 1, 2, 4, 6, 9, 24 hours and 1 week after reperfusion for their study in which they obtained ischaemia by clamping the renal artery and vein for 45 minutes. Cochrane et al. (23) collected blood and tissue samples after 24 hours post-reperfusion for their study, in which they evaluated different regimens for IPC and obtained ischaemia by clamping the renal pedicle for 45 minutes.

Islam et al. (7) applied reperfusion for 9 days after 20 and 40 minutes of ischaemia in their study, and they also compared groups in which IPC was performed and in those that it was not performed. These researchers stated that 20 minutes is too short, and 40 minutes is ideal for the studies investigating the IPC efficiency.

In this study, 45 minutes of ischaemia followed by 4 hours of reperfusion, the shortest interval when renal damage is ob-



served, was preferred for observing the efficiency of IPC as Williams et al. (22) and Cochrane et al. (23) did in their studies.

The IPC, which is one of the methods for preventing the IR damage to the kidney, has been applied with various techniques, and it was demonstrated that it is efficient in the prevention of IR damage (8, 23, 24). The mechanism of the IPC protector effect in IR damage is still unknown.

Ischaemic preconditioning reduces the secretion of proinflammatory cytokines, which are secreted from the ischaemic tissue, by decreasing endothelial dysfunction and inhibiting P-selectin augmentation induced by TNF (25, 26). Adenosine A1 receptors (27), opioid receptors (15), protein kinase C activation (28) and the HSP synthesis (29, 30) also play a role in the protective effect of preconditioning.

The protective effects of IPC are also related to the duration of ischaemia, number of IR cycles, pattern of application of the cycles (intermittent or constant), direct or iRIPC, location of indirect preconditioning and the target organ. Fan-zhu et al. (31) inspected the effects of the IPC protocols repeated one, two or three times on renal IR damage in their study that was conducted on dogs. They reported that the renal blood flow and urine output recovery was significantly shorter in the three-cycles group compared to the one-and two-cycles groups, and the levels of adenosine, inosine, hypoxanthine, xantine and uric acid were lower in the three-cycles group compared to one-and two-cycles groups and non-IPC group. Toosy et al. (8) reported that the IPC protocol performed as four cycles of 4 minutes of ischaemia and 11 minutes of reperfusion, 5 minutes before the 40 minutes prolonged ischaemia, significantly improves the functional protection in kidneys. Islam et al. (7) did not observe any protective effect even although they used the same IPC protocol. The reason for this was the IPC application 30 minutes before IR, and the protective efficiency of IPC progressively declines if the interval which is named as the critical interval between the IPC and prolonged ischaemia is long. In a study conducted on rabbits, the critical interval was prolonged to 1 hour from 10 minutes, and the rate of myocardial infarction declined to 45% from 84%, but no decrease was observed when the interval was 2 hours (32).

We performed 4-minute ischaemia and 11-minute reperfusion based on a 5-minute critical interval, which is accepted as the optimal time to avoid renal damage caused by the model itself, and applied the IPC protocol as four cycles (7, 8).

We established that the IPC model reduces renal IR damage significantly by reducing structural changes in the proximal tubules and mononuclear cell infiltration, which is similar to the results by Toosy et al. (8) and different from the study by Islam et al. (7).

Remote ischaemic preconditioning, performed by Przyklenk et al. (33) for the first time, was shown to improve the coronary artery perfusion, and the incident was called RIPC.

Ates et al. (34), in the study that inspected the effects of hepatic IPC on renal IR damage, evaluated renal histopathology at 45 minutes and 24 hours after reperfusion and reported that the findings were significantly lower after 45 minutes in the group that was applied RIPC and that at 24 hours, histological findings were almost normal. We also determined like Ates et al. (34) that the results were supporting that RIPC has effects on renal IR damage.

Küntschler et al. (35) reported that to obtain temporary ischaemia a non-invasive tourniquet application might be an alternative instead of direct cessation of blood flow for RIPC. Saita et al. (17) stated that the most effective IPC method to prevent skeletal muscle IR damage is three cycles of 10 minutes ischaemia and 10 minutes of reperfusion. Olguner et al. (3) demonstrated that the RIPC performed with the one-sided hind foot tourniquet method before the IR model has decreased the histological score of lung damage and lipid peroxydation. Sahin et al. (21) evaluated the liver IR damage after three cycles of RIPC performed with the hind-foot tourniquet method, and it was shown that RIPC had reduced serum transaminase levels and liver histological damage scores compared to DIPC. Wever et al. (14) demonstrated for the first time for renal IR that the non-invasive RIPC model with the one- or two-sided hind leg tourniquet method is effective. Ulus et al. (36) showed that different preconditioning methods may play an important role in distinct organ injuries during aortic cross-clamping. According to their results, preconditioning has a major effect on renal IR injury.

However, different from our study, they found that the best results on renal congestion were in direct preconditioning group. This difference may be related to different renal ischaemia models in these studies.

In our study, differing from other researchers, we investigated and compared the effects of DIPC and 10 minutes of the RIPC model on the one-side hind leg. It was detected that both methods reduced IR damage and that RIPC was histopathologically more effective than DIPC.

In the studies conducted, congestion, tubular dilatation, tubular atrophy, degeneration, eosinophilic casts and necrosis were observed in the renal histopathology investigations after IR (22, 23). In this study, proximal tubular structural changes, tubular atrophy, tubular brush-border loss, tubular dilatation, cast formation, vacuolization, the MNL infiltration, erythrocyte extravasation, renal corpuscle morphology and interstitial space structural changes were observed to be lower in the sham group compared to the other three groups when renal histopathology was inspected with a light microscope.

Especially intensified in the cortical region in the peritubular area, the MNL infiltration, proximal tubular brush-border loss, cortical vessel vasodilatation, rich erythrocyte extravasation, rare tubular atrophy, tubular dilatation and vacuolization were seen in the IR group, but a significant difference was not found when compared to the DIPC+IR and RIPC+IR groups; on the other hand, the DIPC+IR and RIPC+IR groups were not significantly different, except for erythrocyte extravasation. Histologic investigations with light microscopy were determined as semi-quantitative scoring (3). In this study, it was concluded that RIPC represses the histopathologic renal damage score better than DIPC.

Reperfusion mechanism along with the protective mechanisms is very complicated. Even though the effects of preconditioning were defined two decades ago, intervening pathways are still not fully understood. It is reported that IPC applied directly to the organ is not easily performed in vital organ surgeries, that it primarily might endanger the target organ, and that it secondarily might prolong the operation time and increase the bleeding (37).

Remote ischaemic preconditioning might be used as an easily applied non-invasive clinical method which causes no added stress to the kidney, without increasing the procedure duration or bleeding. We have not come across any studies comparing DIPC and RIPC in our literature investigations in PubMed and other available resources.

As limitations to this study, we list the histopathologic evaluation only without the investigation of biochemical parameters, such as renal function tests, tissue myeloperoxidase and longer reperfusion times (24 hours).

## Conclusion

Direct ischaemic preconditioning and RIPC were both shown to decrease the renal IR damage score histopathologically, but RIPC was found to be more efficient than DIPC. It was concluded that further studies about the efficiency and mechanisms of these two methods are required.

**Ethics Committee Approval:** Ethics committee approval was received for this study from the Dokuz Eylul University Faculty of Medicine Animal Experiments Local Ethical Committee (date 30.04.2010, 25/2010 protocol no).

**Peer-review:** Externally peer-reviewed.

**Author Contributions:** Concept – M.A., K.O.; Design – M.A., Ç.O.; Supervision – S.Ö., Ç.O.; Resources – N.B.; Materials – H.F.; Data Collection and/or Processing – M.E.G., B.U.E.; Analysis and/or Interpretation – N.B., M.A., S.Ö.; Literature Search – K.O.; Writing Manuscript – K.O., M.A.; Critical Review – Ç.O., M.A., S.Ö.

**Conflict of Interest:** The authors have no conflicts of interest to declare.

**Financial Disclosure:** The authors declared that this study has received no financial support.

**Etik Komite Onayı:** Bu çalışma için etik komite onayı Hayvan Deneyleri Yerel Etik Kurulu'ndan (tarih 30.04.2010, 25/2010 protokol no) alınmıştır.

**Hakem Değerlendirmesi:** Dış bağımsız.

**Yazar Katkıları:** Fikir – M.A., K.O.; Tasarım – M.A., Ç.O.; Denetleme – S.Ö., Ç.O.; Kaynaklar – N.B.; Malzemeler – H.F.; Veri Toplanması ve/veya İşlemesi – M.E.G., B.U.E.; Analiz ve/veya Yorum – N.B., M.A., S.Ö.; Literatür Taraması – K.O.; Yazıyı Yazan – K.O., M.A.; Eleştirel İnceleme – Ç.O., M.A., S.Ö.

**Çıkar Çatışması:** Yazarlar çıkar çatışması bildirmemişlerdir.

**Finansal Destek:** Yazarlar bu çalışma için finansal destek almadıklarını beyan etmişlerdir.

## References

1. Collard CD, Gelman S. Pathophysiology, clinical manifestations and preventions of ischemia-reperfusion injury. *Anesthesiology* 2001; 94: 1133-8. [CrossRef]
2. Huang SS, Wei FC, Hung LM. Ischemic preconditioning attenuates postischemic leukocyte - endothelial cell interactions role of nitric oxide and protein kinase C. *Circ J* 2006; 70: 1070-5. [CrossRef]
3. Olguner C, Koca U, Kar A, Karci A, İşlekel H, Canyilmaz M, et al. Ischemic preconditioning attenuates the lipid peroxidation and remote lung injury in the rat model of unilateral lower limb ischemia reperfusion. *Acta Anaesthesiol Scand* 2006; 50: 150-5. [CrossRef]
4. Murry CE, Jennings RB, Reimer KA. Preconditioning with ischemia: a delay of lethal cell injury in ischemic myocardium. *Circulation* 1986; 74: 1124-36. [CrossRef]
5. Laurikka J, Zhong-Kai W, Lisalo P, Kaukinen L, Honkonen EL, Kaukinen S, et al. Regional ischemic preconditioning enhances myocardial performance in off-pump coronary artery bypass grafting. *Chest* 2002; 121: 1183-9. [CrossRef]
6. Takaoka A, Nakae I, Mitsunami K, Yabe T, Morikawa S, Inubushi T, et al. Renal ischemia/reperfusion remotely improves myocardial energy metabolism during myocardial ischemia via adenosine receptors in rabbits: effects of "remote preconditioning". *J Am Coll Cardiol* 1999; 33: 556-64. [CrossRef]
7. Islam CF, Mathie RT, Dinneen MD, Kiely EA, Peters AM, Grace PA. Ischaemia-reperfusion injury in the rat kidney: the effect of preconditioning. *Br J Urol* 1997; 79: 842-7. [CrossRef]
8. Toosy N, McMorris ELJ, Grace PA, Mathie RT. Ischaemic preconditioning protects the rat kidney from reperfusion injury. *BJU Int* 1999; 84: 489-94. [CrossRef]
9. Papanastasiou S, Estdale SE, Homer-Vanniasinkam S, Mathie RT. Protective effect of preconditioning and adenosine pretreatment in experimental skeletal muscle reperfusion injury. *Br J Surg* 1999; 86: 916-22. [CrossRef]
10. Soncul H, Oz E, Kalaycioglu S. Role of ischemic preconditioning on ischemiareperfusion injury of the lung. *Chest* 1999; 115: 1672-7. [CrossRef]



11. Davis JM, Gute DC, Jones S, Krsmanovic A, Korthuis RJ. Ischemic preconditioning prevents postischemic P-selectin expression in the rat small intestine. *Am J Physiol* 1999; 277: 2476-81. [\[CrossRef\]](#)
12. Peralta C, Prats N, Xaus C, Gelpi E, Roselló-Catafau J. Protective effect of liver ischemic preconditioning on liver and lung injury induced by hepatic ischemia-reperfusion in the rat. *Hepatology* 1999; 30: 1481-9. [\[CrossRef\]](#)
13. Heurteaux C, Lauritzen I, Widmann C, Lazdunski M. Essential role of adenosine, adenosine A1 receptors, and ATP-sensitive K<sup>+</sup> channels in cerebral ischemic preconditioning (fore-brain ischemia/gene expression). *Proc Natl Acad Sci USA* 1995; 92: 4666-70. [\[CrossRef\]](#)
14. Wever KE, Warle MC, Wagener FA, van der Hooij JW, Masereeuw R, van der Vliet JA, et al. Remote ischemic preconditioning by brief hind limb ischemia protects against renal ischemia-reperfusion injury: the role of adenosine. *Nephrol Dial Transplant* 2011; 26: 3108-17. [\[CrossRef\]](#)
15. Wever KE, Masereeuw R, Wagener FA, Verweij VG, Peters JG, Pertijs JC, et al. Humoral signalling compounds in remote ischaemic preconditioning of the kidney, a role for the opioid receptor. *Nephrol Dial Transplant* 2013; 28: 1721-32. [\[CrossRef\]](#)
16. Strock PE, Majno G. Vascular responses to experimental tourniquet ischemia. *Surg Gynecol Obstet* 1969; 129: 309-18.
17. Saita Y, Yokoyama K, Nakamura K, Itoman M. Protective effect of ischemic preconditioning against ischemia-induced reperfusion injury of skeletal muscle: how many preconditioning cycles are appropriate? *Br J Plast Surg* 2002; 55: 241-5.
18. Fujii T, Takaoka M, Muraoka T, Kurata H, Tsuruoka N, Ono H, et al. Preventive effect of L-carnosine on ischemia/reperfusion-induced acute renal failure in rats. *Eur J Pharmacol* 2003; 474: 261-7. [\[CrossRef\]](#)
19. Grace PA. Ischemia-reperfusion injury. *Br J Surg* 1994; 81: 637-47. [\[CrossRef\]](#)
20. Carden DL, Granger DN. Pathophysiology of ischemia-reperfusion injury. *J Pathology* 2000; 190: 255-66. [\[CrossRef\]](#)
21. Şahin E, Olguner Ç, Bodur HA, Koca U, Tuncel P, Örmen M, et al. Comparison of the effects of remote and direct ischemic preconditioning on liver reperfusion injury. *Turkiye Klinikleri J Med Sci* 2009; 29: 381-7.
22. Williams P, Lopez H, Britt D, Chan C, Ezrin A, Hottendorf R. Characterization of renal ischemia-reperfusion injury in rats. *J Pharmacol Toxicol Methods* 1997; 37: 1-7. [\[CrossRef\]](#)
23. Cochrane J, Williams BT, Banerjee A, Harken AH, Burke TJ, Cairns CB, et al. Ischemic preconditioning attenuates functional, metabolic, and morphologic injury from ischemic acute renal failure in the rat. *Ren Fail* 1999; 21: 135-45. [\[CrossRef\]](#)
24. Riera M, Herrero I, Torras J, Cruzado JM, Fatjo M, Lloberas N, et al. Ischemic preconditioning improves postischemic acute renal failure. *Transplant Proc* 1999; 31: 2346-7. [\[CrossRef\]](#)
25. Kharbanda Kharbanda RK, Peters M, Walton B, Kattenhorn M, Mullen M, Klein N, et al. Ischemic preconditioning prevents endothelial injury and systemic neutrophil activation during ischemia-reperfusion in humans in vivo. *Circulation* 2001; 103: 1624-30. [\[CrossRef\]](#)
26. Peralta C, Fernandez L, Panes J, Prats N, Sans M, Pique JM, et al. Preconditioning protects against systemic disorders associated with hepatic ischemia-reperfusion through blockade of tumor necrosis factor-induced P-selectin upregulation in the rat. *Hepatology* 2001; 33: 100-13. [\[CrossRef\]](#)
27. Neely CF, Keith IM. A1 adenosine receptor antagonists block ischemia-reperfusion injury of the lung. *Am J Physiol* 1995; 268: L1036-46.
28. Baxter GF, Gona FM, Yellon DM. Involvement of protein kinase C in the delayed cytoprotection following sublethal ischaemia in rabbit myocardium. *Br J Pharmacol* 1995; 115: 222-4. [\[CrossRef\]](#)
29. Marber MS, Latchman DS, Walker JM, Yellon DM. Cardiac stress protein elevation 24 hours after brief ischemia or heat stress associated with resistance to myocardial infarction. *Circulation* 1993; 88: 1264-72. [\[CrossRef\]](#)
30. Marber MS, Mestral R, Chi SH, Sayen MR, Yellon DM, Dillmann WH. Overexpression of the rat inducible 70-kD heat stress protein in a transgenic mouse increases the resistance of the heart to ischemic injury. *J Clin Invest* 1995; 95: 1446-56. [\[CrossRef\]](#)
31. Fan-zhu LI, Kimura S, Nishiyama A. Ischemic preconditioning protects post-ischemic renal function in anesthetized dogs: role of adenosine and adenine nucleotides. *Acta Pharmacologica Sinica* 2005; 26: 851-9. [\[CrossRef\]](#)
32. Van Winkle DM, Thornton J, Downey JM. The natural history of preconditioning: cardioprotection depends on duration of transient ischemia and time to subsequent ischemia. *Coron Artery Dis* 1991; 2: 613-9.
33. Przyklenk K, Bauer B, Ovize M, Kloner RA, Whittaker P. Regional ischemic 'preconditioning' protects remote virgin myocardium from subsequent sustained coronary occlusion. *Circulation* 1993; 87: 893-9. [\[CrossRef\]](#)
34. Ates E, Genc E, Erkasap N, Erkasap S, Akman S, Firat P, et al. Renal protection by brief liver ischemia in rats. *Transplantation* 2002; 74: 1247-51. [\[CrossRef\]](#)
35. Küntscher MV, Kastell T, Sauerbier M, Nobiling R, Gebhard MM, Germann G. Acute remote ischemic preconditioning on a rat cremasteric muscle flap model. *Microsurgery* 2002; 22: 221-6. [\[CrossRef\]](#)
36. Ulus AT, Yavas S, Sapmaz A, Sakaogullari Z, Simsek E, Ersoz S, et al. Effect of conditioning on visceral organs during indirect ischemia/reperfusion injury. *Ann Vasc Surg* 2014; 28: 437-44. [\[CrossRef\]](#)
37. Lai R, Chang K, Chen C, Tsai H. Transient limb ischemia induces remote preconditioning in liver among rats: The protective role of Heme Oxygenase-1. *Transplantation* 2006; 81: 1311-31. [\[CrossRef\]](#)