



Research Article

Results of Radiofrequency Ablation of Inferior Turbinate Hypertrophy in Patients with Allergic and Non-Allergic Rhinitis

Bilge Türk, Arzu Yasemin Korkut, Kerem Sami Kaya, Egehan Salepçi,
 Özlem Ünsal, Berna Uslu Coşkun, Suat Turgut

Department of Otorhinolaryngology Head and Neck Surgery, Şişli Hamidiye Etfal Training and Research Hospital, İstanbul, Turkey

Abstract

Objectives: For the treatment of the inferior turbinate hypertrophy that is unresponsive to medical treatment, turbinate surgery with radiofrequency is a widely used method. This study aims to evaluate the efficacy of turbinate surgery with radiofrequency ablation for the treatment of turbinate hypertrophy, and compare the results of patients with allergic rhinitis and non-allergic rhinitis.

Methods: A total of 59 consecutive patients aged 18–67 years (mean 37±13) who underwent radiofrequency ablation to the inferior turbinate at our tertiary care hospital from September 2017 to January 2018 were enrolled in this prospective nonrandomized clinical study. The patients with allergic rhinitis (n=23) were classed as group 1, and the patients with non-allergic rhinitis (n=36) were classed as group 2. Endoscopic nasal examination and an acoustic rhinometer were applied, and a standard 0–10 visual analog scale (VAS) was used to assess nasal symptoms preoperatively and postoperatively at the third and sixth months.

Results: The study found a significant reduction in nasal obstruction for both groups postoperatively. This reduction was higher in group 1. The decrease in nasal VAS scores for itching, rhinorrhea, and sneezing were statistically significant in group 1, whereas the decrease in nasal VAS scores for sneezing was significant in group 2.

Conclusion: This study demonstrates that radiofrequency appears to be an effective and safe treatment option for inferior turbinate hypertrophy of patients with allergic rhinitis or non-allergic rhinitis. It also provides a better perception of all nasal symptoms in patients with allergic rhinitis, and a better perception of nasal obstruction and sneezing in patients with non-allergic rhinitis.

Keywords: Allergic rhinitis; nasal turbinate; non-allergic rhinitis; radiofrequency.

Please cite this article as "Türk B, Korkut AY, Kaya KS, Salepçi E, Ünsal Ö, Uslu Coşkun B, et al. Results of Radiofrequency Ablation of Inferior Turbinate Hypertrophy in Patients with Allergic and Non-Allergic Rhinitis. Med Bull Sisli Etfal Hosp 2018;52(4):296–301".

Inferior turbinate hypertrophy (ITH) is one of the most common causes of chronic nasal obstruction. It can be persistent in cases such as allergic rhinitis, vasomotor rhinitis, and compensatory hypertrophy due to septal deviation.^[1–3] Intractable nasal blockage due to inferior turbinate hypertrophy interferes with the nasal functions. Medical treatments such as antihistamines, systemic decongestants, or intranasal sprays have been used for the hypertrophy, but they are often ineffective.^[4, 5] Many turbinate

surgery procedures such as partial or total turbinectomy, electrocautery, and cryosurgery have been performed in cases where conservative medical treatment has failed.^[6–8]

Radiofrequency ablation (RFA) is safe and efficient. In recent years, it has become a widely used procedure for the surgical reduction of the inferior turbinate.^[9, 10] In cases where RFA is used, overlying mucosa is spared, and operative morbidity is low. RFA has also been demonstrated as an effective and safe tool to treat allergic rhinitis refractory to

Address for correspondence: Bilge Türk, MD. Şişli Hamidiye Etfal Eğitim ve Araştırma Hastanesi, Kulak Burun Boğaz ve Baş Boyun Cerrahisi, İstanbul, Turkey

Phone: +90 532 286 82 13 **E-mail:** drbilgeturk@hotmail.com

Submitted Date: September 11, 2018 **Accepted Date:** November 09, 2018 **Available Online Date:** December 28, 2018

©Copyright 2018 by The Medical Bulletin of Sisli Etfal Hospital - Available online at www.sislietfaltip.org

This is an open access article under the CC BY-NC-ND license (<http://creativecommons.org/licenses/by-nc/4.0/>).



medical therapy, and it can significantly improve the symptoms of allergic rhinitis.^[11, 12]

In this study, we aimed to evaluate the efficacy of turbinate surgery with RFA for the treatment of persistent turbinate hypertrophy. We also aim to compare the results for patients with allergic rhinitis and non-allergic rhinitis.

Methods

Participants

A total of 59 patients (37 female, 22 male) aged 18–67 years (mean 37±13) were enrolled in this nonrandomized prospective clinical study. The patients had RFA turbinate surgery at the Otorhinolaryngology Head and Neck Surgery Clinic of Sisli Hamidiye Etfal Training and Research Hospital between September 2017 and January 2018. The patients who had rhinitis and ITH bilaterally that was unresponsive to medical treatment lasting at least 3 months and who accordingly underwent inferior turbinate RFA surgery were included in this prospective study. Patients aged below 18 years and those with a history of previous turbinate surgery, those with severe septal deviation and nasal polyposis, and those with a history of chronic sinusitis were excluded from the study. Those who had not received medical treatment for inferior turbinate hypertrophy were also excluded.

Written informed consent was obtained from all the participants. The research plan was approved by the institutional research committee and the local medical ethics committee (26.12.2017; 1841). All aspects of the study were conducted according to the Declaration of Helsinki.

All the patients underwent a skin prick test. The patients were divided into two groups. Those who had a positive skin prick test for inhalant allergens, numbering 23 patients (15 female, 8 male; aged 18–60 years, mean age 18±12 years) were classed as group 1. Moreover, 36 patients (22 female, 14 male; aged 24–67 years, mean age 40±12 years) who had a negative skin prick test were classed as group 2.

Evaluation

Objective evaluations of the intranasal findings were conducted by anterior rhinoscope, and endoscopic examination was conducted with a 4 mm, 0° endoscope (Karl Storz GmbH&Co., Tuttlingen, Germany) by the same surgeon to minimize any intraobserver difference. The degree of the nasal obstruction due to ITH of the each cavity was observed, and it was noted separately before and after the third and sixth months of the RFA of the inferior turbinate. The obstruction degree was numbered from 1 to 4; 1 indicating 0%–25% obstruction, 2 indicating 25%–50% obstruction, 3 indicating 50%–75% obstruction, and 4 indicating 75%–100% obstruction.

Acoustic rhinometry via RhinSCAN SRE2000 (RhoMetrics A/S, Lyngø, Denmark) was performed for each individual in the standardized form. The same researcher measured the cross-sectional areas and volumes of the nasal cavity before and after the third and sixth months of turbinate surgery. A graph of the nasal cross-sectional area as a function of distance from the nostril was produced. Several area and volume estimates of the nasal cavity were derived from this graph. The minimum cross-sectional area from the nostril to 2.20 cm into the nasal cavity was referred to as MCA1, and the minimum cross-sectional area from 2.20 cm to 5.40 cm was referred to as MCA2. The minimum cross-sectional volume 1 (VOL1) and minimum cross-sectional volume 2 (VOL2) were measured from 0 to 2.20 cm and from 2.20 to 5.40 cm, respectively.

A standard 0–10 visual analog scale (VAS) (0 representing no symptoms and 10 representing the most severe symptoms) was used to assess subjective nasal symptoms, including nasal obstruction, itchy nose, rhinorrhea, and sneezing, preoperatively and postoperatively at the third and sixth months. Under the observation of the same senior surgeon of the clinic, the nasal symptom scores were marked by the patients preoperatively and postoperatively at the third and sixth months.

Surgical Procedure

All surgical procedures were performed under local anesthesia by the same senior surgeon using the same technique. Topical lidocaine spray (two puffs per nostril) to both nasal mucosal surfaces, and injection of 2 mL of 40 mg lidocaine HCl with 0.025 mg adrenaline diluted with 2 mL of 0.9% NaCl, using a 22 G × 32 mm dental injector was given into the anterior portion of each inferior turbinate for local anesthesia. The regulation and monitoring of the entire soft-coagulation process were conducted via the radiofrequency generator (CelonLabENT; Celon AG, Teltow, Germany). Under endoscopic guidance, a conchal probe (CelonProBreath, Celon AG, Teltow, Germany) was placed submucosally within the anterior, middle, and posterior one-third of the each inferior turbinate. To each turbinate, the energy delivered for one shot was 12 W, and 300 J of energy was supplied for 7–8 s. Outfracturing of the inferior turbinate was not performed. After surgery, each patient was discharged without any limitation of normal daily activities. No nasal packing was applied, and no nasal spray, antihistamines, or analgesics were prescribed.

Follow-up

During their postoperative visit to the outpatient clinic at the third and sixth months, nasal endoscopic examination, nasal symptom VAS scores, and history of adverse reactions,

Table 1. The demographic distribution of the group 1 and group 2

	Group 1 (n=23)		Group 2 (n=36)		p
	Mean±SD	Min.-Max.	Mean±SD	Min.-Max.	
Age	32.7±12.7	18-60	40.2±12.5	24-67	0.022
Sex					0.750
Male	8	34.8	14	38.9	
Female	15	65.2	22	61.1	

SD: Standard deviation; Min.: Minimum; Max.: Maximum.

including nasal infection, crusts, dryness, and nasal bleeding during the postoperative period at home, were recorded by the senior surgeon examining the patient. Acoustic rhinometer measures were performed at the third and sixth months. Postoperative follow-up ranged from 6 to 8 months. Data collected from the two groups were compared.

Statistical Analysis

The Windows Statistical Package for the Social Sciences program (version 15.0, IBM Corp., Chicago, Illinois, USA, 2008) was used for statistical analysis. Number and percentage were used as descriptive statistics for categorical variables, while mean, standard deviation, minimum, maximum, and median were used for numerical variables. When numerical variables yielded a normal distribution condition, independent two-group comparisons were made by the Student's t-test. The Mann-Whitney U test was used when normal distribution was not satisfied. When the differences in the numerical variables did not produce a normal distribution, the dependent multiple group analyses were performed by the Friedman analysis. Subgroup analyses were performed using the Wilcoxon test and interpreted by Bonferroni correction. Paired t-test was used when the difference in the numerical variables in the two dependent groups produced a normal dispersion condition, while Wilcoxon analysis was performed when the normal dispersion condition was not satisfied. The ratios in the groups were tested by the chi-square analysis. A p value of <0.05 was considered to be statistically significant.

Results

Fifty-nine patients were divided into two groups. Those with allergic rhinitis were classed as group 1, consisting of 23 patients; those with non-allergic rhinitis were classed as group 2, consisting of 36 patients. There was no statistically significant difference in the sex ratios of the two groups, but the mean age of group 2 patients was statistically higher than that of group 1 patients (p=0.022) (Table 1). RFA was applied to both inferior turbinates of each patient, and in total 118 nasal cavities were analyzed. No adverse reactions such as nasal infection, crusts, adhesion, dryness, or nasal bleeding were encountered in either group. No analgesics were prescribed in the entire study.

Objective evaluation of nasal cavities by endoscopic examination

In both groups, the postoperative endoscopic examination revealed that there was a statistically significant decrease in nasal obstruction (p<0.001). A statistically significant decrease in the obstruction rate was detected at the postoperative sixth month in comparison to findings at the postoperative third month in group 1 (p<0.001). There was no statistically significant difference in the degree of nasal obstruction between the two groups preoperatively or at the postoperative third month (p=0.218 and p=0.922, respectively). However, the percentage of obstruction of the nasal cavity due to the inferior turbinate at the postoperative sixth month was significantly higher in group 1 than that in group 2 (p=0.004) (Table 2).

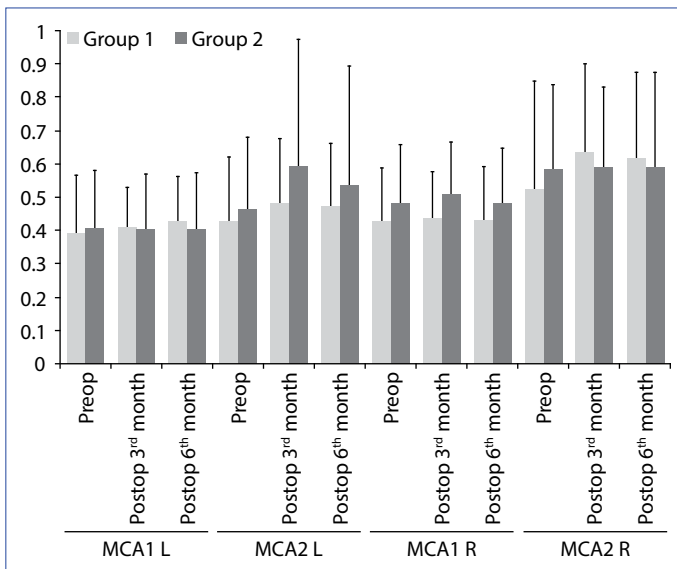
Objective evaluation of nasal cavities by acoustic rhinometry

The pre-ablation and post-ablation MCA1 and MCA2 and nasal volumes (VOL1 and VOL2) for each nasal cavity were compared. As shown in Figures 1 and 2, the post-ablation MCA1 L, MCA2 L, MCA2R, VOL 1 L, VOL 2 L, and VOL 2 R were higher when compared with the pre-ablation values in group 1. The differences between them were statistically significant (p=0.023, p=0.028, p<0.001, p<0.001, p=0.006,

Table 2. Nasal cavity obstruction percentage according to endoscopic examination of nasal cavities

	Group 1		Group 2		p
	Mean±SD	Median	Mean±SD	Median	
Nasal cavity obstruction (%)					
Preop	86.7±4.9	90	85.0±5.1	85	0.218
Postop third month	31.3±16.0	20	27.8±8.1	30	0.922
Postop sixth month	38.7±15.2	30	27.2±7.6	30	0.004
p	<0.001		<0.001		

SD: Standard deviation.



Figur 1. Demonstration of the changes in the left and right mean cross-sectional area 1 and 2 (MCA1-2 L, MCA1-2 R) before and after the reduction of the inferior turbinates. Data are presented as median, minimum, and maximum values.

$p < 0.001$), and these values were not statistically different in group 2. There was no statistically significant difference between the groups in terms of preoperative and postoperative MCA1 and MCA2 L-R values. On the other hand, when comparing the VOL1-2 of the right and left nasal cavities of the two groups, only the VOL1 R was significantly higher in group 1 when compared to VOL1 R in group 2 at the postoperative sixth month ($p = 0.032$).

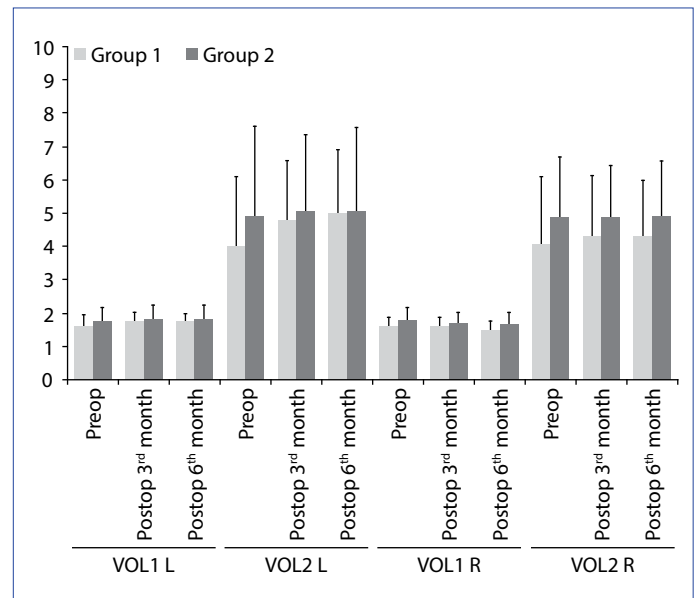
Subjective evaluation of nasal symptoms

There was a significant reduction in nasal VAS obstruction symptoms in both groups postoperatively at the third and sixth months ($p < 0.001$). There was no statistically significant difference in VAS scores for nasal obstruction preoperatively and postoperatively between the groups.

While the decrease in VAS scores of rhinorrhea and itching at the postoperative third and sixth months was statistically significant in group 1 ($p < 0.001$), the decrease in VAS scores for sneezing was statistically significant in both groups ($p < 0.001$) (Table 3).

Discussion

Nasal obstruction due to ITH causes morbidity, which affects the daily activity and hence quality of life of patients. Although medical treatments have been used for ITH, intractable nasal blockage still interferes with the nasal functions. In cases of rhinitis, especially such as allergic rhinitis and non-allergic rhinitis, ITH can be persistent.^[1-3] Besides medical treatments, surgical procedures have been performed to relieve the symptoms in cases that were refrac-



Figur 2. Illustration of the changes in the right and left nasal volumes (VOL1-2 R, VOL1-2 L) before and after the reduction of the inferior turbinates.

tory to medicines.^[13, 14] Nowadays, RFA is a commonly preferred surgical method to reduce the inferior turbinates.

The reduction in size of the inferior turbinates by RFA results in an enlargement of the nasal airway and also in a better perception of nasal symptoms. The focus of this study was to compare the qualitative improvement of nasal symptoms and acoustic rhinometer findings for patients with allergic rhinitis and patients with non-allergic rhinitis who had undergone bilateral inferior turbinate RFA surgery, and to determine whether there was a difference between them.

RFA turbinate surgery of ITP significantly reduces the nasal obstruction.^[13-16] In this study, both groups experienced a significant improvement in nasal obstruction VAS scores, which was compatible with the findings in the literature. There was no significant difference in the preoperative nasal obstruction VAS scores between the two groups. For both groups, relief of nasal obstruction persisted until the postoperative sixth month. Also, nasal endoscopic examination revealed a significant decrease in nasal obstruction.

In this study, a statistically significant improvement in rhinorrhea, itching, and sneezing symptoms was observed in group 1 postoperatively. On the other hand, there was no statistically significant difference in the VAS scores of rhinorrhea and itching postoperatively in group 2. Only a significant symptomatic improvement in sneezing was observed. It remains unclear how RFA turbinate surgery reduces rhinorrhea, itching, and sneezing symptoms in patients with allergic rhinitis and sneezing in patients with non-allergic

Table 3. The VAS scores of the nasal symptoms of the group 1 and group 2 at each follow-up time

	Group 1		Group 2		p
	Mean±SD	Median	Mean±SD	Median	
Nasal obstruction					
Preop	8.22±1.31	8	7.50±1.76	8	0.153
Postop third month	4.61±1.70	4	3.89±2.05	4	0.218
Postop sixth month	4.35±1.58	4	3.61±1.82	4.5	0.343
p	<0.001		<0.001		
Rhinorrhea					
Preop	7.09±2.09	8	3.11±2.93	1	<0.001
Postop third month	3.87±1.84	3	2.83±2.79	1	0.008
Postop sixth month	4.04±1.74	4	2.78±2.70	1	0.005
p	<0.001		0.456		
Nasal itching					
Preop	7.09±2.37	8	3.00±2.95	1	<0.001
Postop third month	3.65±2.84	3	2.17±1.83	1	0.045
Postop sixth month	3.48±2.57	3	2.06±1.80	1	0.023
p	<0.001		0.230		
Sneezing					
Preop	7.52±1.86	8	5.22±3.27	5.5	0.010
Postop third month	4.17±3.19	4	2.61±2.44	1.5	0.060
Postop sixth month	4.39±3.45	3	2.72±2.24	2	0.110
p	<0.001		<0.001		

VAS: Visual analog scale; SD: Standard deviation.

rhinitis. In some studies, the relief of sneezing after RFA was attributed to the destruction of the post-nasal nerve branches.^[12, 14, 17] However, posterior nasal nerve responsible for the innervation of nasal mucosa is distributed on the whole nasal mucosa, so it is strange that just turbinate reduction can have so striking results. Furthermore, it has been suggested that dysregulation of sympathetic, parasympathetic, and nociceptive nerves innervating the nasal mucosa and regulating the nasal mucosal vascularity and glandular secretion. The application of RF energy to inferior turbinate submucosa induces submucosal small vessel obliteration and mucosal gland destruction, circumferential scar formation that are considered to play major role for these beneficial effects of RFA.^[11, 12, 18, 19]

On the other hand, the mechanism of action of radiofrequency on the improved perception of itching and rhinorrhea and sneezing in patients with allergic rhinitis is not clear.

The acoustic rhinometer provides an objective measurement of cross-sectional areas in the nose. In this study, post-ablation AR parameters were significantly higher than the pre-ablation measurements in group 1, while there was no statistically significant difference in group 2. This was surprising because a statistically significant decrease was

observed in the post-ablation nasal obstruction VAS scores in group 2.

The reduction of the inferior turbinates with RFA seems to be effective, especially in patients with allergic rhinitis, not only for nasal obstruction but also for the reduction of the VAS scores of rhinorrhea, itching, and sneezing. Symptom scores statistically improved in patients with allergic rhinitis. Additionally, the AR measurements and nasal examination revealed an improvement in nasal obstruction. On the other hand, for patients with non-allergic rhinitis with İTH, RFA also seems to be effective for the relief of nasal obstruction and sneezing symptoms. Nasal endoscopic findings supported the improvement in nasal obstruction; however, the AR measurements were not statistically different in the non-allergic patients.

No adverse reactions, such as nasal infection, crusts, adhesion, dryness, or nasal bleeding, were encountered in either group. No analgesics were prescribed. These were the main advantages of treating İTH with the RFA method.

There are some limitations of this study. Owing to the strict exclusion criteria, only a limited number of cases were evaluated. Additionally, during the follow-up period, some of the participants left the study. Since the follow-up period ranged from 6 to 8 months, long-term results were not

available. Future investigations should be performed to assess the long-term results.

Conclusion

RFA of the inferior turbinate may somehow alter the allergic response and reduce nasal symptoms, such as nasal obstruction, rhinorrhea, itching, and sneezing, in patients with allergic rhinitis. RFA yielded a greater reduction in the perception of nasal obstruction and sneezing in patients with non-allergic rhinitis. The symptomatic response was better in patients with allergic rhinitis. RFA appeared to be effective and alternative treatment option for patients with allergic rhinitis for relief of nasal symptoms refractory to medical therapy.

Disclosures

Peer-review: Externally peer-reviewed.

Ethics Committee Approval: Written informed consent forms were obtained from all participants. The research plan was approved by the medical Ethics Committee of our hospital (26.12.2017/1841).

Financial Disclosure: There are no funding or financial relationships to disclose.

Conflict of Interest: There is no conflict of interest.

Authorship contributions: Concept – B.T., A.Y.K., B.U.C., S.T.; Design – B.T., A.Y.K., K.S.K., E.S., S.T., Ö.U.; Supervision – A.Y.K., B.U.C., S.T.; Materials – B.T., E.S., K.S.K., Ö.U.; Data collection &/or processing – B.T., K.S.K., E.S., Ö.U.; Analysis and/or interpretation – B.T., A.Y.K., K.S.K., Ö.U., B.U.C., S.T.; Literature search – B.T., E.S., A.Y.K., Ö.U.; Writing – B.T., A.Y.K., E.S., K.S.K.; Critical review – A.Y.K., B.U.C., S.T.

References

- Bäck LJ, Hytönen ML, Malmberg HO, Ylikoski JS. Submucosal bipolar radiofrequency thermal ablation of inferior turbinates: a long-term follow-up with subjective and objective assessment. *Laryngoscope* 2002;112:1806–12. [CrossRef]
- Sapçı T, Sahin B, Karavus A, Akbulut UG. Comparison of the effects of radiofrequency tissue ablation, CO2 laser ablation, and partial turbinectomy applications on nasal mucociliary functions. *Laryngoscope* 2003;113:514–9. [CrossRef]
- Farmer SE, Eccles R. Chronic inferior turbinate enlargement and the implications for surgical intervention. *Rhinology* 2006;44:234–8.
- Lanier B. Allergic rhinitis: selective comparisons of the pharmaceutical options for management. *Allergy Asthma Proc* 2007;28:16–9. [CrossRef]
- Nassef M, Shapiro G, Casale TB; Respiratory and Allergic Disease Foundation. Identifying and managing rhinitis and its subtypes: allergic and nonallergic components—a consensus report and materials from the Respiratory and Allergic Disease Foundation. *Curr Med Res Opin* 2006;22:2541–8. [CrossRef]
- Hol MK, Huizing EH. Treatment of inferior turbinate pathology: a review and critical evaluation of the different techniques. *Rhinology* 2000;38:157–66.
- Williams HO, Fisher EW, Golding-Wood DG. 'Two-stage turbinectomy': sequestration of the inferior turbinate following submucosal diathermy. *J Laryngol Otol* 1991;105:14–6. [CrossRef]
- Mori S, Fujieda S, Igarashi M, Fan GK, Saito H. Submucous turbinectomy decreases not only nasal stiffness but also sneezing and rhinorrhea in patients with perennial allergic rhinitis. *Clin Exp Allergy*. 1999 Nov;29(11):1542-8. [CrossRef]
- Powell NB, Riley RW, Troell RJ, Li K, Blumen MB, Guilleminault C. Radiofrequency volumetric tissue reduction of the palate in subjects with sleep-disordered breathing. *Chest* 1998;113:1163–74.
- Elwany S, Abel Salaam S. Laser surgery for allergic rhinitis: the effect on seromucinous glands. *Otolaryngol Head Neck Surg* 1999;120:742–4. [CrossRef]
- Lin HC, Lin PW, Su CY, Chang HW. Radiofrequency for the treatment of allergic rhinitis refractory to medical therapy. *Laryngoscope* 2003;113:673–8. [CrossRef]
- Lin HC, Lin PW, Friedman M, Chang HW, Su YY, Chen YJ, et al. Long-term results of radiofrequency turbinoplasty for allergic rhinitis refractory to medical therapy. *Arch Otolaryngol Head Neck Surg* 2010;136:892–5. [CrossRef]
- Speciale R, Rustivo S, Gallina S, Cupido G, Giammanco AM. Surgery of the inferior turbinates by radiofrequency. *Otorhinolaryngologia* 2000;50:95–8.
- Coste A, Yona L, Blumen M, Louis B, Zerah F, Rugina M, et al. Radiofrequency is a safe and effective treatment of turbinate hypertrophy. *Laryngoscope* 2001;111:894–9. [CrossRef]
- Nease CJ, Kreml GA. Radiofrequency treatment of turbinate hypertrophy: a randomized, blinded, placebo-controlled clinical trial. *Otolaryngol Head Neck Surg* 2004;130:291–9. [CrossRef]
- Banhiran W, Tantilipikorn P, Metheetrairut C, Assanasen P, Bunng C. Quality of life in patients with chronic rhinitis after radiofrequency inferior turbinate reduction. *J Med Assoc Thai* 2010;93:950–60.
- Cavaliere M, Mottola G, Iemma M. Comparison of the effectiveness and safety of radiofrequency turbinoplasty and traditional surgical technique in treatment of inferior turbinate hypertrophy. *Otolaryngol Head Neck Surg* 2005;133:972–8. [CrossRef]
- Bernstein JA. Nonallergic rhinitis: therapeutic options. *Curr Opin Allergy Clin Immunol* 2013;13:410–6. [CrossRef]
- Banov CH, Lieberman P; Vasomotor Rhinitis Study Groups. Efficacy of azelastine nasal spray in the treatment of vasomotor (perennial nonallergic) rhinitis. *Ann Allergy Asthma Immunol* 2001;86:28–35. [CrossRef]