

Familial Mediterranean Fever is a Rare Cause of Recurrent Pleural Effusion

Tekrarlayan Plevral Efüzyonun Nadir Bir Nedeni Ailevi Akdeniz Ateşi

Savaş Özsu, Neslihan Özçelik, Yılmaz Bülbül

Abstract

Pleural effusion is a common condition and considered as an important clinical problem. The exudates remain a challenge for clinicians and 5-25 % of the patients remain undiagnosed despite thorough investigations. Familial Mediterranean Fever (FMF) is an auto-inflammatory disorder with genetic origin showing an autosomal recessive inheritance pattern generally seen in certain ethnic groups characterized by recurrent fever and systemic findings. Exudative pleuritis has been reported as the solitary manifestation of the first FMF attack, in < 10 % of patients. This case study describes a 70-year-old man with recurrent episodes of exudative pleuritis associated with pleuritic pain.

Key words: Mediterranean fever, pleural effusion, genetic analysis.

Özet

Plevral effüzyon sık görülen önemli bir problem olarak karşımıza çıkmaktadır. Eksuda ayırımı klinisyenler için sorun oluşturmakta ve bazı hastalarda ileri incelemelere rağmen % 5-25 oranında tanı konulamamaktadır. Ailesel Akdeniz ateşi (AAA) tekrarlayan ateş ve sistemik bulgularla karakterize, genellikle etnik gruplarda görülen otozomal resesif geçiş gösteren otoinflatuar genetik orjinli gösteren bir hastalıktır. Pulmoner hemoraji, infarkt ve infiltrasyon FMF'in önemli pulmoner komplikasyonlarıdır. İlk AAA atağının tek başına eksudatif plörezi olarak ortaya çıkma oranı < % 10'dur. Bu yazıda tekrarlayan plevral effüzyonla başvuran ve izole pulmoner tutulumu olan 70 yaşında FMF tanısı konulan bir olgu sunulmuştur.

Anahtar Sözcükler: Ailevi akdeniz ateşi, plevral efüzyon, genetik analiz.

Department of Pulmonary Medicine, Karadeniz Technical University, Faculty of Medicine, Trabzon, Turkey

Karadeniz Teknik Üniversitesi, Tıp Fakültesi, Göğüs Hastalıkları Anabilim Dalı, Trabzon

Submitted (Başvuru tarihi): 19.04.2013 **Accepted (Kabul tarihi):** 03.06.2013

Correspondence (İletişim): Neslihan Özçelik, Department of Pulmonary Medicine, Karadeniz Technical University, Faculty of Medicine, Trabzon, Turkey

e-mail: ozcelik.nesli@gmail.com



Pleural effusion is a common condition and is considered an important problem. The primary evaluation in pleural effusions is the distinction between transudates and exudates. The exudates remain a challenge for clinicians and 5-25 % of the patients remain undiagnosed despite thorough investigations (1).

Familial Mediterranean Fever (FMF) is an auto-inflammatory disorder with genetic origin showing an autosomal recessive inheritance pattern generally seen in certain ethnic groups characterized by recurrent fever and systemic findings. The major complications of FMF include pulmonary hemorrhage, infarction, and infiltration (2). The cause of admission to the hospital is pleuritis in <10 % of the cases, and the occurrence rate of pleuritis increase to 30-40 % in recurrent episodes (2-5). The current article reports a case admitting to the hospital with recurrent pleural effusion and isolated pulmonary involvement diagnosed with FMF.

CASE

A 70-year-old patient was admitted to our polyclinic in February 2010 with complaints of coughing and chest pain. The history of the patient included smoking (22 pack-years), coronary artery disease, and employment in a dye factory. The physical examination revealed no findings except decreased breath sounds at the left lung base.

The chest x-ray radiography showed increased opacity in the lower left zone. Routine laboratory investigations indicated no pathological findings except increased D-dimer levels. Spiral thorax tomography was performed. The tomography was not consistent with pulmonary embolism. Pleural effusion and associated atelectasis was detected in the left lung. The thoracentesis revealed pleural exudate with glucose: 29 mg/dL, total protein: 2.9 gr/dL, albumin: 1.7 gr/dL, LDH: 1004 U/L, and 58 % neutrophils. The exudate was negative for acid-fast bacillus (AFB), tuberculosis polymerase chain reaction (PCR), and tuberculosis culture, and adenosine deaminase was 41 U/L. The abdominal ultrasound was normal. Echocardiography revealed an ejection fraction of 60 %, pulmonary artery pressure of 30 mmHg, and no pericardial effusion. The patient was re-admitted in December 2010 complaining of left side pain. The investiga-

tions revealed recurrent left pleural effusion. The thoracentesis was consistent with exudate including 55 % neutrophils. Thoracoscopic biopsy was performed as a further investigation. Pathology results were consistent with chronic inflammatory infiltration and fibrotic thickening in the pleura. No specific diagnosis was made and the patient was taken into follow-up for idiopathic pleuritis.

The patient was re-admitted in November 2012 with right side pain persisting for 2 weeks. The chest x-ray radiography showed bilateral pleural effusion extending to the right central zone with closure on the left sinus (Figure 1 and 2). Thoracentesis revealed pH: 7.24, glucose: 78 mg/dL, total protein: 3.8 gr/dL, albumin: 2 gr/dL, lactate dehydrogenase (LDH): 428 U/L, and 66 % lymphocytes. Further laboratory investigations were negative for collagen tissue markers, rheumatoid factor, anti-CCP (anti-cyclic citrullinated peptide antibodies), and immunoglobulins and thyroid function tests were within normal limits. The detailed anamnesis revealed that the patient had a son with Familial Mediterranean Fever. The subsequent genetic analyses were positive for M680I G>C heterozygosity. The patient was diagnosed with FMF, and 1.5 mg/day colchicine was initiated. Significant regression was detected in pleural effusion after 20 days of treatment (Figure 3).

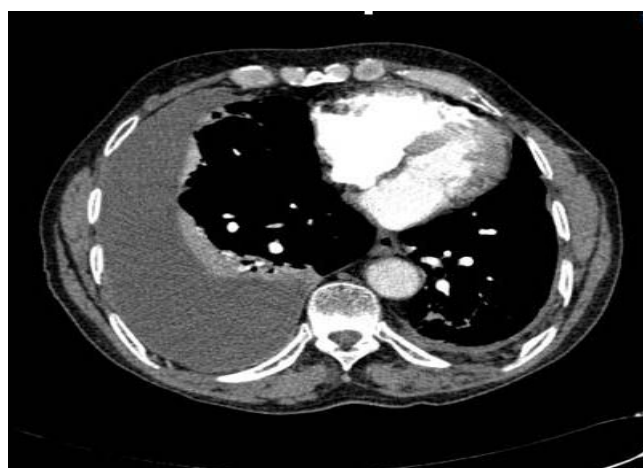


Figure 1: Contrast-enhanced chest CT scan showing a right-sided pleural effusion.

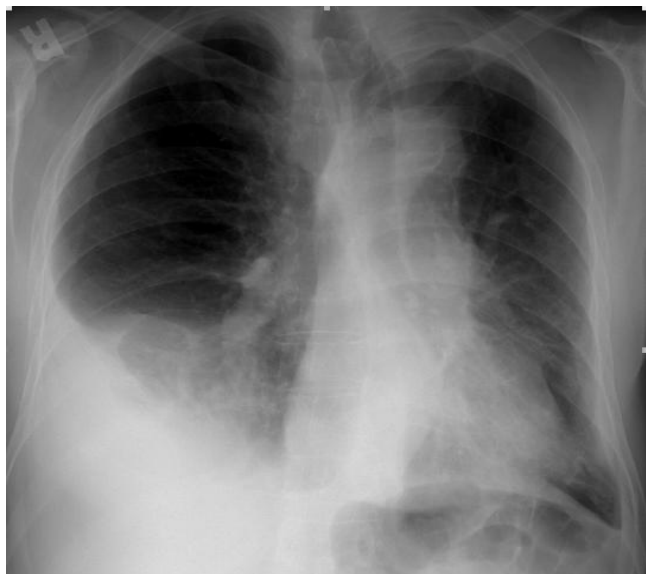

Figure 2 The x-ray showing a right-sided pleural effusion.

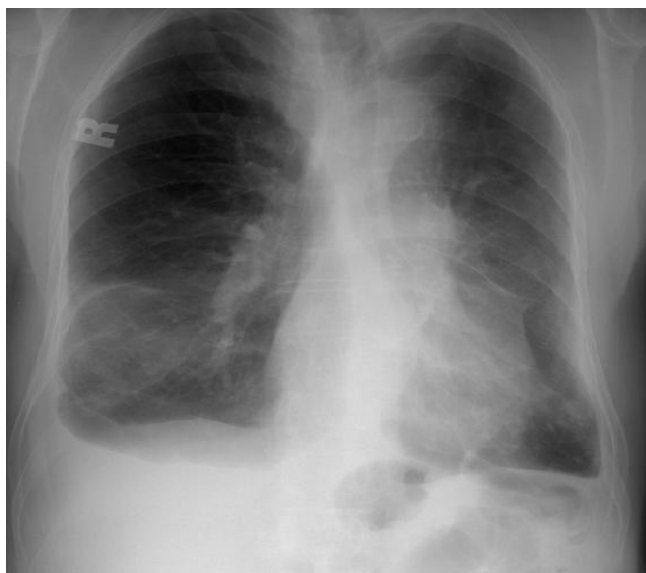

Figure 3: The x-ray showing regressed right-sided pleural effusion.

DISCUSSION

FMF is characterized by recurrent fever and polyserositis, generally with an onset during childhood. A majority of the patients receive the diagnosis by 20 years of age. The proportion of patients diagnosed after the age of 50 years was found to be 5 % in a series of 400 cases (6). Similar to our case report, the literature indicates that patients with isolated pulmonary findings receiving FMF diagnosis are usually older than 50 years of age (7,8).

FMF is a systemic disorder commonly associated with fever and abdominal pain. While 95 % of FMF patients experience abdominal pain, 25 % of them may present with fever alone (3). Various pulmonary findings have

been reported in patients with FMF. These include hemorrhage, pulmonary embolism and infiltration, pleuritis, and malignant mesothelioma (2). Pleural effusion is reported in 30-40 % of patients with FMF (2,4). The reported cases are usually diagnosed following recurrent pleural effusions (3,7,9). Physical examination and imaging findings are commonly non-diagnostic in these patients (3). Pleural effusion is commonly one-sided and resolves spontaneously within a few days. Pleural friction rub and transient minimal pleural effusion are found only in a small portion of attacks. Recurrent chest attacks are associated with pleural thickening and adhesions in some patients, and rarely, with chronic obliteration of the costophrenic sinus (2). The characteristics of pleural fluid have not been described in detail, but an older study stated that the pleural fluid contains predominantly polymorphonuclear leukocytes (3). The pathogenesis of the attacks remains obscure, but the associated painful manifestations are known to result from a massive influx of polymorphonuclear neutrophils and inflammation of the serosal membrane at the affected sites (2). Similar to our case report, Katsenos and colleagues report lymphocytic pleuritis in the pathological evaluation of the pleural exudate in a 30-year-old patient with FMF. As in our study, they also rule out the other possible reasons with thoracoscopic biopsy (3). Interestingly, pericarditis is found in only <1 % of the patients with FMF. FMF diagnosis is based on clinical assessment and pleural involvement is considered as one of the major criteria (2). Genetic diagnosis is limited to only 60 % of the patients that are diagnosed genetically (5).

FMF patients usually exhibit a good response to colchicine treatment. There is no precise data on the treatment period, but two or three months treatment can be administered. Pleural involvement does not require additional treatment. However, if left untreated, these patients may progress to renal and pulmonary amyloidosis and pleural thickening. Renal amyloidosis is the most important and life threatening complication in patients with FMF. One of the most important characteristics of FMF-associated amyloidosis is the occurrence of renal complications without febrile attacks (8).

In conclusion, FMF with isolated pulmonary involvement should be considered in patients with unexplained recurrent pleural effusion. Genetic analysis provides ease of diagnosis, generally without requiring any further diagnostic procedures.

CONFLICTS OF INTEREST

None declared.

REFERENCES

1. Alemán C, Sanchez L, Alegre J, Ruiz E, Vázquez A, Soriano T, et al. Differentiating between malignant and idiopathic pleural effusions: the value of diagnostic procedures. *Q J M* 2007; 100:351–9. [\[CrossRef\]](#)
2. Livneh A, Langevitz P, Pras M. Pulmonary associations in familial Mediterranean fever. *Curr Opin Pulm Med* 1999; 5:326–31. [\[CrossRef\]](#)
3. Katsenos S, Mermigkis C, Psathakis K, Tsintiris K, Polychronopoulos V, Panagou P, et al. Unilateral lymphocytic pleuritis as a manifestation of familial Mediterranean fever. *Chest* 2008; 133:999–1001. [\[CrossRef\]](#)
4. Ben-Chetrit E, Levy M. Familial Mediterranean fever. *Lancet* 1998; 351:659–64. [\[CrossRef\]](#)
5. Lidar M, Pras M, Langevitz P, Livneh A. Thoracic and lung involvement in familial Mediterranean fever (FMF). *Clin Chest Med* 2002; 23:505–11. [\[CrossRef\]](#)
6. Tunca M, Akar S, Onen F, Ozdogan H, Kasapcopur O, Yalcinkaya F, et al. Familial Mediterranean fever (FMF) in Turkey: results of a nationwide multicenter study. *Medicine (Baltimore)* 2005; 84:1–11.
7. Ozkaya S, Butun SE, Findik S, Atici A, Dirican A. A very rare cause of pleuritic chest pain: bilateral pleuritis as a first sign of familial Mediterranean fever. *Case Rep Pulmonol* 2013; 2013:315751. [\[CrossRef\]](#)
8. Sever F, Sever M, Sanal S, Yalçın M, Berdeli A. Familial Mediterranean fever with pulmonary manifestations alone; early diagnosis with genetic analysis. *Tuberk Toraks* 2012; 60:380–4. [\[CrossRef\]](#)
9. Lega JC, Khouatra C, Cottin V, Cordier JF. Isolated recurrent pleuritis revealing familial Mediterranean fever in adulthood. *Respiration* 2010; 79:508–10. [\[CrossRef\]](#)