



An Isolated Skeletal Muscle Metastasis from Lung Adenocarcinoma

Akciğer Adenokarsinomuna Bağlı İzole Bir Kas Metastazı

Aziz Gümüş,¹ Servet Kayhan,¹ Halit Çınarka,¹ İsmail Saygın,² Ünal Şahin¹

Abstract

Lung cancer is one of the leading causes of cancer deaths worldwide and despite advances in treatment and diagnostic techniques, the mortality rates remain high. We report here an 80-year-old male patient with lung adenocarcinoma. The patient underwent a lower left lobectomy and chemotherapy. After 12 months, an isolated skeletal muscle metastasis from a primary lung adenocarcinoma in the left semitendinosus and semimembranosus muscles was detected. The patient is alive without any signs of new metastases after 18 months from the completion of combination therapy consisting of metastasectomy and chemoradiotherapy.

Key words: Adenocarcinoma, lung cancer, skeletal muscle metastasis.

Özet

Akciğer kanseri dünyadaki en önemli ölüm nedenleri arasında yer almakta olup tedavi seçenekleri ve tanı tekniklerindeki gelişmelere rağmen mortalite oranları halen yüksektir. Burada, akciğer adenokarsinomu tanısı olan 80 yaşındaki bir erkek hastayı sunuyoruz. Hastaya sol alt lobektomi ve kemoterapi uygulandı. Tedaviden 12 ay sonra, primer akciğer adenokarsinomundan kaynaklanan, sol semitendinöz ve semimembranöz kaslarda izole bir çizgili kas metastazı saptandı. Hastaya metastazektomi ve kemoradyoterapiden oluşan tedavi kombinasyonu uygulandıktan 18 ay sonra, herhangi yeni bir metastaz bulgusu olmaksızın yaşamaktadır.

Anahtar Sözcükler: Adenokarsinom, akciğer kanseri, çizgili kas metastazı.

¹Department of Pulmonary Disease, Recep Tayyip Erdoğan University, Faculty of Medicine, Rize, Turkey

²Department of Pathology, Karadeniz Technical University, Faculty of Medicine, Trabzon, Turkey

¹Recep Tayyip Erdoğan Üniversitesi Tıp Fakültesi, Göğüs Hastalıkları Ana Bilim Dalı, Rize

²Karadeniz Teknik Üniversitesi Tıp Fakültesi, Patoloji Ana Bilim Dalı, Trabzon

Submitted (Başvuru tarihi): 24.04.2013 **Accepted (Kabul tarihi):** 13.05.2013

Correspondence (İletişim): Servet Kayhan, Department of Pulmonary Disease, Recep Tayyip Erdoğan University, Faculty of Medicine, Rize, Turkey

e-mail: kayhanservet@gmail.com



Cancer is a major public health problem in the world. Despite improved diagnostic methods, and advanced therapeutic modalities including surgery, chemotherapy, and radiotherapy, survival rates remain low. Lung cancer remains the leading cause of cancer-related death in the United States, accounting for 28% of all cases and 5-year combined survival rates for all stages of lung cancer are at 16% (1). Lung cancer metastasize via hematogenous or lymphatic ways commonly to bone, brain, adrenal glands and liver which are rich in capillary vasculature. Isolated metastasis to skeletal muscle originated from non-small cell lung cancer is extremely rare phenomenon, we report here an 80 year-old male patient with lung adenocarcinoma presented with a single metastasis located in semimembranous and semitendinous muscles after one year from a curative therapy. This is a unique case in the literature.

CASE

An 80-year-old man with a 43 year smoking history presented with cough and weight loss. A chest radiograph revealed a well-defined opacity in the left hilar region (Figure 1). A contrast enhanced computed tomography (CT) scan was performed which showed a 3x3 cm sized mass in the left lower lobe that did not involve the mediastinal structures (Figure 2). The stage of the patient was in T2N0M0 stage during diagnosis. He underwent left lower lobectomy and 2 cycles of chemotherapy with cisplatin and docetaxel regimen. After 12 months from surgery, he admitted to clinic with painful, solid palpable mass and well circumscribed swelling located at the back of the thigh. Magnetic resonance imaging (MRI) revealed 3x2.5 cm diameter mass in left semimembranous and semitendinous muscles (Figure 3 and 4). Positron emission computed tomography (PET-CT) revealed an isolated metastasis with a 9.5 SUV max value in same region correlated with MRI results (Figure 5) Incisional biopsy was performed and a final histological diagnosis of the tumor was skeletal muscle metastasis of primary lung adenocarcinoma (Figure 6 and 7). The patient underwent metastasectomy by orthopedic surgery and subsequently 4 cycles of chemotherapy with cisplatin and docetaxel was performed. Regional 40 Gy radiotherapy was given in 15

fractions to reduce the risk of local regional tumor relapse. This patient is alive 18 months after completion of therapy without any signs of new metastases.

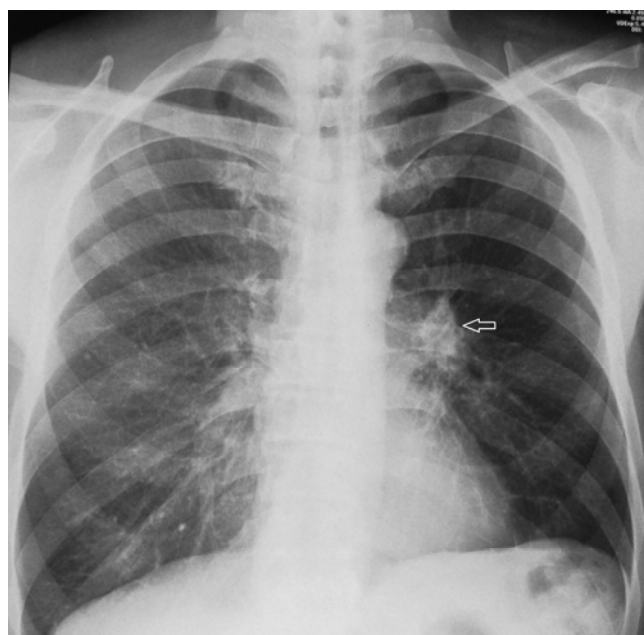


Figure 1: A chest radiograph revealed a well-defined opacity in the left hilar region (arrow).

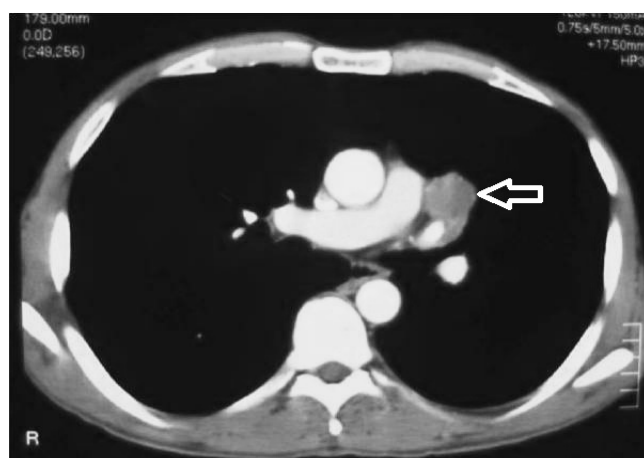


Figure 2: A contrast enhanced computed tomography (CT) scan was performed which showed a 3x3 cm sized mass (arrow) in the left lower lobe that did not involve the mediastinal structures.

DISCUSSION

Lung cancer is the main cause of cancer related deaths. During the first diagnosis and treatment period, most of the patients with lung cancer already have some kind of metastasis. Lung cancer metastasize via hematogenous or lymphatic ways commonly to bone, brain, adrenal glands and liver which are rich in capillary vasculature. Although muscle tissue makes up approximately half of total body weight, metastatic extension to the skeletal

muscle is an exceptional event in neoplasms, with an incidence of 0.8 to 1.5% in autopsy series (2-5). Lung cancer seems to be the underlying primary cancer in most of these cases. Skeletal muscle is resistant to tumoral invasion (6). Isolated metastasis to skeletal muscle from a primary lung cancer is extremely rare. There are a few reports described in the literature. Muscular contractile actions, lactic acid accumulations and protease inhibitors affect the blood flow and inhibit the growth of tumor cells in the muscles and this may contribute to the rarity of this phenomenon (7).

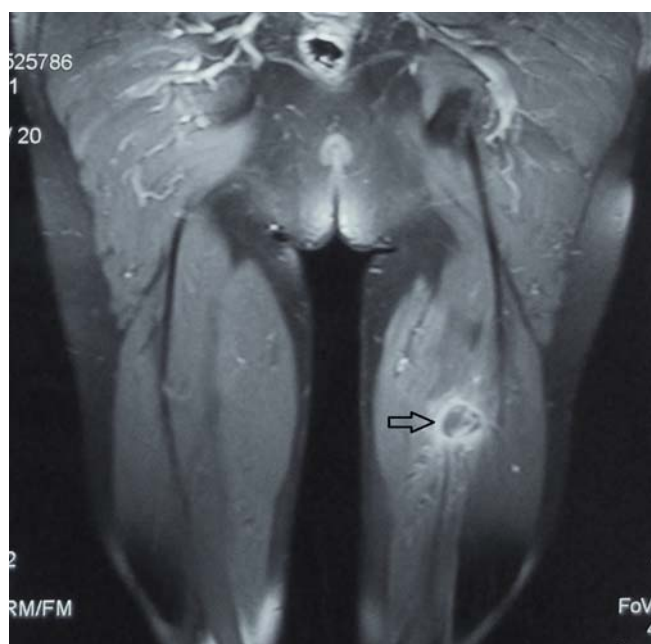


Figure 3: Longitudinal section of magnetic resonance with weighted sequence in T2 that shows a large heterogeneous mass (3x2.5 cm) at the origin of semitendinous and semimembranous muscles of the left thigh, corresponding to a metastasis in the skeletal muscle (arrow).

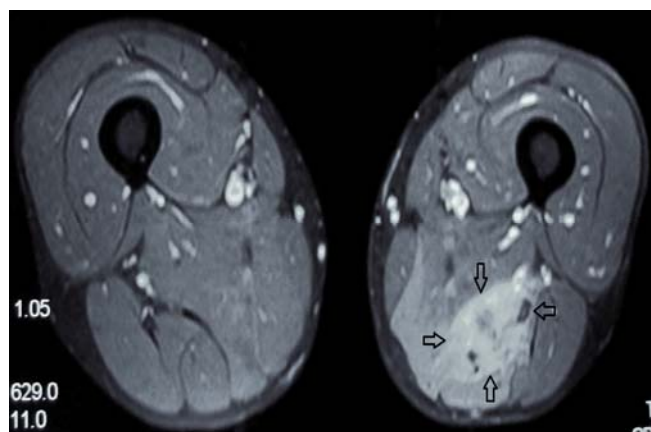


Figure 4: Axial section of magnetic resonance with weighted sequence in T2 that shows the metastatic mass (3x2.5 cm) in semitendinous and semimembranous muscles (arrows).

Skeletal muscle metastasis is deep in location and the most frequent presentation of muscular metastasis is pain and local swelling as demonstrated in our patient (8). Advanced radiological techniques such as MRI, PET-CT and histological confirmations are necessary for skeletal muscle metastasis in clinical suspicions. Even if surgically treated, most of the patients with intramuscular metastasis die within a year. Treatment modalities including combination or any of radiotherapy, chemotherapy and metastasectomy often provides palliation only (8).

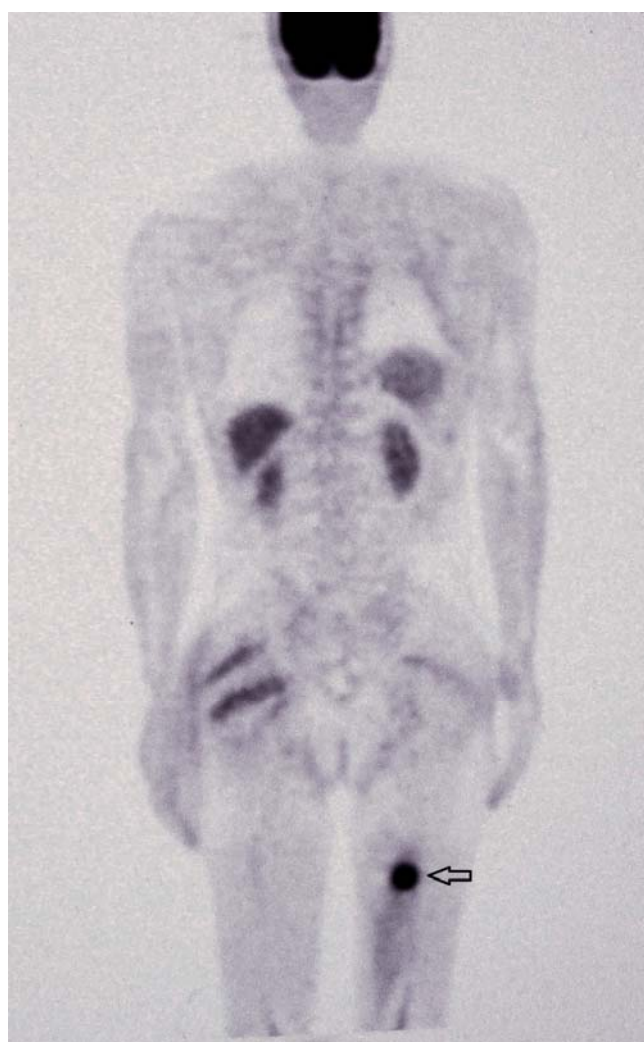


Figure 5: PET-CT revealed an isolated metastasis with a 9.5 SUV max value at the back of the left thigh region.

This case highlights the importance of histologic diagnosis despite clinical and radiologic findings supportive of soft tissue sarcomas. In addition, recurrence after resection of non-small cell lung carcinoma is generally associated with a poor prognosis and this case report

also adds further information to the literature that is an isolated skeletal muscle metastasis from a primary lung adenocarcinoma and treated by chemotherapy and radiotherapy after metastasectomy without any recurrence within 18 months period.

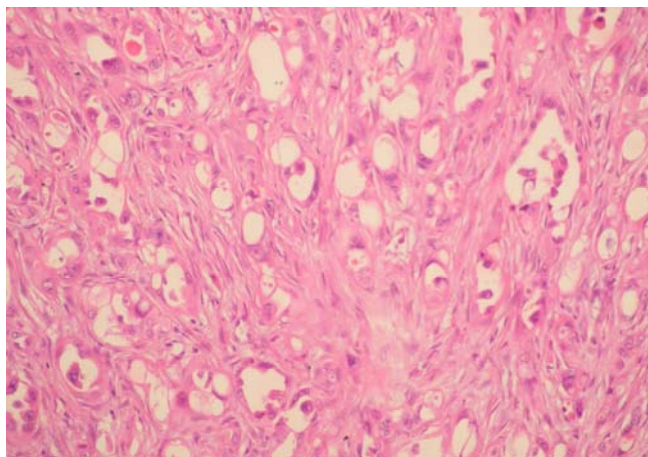


Figure 6: Adenoid structures lined by atypic cells with a large hyperchromatic nuclei and some of them with dense nucleolus in desmoplastic stroma (HEX200).

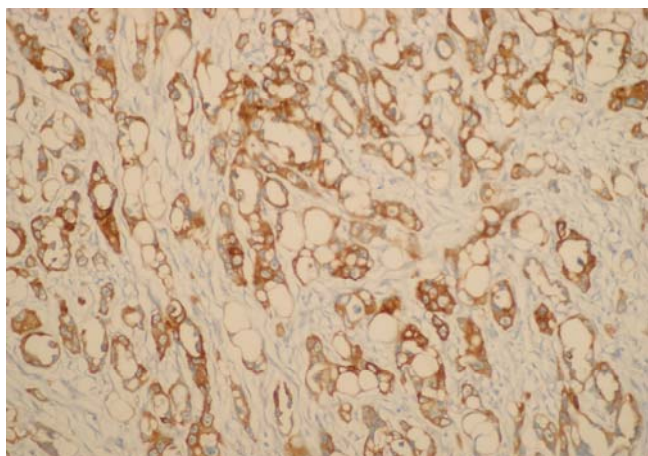


Figure 7: A cytology obtained from the lesion was consistent with adenocarcinoma in the immunohistochemistry study stained positively by thyroid transcription factor 1 (TTF1) showing that metastasis from primary lung cancer (TTF1X200).

There is no consensus on the optimal treatment strategy for skeletal muscle metastasis (3,6). But due to their clinical and radiological appearance, skeletal muscle metastasis is similar to soft tissue sarcomas. We con-

clude that a more aggressive approach might be considered for selected patients with a solitary muscular metastasis from lung cancer and combined therapies may offer potentially curative results as we reported here.

CONFLICTS OF INTEREST

None declared.

REFERENCES

1. American Cancer Society. Cancer facts and figures 2012. Atlanta (GA): American Cancer Society; 2012. Access date: 20 April 2012 Place of access: <http://www.cancer.org/acs/groups/content/@epidemiologyandprevention/documents/document/acspc-031941.pdf>.
2. Damron TA, Heiner J. Distant soft tissue metastases: a series of 30 new patients and 91 cases from the literature. *Ann Surg Oncol* 2000; 7:526–34.
3. Pop D, Nadeemy AS, Venissac N, Guiraudet P, Otto J, Poudoux M, et al. Skeletal muscle metastasis from non-small cell lung cancer. *J Thorac Oncol* 2009; 4:1236–41. [\[CrossRef\]](#)
4. Tuoheti Y, Okada K, Osanai T, Nishida J, Ehara S, Hashimoto M, et al. Skeletal muscle metastases of carcinoma: a clinicopathological study of 12 cases. *Jpn J Clin Oncol* 2004; 34:210–4.
5. Sridhar KS, Rao RK, Kunhardt B. Skeletal muscle metastases from lung cancer. *Cancer* 1987; 59:1530–4. [\[Cross-Ref\]](#)
6. McKeown PP, Conant P, Auerbach LE. Squamous cell carcinoma of the lung: an unusual metastasis to the pectoralis muscle. *Ann Thorac Surg* 1996; 61:1525–6. [\[CrossRef\]](#)
7. Acinas Garcia O, Fernandez FA, Satue EG, Buelta L, Val-Bernal JF. Metastasis of malignant neoplasms to skeletal muscle. *Rev Esp Oncol* 1984; 31:57–67.
8. Santini M, Vicidomini G, Di Marino MP, Baldi A. Solitary muscle metastasis from lung carcinoma. *J Cardiovasc Surg (Torino)* 2001; 42:701–2.