

Ultrasound therapy in iliopsoas hematoma

Basak Bilir Kaya,¹ Afitap Icagasioglu²

¹Department of Physical Medicine and Rehabilitation, Government of Health Siyami Ersek Training and Research Hospital, Istanbul, Turkey

²Department of Physical Medicine and Rehabilitation, Medeniyet University Goztepe Training and Research Hospital, Istanbul, Turkey

ABSTRACT

Warfarin is a commonly used anticoagulant agent that can have life-threatening complications, such as severe bleeding, which then require cessation of the treatment. Due to the widespread use of this therapy in recent years, incidences of its hemorrhagic complications have also increased significantly. In hemodynamically stable patients, it is possible to adopt conservative treatment strategies, such as ultrasound (US) therapy as an alternative. US is a physical therapy modality widely used in musculoskeletal disorders, but there is little evidence about its effectiveness for hemorrhagic complications because of the limited number of studies on this subject at present. A 77-year-old male who had been under oral anticoagulant therapy for 6½ years presented at the clinic with complaints of severe pain and numbness in the anterolateral thigh. US evaluation revealed iliopsoas hematoma. US treatment, administered as a physical therapy modality, resulted in faster resorption of the hematoma than expected. The patient fully recovered from clinically observed pain, meralgia paresthetica, and reduced patellar reflex.

Keywords: Hematoma; ultrasound; warfarin.

Iliopsoas hematoma occurring during anticoagulant use is a rare entity generally seen in patients who are using heparin or warfarin [1, 2]. Iliopsoas hematoma may manifest with various symptoms. In the early stage, pain localized in the lumbar and inguinal regions may occur, while in advanced cases, lumbar plexus neuropathy, massive bleeding, and hemorrhagic shock can be seen [3]. In some cases, direct hemorrhagic pathology may not come to mind [3]. The aim of this case presentation was to raise awareness of iliopsoas hematoma, which should be considered in patients who present with the frequently encountered complaints of thigh

pain, meralgia paresthetica, or femoral neuropathy. It was also a goal to draw attention to the accelerating effect of ultrasound (US) therapy on hematoma resorption in hemodynamically stable patients.

US is a frequently used technology in the diagnosis and treatment of medical conditions [4]. It is also very often preferred among physical treatment modalities [4]. Its indications for use for the musculoskeletal system include muscle relaxation, and relief of edema and pain [5]. Although *in vitro* studies have demonstrated physiological effects of US on live tissue, there is scarce *in vivo* evidence available about its effects on soft tissue [5]. In a recent study

Received: September 18, 2015 *Accepted:* September 29, 2016 *Online:* August 26, 2017

Correspondence: Dr. Basak BILIR KAYA. Dr. Siyami Ersek Gogus Kalp ve Damar Cerrahisi Egitim ve Arastirma Hastanesi, Istanbul, Turkey.

Tel: +90 216 - 542 44 44 e-mail: basakbilir@gmail.com

© Copyright 2017 by Istanbul Northern Anatolian Association of Public Hospitals - Available online at www.kuzeyklinikleri.com



in mice, cutaneous stimulation with US was demonstrated to increase fibroblast migration through the activation of the calcium/calmodulin-dependent protein kinase II/T-cell lymphoma invasion and metastasis 1/Ras-related C3 botulinum toxin substrate 1 (Rac1) pathway, and to decrease wound healing time in diabetic and aged mice at a rate of 30% [6]. Speed evaluated the therapeutic use of US on soft tissue, and indicated that the thermal effects of US included an increase in blood flow and a mild pro-inflammatory response [5]. Its non-thermal effects include cavitation and acoustic microstreaming [5]. As a consequence of such thermal and non-thermal effects, an increase in fibroblastic activity and protein synthesis, increased blood flow, tissue regeneration, and bone healing can be expected [5]. The frequency of therapeutic US is between 0.75 and 3 MHz. Lower frequencies penetrate deeper, but focus on the target tissue with less precision. A frequency of 1 MHz is absorbed at depth of between 3 and 5 cm [7], and is appropriate for deeper tissues (i.e., the psoas muscle). Intermittent use of US increases its non-thermal effects, and a subsequent increase in microfluidity with an ensuing acceleration of fibrinolysis occurs [8, 9]. This effect might presumably hasten resorption of iliopsoas hematoma. Use of diagnostic US in a patient with a spontaneous iliopsoas hematoma and therapeutic use of US in a rectus sheath hematoma have been reported in the literature [2, 10]. However, to our knowledge, no publication of the use of US in the treatment of an iliopsoas hematoma has been presented in the literature.

CASE REPORT

A 77-year-old male patient presented at the clinic with complaints of thigh pain and loss of sensation on the lateral aspect of his thigh. The patient had been using oral anticoagulants for 6½ years following aortic valve replacement and with the diagnoses of left ventricular systolic dysfunction, 3+ mitral valve insufficiency, and pulmonary hypertension. In 2004, he had gone to emergency service with complaints of headache and dizziness, and oral warfarin treatment was discontinued as result of diagnoses of subarachnoid hematoma and bilateral frontoparietal subdural hematoma. The hematomas were surgically resolved by the department of neurosur-

gery and postoperative warfarin treatment was reinitiated at 5 mg, and 7.5 mg on alternate days, based on the recommendation of the department of cardiology. He had no history of bleeding diathesis or alcohol use, and his coagulation parameters tested no more than 1 month earlier were reportedly under control and within therapeutic limits.

Cardiovascular examination results of the patient were as follows: ambulatory blood pressure: 110/70 mmHg and heart rate: 80 bpm with 2/6 systolic murmur heard over cardiac apex. Locomotor system examination revealed a 30 x 20 mm, firm, tender mass, and hypoesthesia were detected on the left medioanterior region of the thigh. Femoral stretch test positivity and decreased patellar tendon reflex were observed in the right thigh. The patient had a score of 8 on 10-point Visual Analogue Scale (VAS) of pain. Some notable biochemical parameters were: bilirubin: 2.0 mg/dL (0.1–1.2 mg/dL), indirect bilirubin: 1.6 mg/dL (0.1–0.8 mg/dL), white blood cell count: 4000/mm³ (4000–11000/mm³), hemoglobin: 14.1 g/dL (11.0–18.0 g/dL), hematocrit: 40.6% (40–52%), platelet count: 150,000/mm³ (150,000–400,000/mm³), prothrombin time: 31.8 seconds (11–15.5 seconds), activated partial thromboplastin time: 29.3 seconds (24–40 seconds), and international normalized ratio (INR): 2.67 (0.67–1.25) (Table 1). Since the patient had claustrophobia, US was preferred as an imaging modality. Superficial tissue US was performed and revealed a 31.1x20.4x14.2 mm hypoechoic mass, which was evaluated as consistent with organized, residual hematoma (Figure 1). Since hemoglobin level and hemodynamic data of the patient were stable and there was no life-threatening bleeding, his oral anticoagulant treatment was not discontinued. US therapy was thought to be a potential treatment for hematoma resorption.

As the patient was hemodynamically stable and the mass lesion was ultrasonographically consistent with organized hematoma, 2 days after the diagnosis, US treatment was initiated. Treatment site was determined based on US findings of heterogeneous isoechoic mass (30.8x11.3x8.3 mm) surrounded by calcific hyperechoic images (Figure 2). In order to benefit from non-thermal effects, intermittent US treatment was preferred. The patient was informed about the emergency case of bleeding, and told that

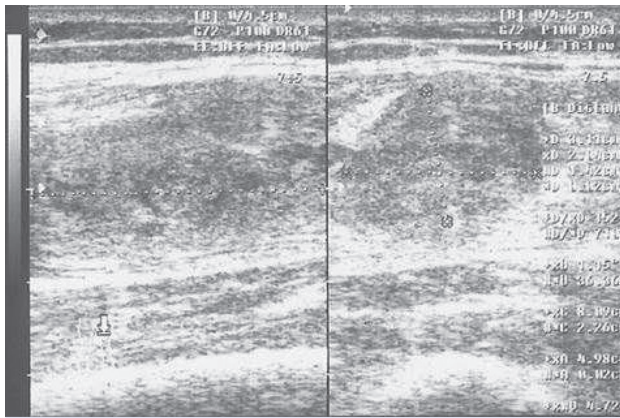


FIGURE 1. Pretreatment ultrasonographic findings.

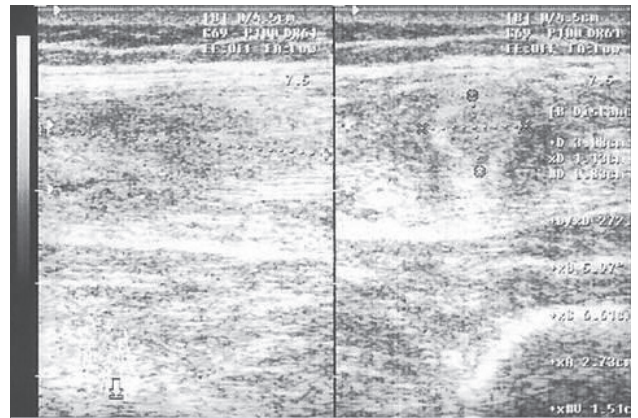


FIGURE 2. Posttreatment ultrasonographic findings.

TABLE 1. Findings

Physical examination	Firm, solid, tender mass measuring 30 x 20 mm in the medioanterior aspect of the femoral region	
	Hypoesthesia of the midlateral aspect of the femoral region	
	Femoral stretch test	Left side: positive
	Visual analogue scale (VAS) pain score	VAS 8
	Patellar tendon reflex	Left side: decreased
Ultrasonographic findings	Hypoechoic mass measuring 31.1x20.4x14.2 mm, consistent with organized hematoma	
Vital findings	Blood pressure	110/70 mmHg
	Heart rate	80 bpm
	Findings on auscultation	2/6 systolic murmur heard over cardiac apex
Laboratory results	Bilirubin	2.0 mg/dL (0.1–1.2 mg/dL)
	Indirect bilirubin	1.6 mg/dL (0.1–0.8 mg/dL)
	White blood cell count	4000/mm ³ (4000–11000/mm ³)
	Hemoglobin	14.1 g/dL (11.0–18.0 g/dL)
	Hematocrit	40.6% (40–52%)
	Platelet count	150,000/mm ³ (150,000–400,000/mm ³)
	Prothrombin time	31.8 seconds (11–15.5 seconds)
	Activated partial thromboplastin time	29.3 seconds (24–40 seconds)
	International normalized ratio	2.67 (0.67–1.25)

VAS: Visual Analogue Scale

if his thigh pain increased or his health state deteriorated, he was to request emergency service. Restriction of physical activity during the treatment process was also recommended. US therapy was organized as a total of 15 sessions over a period of 3 weeks, once a day, 5 days a week. The dose of intermittent US applied was 1 W/cm² for 5 minutes with probe light emission area of 5 cm². The probe was applied with circular movements and with the aid of a lubri-

cating gel. No complication due to US therapy was observed. Flank pain regressed from VAS 8 to VAS 2. On physical examination, patellar reflex returned to normal. Femoral stretch test was negative on the left side, which had previously yielded positive result. Sensory examination of the previously hypoesthetic area on the lateral side of the thigh demonstrated normoesthesia. On control examination performed 4 months later, VAS score was 0 with normal sen-

sory perception, and during US examination no hematoma formation was observed.

DISCUSSION

In cases of hematoma, the ability to decrease resorption time is important. In a case presented by Berna et al., the authors followed-up the resorption process of a rectus sheath hematoma treated conservatively without the application of US, and observed spontaneous hematoma resorption nearly 3 months later [11]. They indicated that during this process of resorption there was a risk of the hematoma becoming infected [11–13]. Therefore, decreasing the resorption time of a hematoma will enable a much faster improvement in the clinical state of the patient and decrease the possibility of infection.

When a patient presents with thigh pain, iliopsoas hematoma should be kept in mind [14]. For the diagnosis of hematoma, US or computed tomography may be used [10]. The treatment alternative selected is dependent on the hemodynamic stability of the patient, and for hemodynamically unstable patients, a surgical alternative may be preferred [15]. However, in stable patients, conservative treatment alternatives may be evaluated. Among these alternatives, as a modality of physical therapy, US can be considered. However, very few publications are currently available indicating that US accelerates the processes of soft tissue regeneration and hematoma resorption [5]. Recently, a study on mice demonstrated that US activated the Rac 1 pathway, leading to a migration of fibroblasts, and also shortened the wound healing process by 30% [6]. In the present case, we also think that US sped up resorption of hematoma, as rapid clinical improvement of the patient was observed sooner than anticipated. Devcic-Kuhar et al. demonstrated that US increased *in vitro* thrombolysis mediated by plasminogen and tissue-type plasminogen activator [16]. The acceleration of hematoma resorption in our patient was consistent with these data. Berna et al. recommended proceeding with intermittent US therapy after the acute phase of a hematoma had terminated, due to the risk of hemorrhagic complications [10]. Nevertheless, despite the concern about a higher risk of recurrent bleeding in a newly formed hematoma, in some studies in the literature it has been stated that once a hematoma

is organized, that is, after detection of a mostly hypoechoic mass on US, and coagulation parameters are brought within therapeutic limits (INR=2–3.5), US therapy may be initiated [10]. As reported in the literature, a patient whose heparin treatment had been discontinued because of the presence of an iliac hematoma exited as a result of myocardial infarction [14]. Therefore, since discontinuation of anticoagulant therapy also constitutes a risk for the patient, hemodynamically stable patients can be closely followed-up without termination of anticoagulant therapy. We also believe that in appropriately selected cases, conservative treatment of an iliopsoas hematoma should be conducted by a specialist in physical therapy and rehabilitation in close collaboration with the primary specialist and a radiologist who will monitor the anticoagulant treatment of the patient. Randomized controlled studies to be performed in the future may help us formulate protocols to guide us concerning the use of US for the resorption of hematomas.

Conflict of Interest: None declared.

Financial Disclosure: The authors declared that this study has received no financial support.

Authorship contributions: Concept – B.B.K.; Design – B.B.K.; Supervision – A.I.; Materials – B.B.K.; Data collection &/or processing – B.B.K.; Analysis and/or interpretation – B.B.K.; Literature search – B.B.K., A.I.; Writing – BBK; Critical review – A.I.

REFERENCES

1. Sasson Z, Mangat I, Peckham KA. Spontaneous iliopsoas hematoma in patients with unstable coronary syndromes receiving intravenous heparin in therapeutic doses. *Can J Cardiol* 1996;12:490–4.
2. Sharma D, Saker R, Govind A. Emergency department ultrasound diagnosis of spontaneous iliopsoas haemorrhage in a patient on warfarin. *BMJ Case Rep* 2013;2013. pii: bcr2013201291.
3. Qanadli SD, El Hajjam M, Mignon F, Bruckert F, Chagnon S, Lacombe P. Life-threatening spontaneous psoas haematoma treated by transcatheter arterial embolization. *Eur Radiol* 1999;9:1231–4.
4. Warden SJ, McMeeken JM. Ultrasound usage and dosage in sports physiotherapy. *Ultrasound Med Biol* 2002;28:1075–80.
5. Speed CA. Therapeutic ultrasound in soft tissue lesions. *Rheumatology (Oxford)* 2001;40:1331–6.
6. Roper JA, Williamson RC, Bally B, Cowell CA, Brooks R, Stephens P, et al. Ultrasonic Stimulation of Mouse Skin Reverses

- the Healing Delays in Diabetes and Aging by Activation of Rac1. *J Invest Dermatol* 2015;135:2842–51.
7. Gann N. Ultrasound: Current concepts. *Clin Manage* 1991;11:64–9.
 8. Francis CW, Onundarson PT, Carstensen EL, Blinc A, Meltzer RS, Schwarz K, et al. Enhancement of fibrinolysis in vitro by ultrasound. *J Clin Invest* 1992;90:2063–8.
 9. Harpaz D, Chen X, Francis CW, Marder VJ, Meltzer RS. Ultrasound enhancement of thrombolysis and reperfusion in vitro. *J Am Coll Cardiol* 1993;21:1507–11.
 10. Berná-Serna JD, Sánchez-Garre J, Madrigal M, Zuazu I, Berná-Mestre JD. Ultrasound therapy in rectus sheath hematoma. *Phys Ther* 2005;85:352–7.
 11. Berná JD, García-Medina V, Guirao J, García-Medina J. Rectus sheath hematoma: diagnostic classification by CT. *Abdom Imaging* 1996;21:62–4.
 12. Fusato G, Vidali M, Zuccarotto D, Rodighiero D. Hematomas of the abdominal rectus muscle. *Minerva Chir* 1993;48:107–13.
 13. Moreno Gallego A, Aguayo JL, Flores B, Soria T, Hernández Q, Ortiz S, et al. Ultrasonography and computed tomography reduce unnecessary surgery in abdominal rectus sheath haematoma. *Br J Surg* 1997;84:1295–7.
 14. Piazza I, Girardi A, Giunta G, Pappagallo G. Femoral nerve palsy secondary to anticoagulant induced iliacus hematoma. A case report. *Int Angiol* 1990;9:125–6.
 15. Egger B, Schweizer W, Wagner HE. Acute abdomen in abdominal wall hemorrhage in anticoagulation. *Helv Chir Acta* 1992;59:399–402.
 16. Devcic-Kuhar B, Pfaffenberger S, Gherardini L, Mayer C, Gröschl M, Kaun C, et al. Ultrasound affects distribution of plasminogen and tissue-type plasminogen activator in whole blood clots in vitro. *Thromb Haemost* 2004;92:980–5.