

An evaluation of magnetic resonance imaging with histogram analysis in patients with idiopathic subjective tinnitus

 Murat Baykara,¹  Saime Sagiroglu²

¹Department of Radiology, Kahramanmaraş Sutcu Imam University Faculty of Medicine, Kahramanmaraş, Turkey

²Department of Otorhinolaryngology, Kahramanmaraş Sutcu Imam University Faculty of Medicine, Kahramanmaraş, Turkey

ABSTRACT

OBJECTIVE: Tinnitus is defined as the perception of sound in the ears without any acoustic stimulus. It has still not been determined whether tinnitus originates peripherally, centrally or from several locations. The aim of the study was to determine any possible cochlear pathology in patients with normal hearing and tinnitus of unspecified etiology.

METHODS: The study included 22 patients who presented at the clinic with the complaint of idiopathic subjective tinnitus that had been ongoing for at least one year. A total of 44 ears were included; 28 with tinnitus and 16 healthy ears. Unilateral tinnitus was determined in 16 patients and bilateral in six patients. The temporal magnetic resonance imaging (MRI) and audiogram results of the patients were retrieved from the hospital records. The MRI histogram measurement was made automatically and calculated for each ear separately.

RESULTS: Entropy was found to be significantly higher in the control group and distribution was lower ($p>0.01$). In the tinnitus group, distribution was found to be broader and kurtosis was statistically significantly greater ($p<0.001$).

CONCLUSION: In conclusion, MRI histogram analysis can be considered as a method to be used in the clinical evaluation of the determination of possible cochlear pathology in ears with tinnitus.

Keywords: Cochlea; entropy; magnetic resonance imaging; tinnitus.

Cite this article as: Baykara M., Sagiroglu S. An evaluation of magnetic resonance imaging with histogram analysis in patients with idiopathic subjective tinnitus. *North Clin Istanbul*

Tinnitus is defined as the perception of sound in the ears or within the head without any acoustic stimulus. It is a heterogeneous feeling and therefore when differentiating tinnitus, it is necessary to define it as pulsatile (synchronised with the heart rhythm) or non-pulsatile, subjective or objective, intermittent or continuous, and unilateral or bilateral [1, 2]. The objective type is more associated with vascular and muscle dysfunction. Myoclonus of the middle ear or the palatal muscles is a cause of objective tinnitus [1, 3]. The sound may be pulsatile or

rhythmic. If it is synchronised with the heartbeat, there is a high likelihood that it is vascular in origin. Most patients have subjective tinnitus and the frequency at which it is seen increases with age. Although often seen together with hearing loss, it can also be seen without symptoms of hearing loss. While 17% of the general population have been reported to be affected, this rate can rise to 33% in the geriatric population [4, 5]. Tinnitus is seen at equal rates in males and females [6]. The relationship between tinnitus and cochlear pathology has not yet been

Received: December 11, 2017 *Accepted:* January 08, 2018 *Online:* August 07, 2018



Correspondence: Dr. Saime SAGIROGLU, Kahramanmaraş Sutcu Imam Universitesi Tıp Fakültesi, Avsar Kampusu, 12 Subat Mahallesi, 46100 Kahramanmaraş, Turkey.

Tel: +90 344 300 34 34 e-mail: ssguzelsoy@hotmail.com

© Copyright 2019 by Istanbul Provincial Directorate of Health - Available online at www.northclinist.com

fully clarified. It is not clear whether or not there is an association with cochlear pathology, increased or decreased cochlear nerve activity or a central pathology.

Microscopic biological changes in tissues can reflect tissue heterogeneity. Entropy is an imaging method of texture analysis which is used to characterise tissue heterogeneity by calculating the tissue intensity and distribution of irregularity within an area or volume. Thus, it is a parameter showing irregularity in the tissue. This method has been successfully applied in the classification of pathological tissues in the liver, thyroid, chest, kidneys, prostate, heart, brain and lungs [7, 8]. Analysis of tissue appearance with entropy is not just a visual evaluation, but is an objective data evaluation calculated statistically. Distribution characteristics of tissue have recently started to attract much attention and to be used as a prognostic biomarker [9–11].

MATERIALS AND METHODS

Patient Population

This retrospective study included 22 patients who presented at the ENT Department with the complaint of tinnitus which had been ongoing for more than 1 year. The continuous tinnitus was considered homogeneous. A control group was formed of 16 healthy ears in the same patient group with 28 ears with tinnitus. Tinnitus was determined as unilateral in 16 patients and bilateral in 6 patients. The medical history of participants was taken from the archives and included cardiovascular disease and risk factors, medications used, exercise, smoking, and caffeine or alcohol consumption. No patient had a history of neurologic disease, tumors in the internal acoustic canal or cerebellopontine angle, or temporal bone trauma. Patients were excluded if they had undergone ear surgery or if the tinnitus was related to acoustic schwannoma, meningioma, hearing loss, otosclerosis, acoustic trauma, Meniere's disease or other reasons. And subject not including pregnancy or any decision for pregnancy, psychiatric disorders or its history (according to psychiatrist verification).

Detailed ear, nose and throat, neurological and audiometric examinations were applied to all patients. Audiometric tests were made in a double-walled sound room using an Interacoustics AC40 Pure Tone Audiometer with evaluation of pure sound in the range of 125 Hz and 8000 Hz and the results were recorded. Patients with pure sound <mean 25dB were included in the study. High frequency hearing loss group (4000 Hz≤) was included in the study group. To discount intracranial

and ear pathologies, the hospital archives were examined for the temporal magnetic resonance imaging (MRI) records. Ethical approval of the study was obtained from the ethics committee of our institution.

MRI Examination Protocol

The MRI examinations were made with a 1.5T GE Optima MR360 device (GE, Milwaukee, USA). The region of interest (ROI) was defined as a cochlear basal turn section area on T2-weighted 3D FIESTA slices.

Image Evaluation and Analysis

The ROI was evaluated with MATLAB version 2009b program (MATrix LABoratory, Mathworks Inc, Natick, USA). Calculations were made of the parameters of gray level intensity, standard deviation of histogram, entropy, uniformity, skewness and kurtosis values with Size L% (mean low values from the area remaining below standard deviation) and Size M% (mean area remaining below standard deviation).

Statistical Analysis

We performed all statistical analyses using SPSS statistics 22 (IBM, Armonk/NY, USA). In our cohort, the Mann–Whitney U test and Pearson correlation analysis were performed. p values below 0.05 were considered significant.

RESULTS

A total of 44 ears were examined in the study, comprising 9 female and 13 male patients. The mean age was found as 49.44 ± 13.16 (range=29–68) in the study group. Although there was no statistically significant difference in the other parameters, entropy was seen to be at a higher value and lower distribution in the control group ($p < 0.01$) (Figure 1). The appearance of the tinnitus group showed broader distribution as lower mean values. The kurtosis in the tinnitus group was statistically significantly greater ($p < 0.001$) (Figure 2). This created a statistically significant difference in the Size L% and Size M% parameters ($p < 0.01$, $p < 0.05$).

DISCUSSION

Despite great advances recorded in medicine, tinnitus remains a scientific and clinical enigma. It is very commonly seen and can cause a deterioration in quality of life

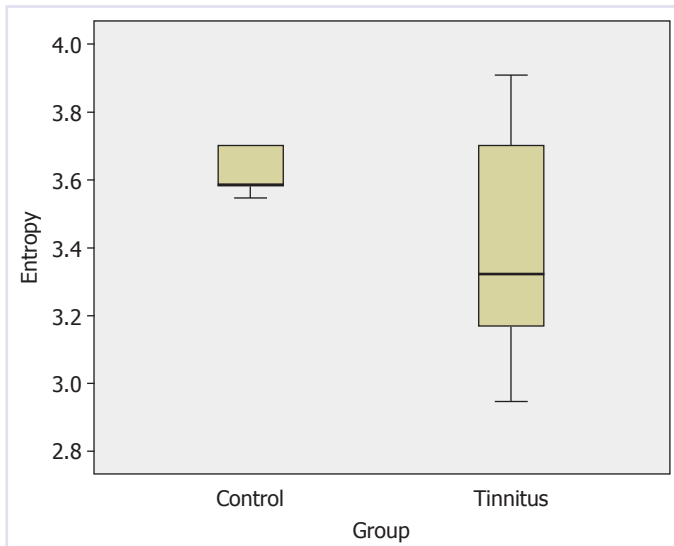


FIGURE 1. Entropy distribution in patients ears and control ears.

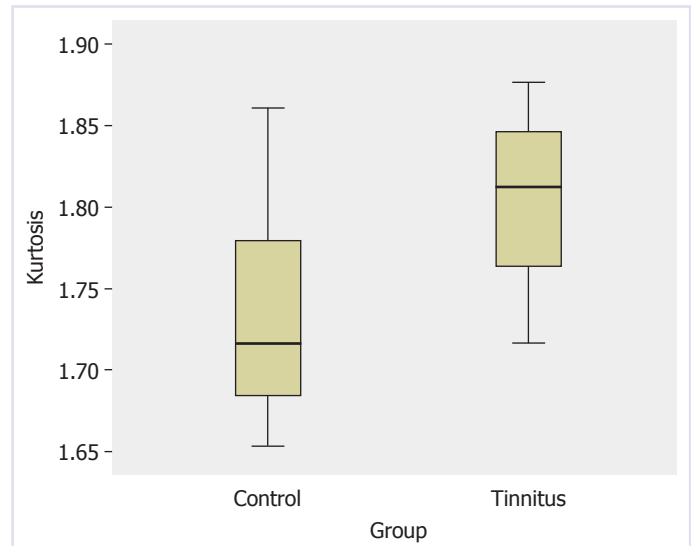


FIGURE 2. Kurtosis distribution in patients ears and control ears.

of the patient. It has still not been determined whether tinnitus originates peripherally, centrally or from several locations. When it is in one ear and there is sensorineural hearing loss in the same ear, there is increased possibility of peripheral origin.

Tinnitus is not a disease, but a symptom, but there are no objective tests to determine this state. The majority of studies on this subject have been made without evidence. Etiological causes include external ear canal diseases, diseases involving the tympanic membrane, middle ear diseases, vascular lesions, all kinds of cochlear pathologies that cause sensorineural hearing loss, retrocochlear pathologies and psychiatric diseases. In patients with idiopathic subjective tinnitus, the cause is generally multifactorial or may emerge associated with peripheral nerve hyperactivity (cochlear and 8th cranial nerve) or an impairment of function in this cycle [12–14].

There are many theories on the subject of cochlear or retrocochlear origin of tinnitus. These include abnormal perilymph movement, chorda tympani hypersensitivity, increased activity in the cochlear hairy cells, static breaks in the cilia, a cut in the connection of the hairy cells in the tectorial membrane, abnormal connections of the hairy cells in the tectorial membrane, and reduced or increased blood flow in the auditory system. In some studies, it has been shown that a potential source of tinnitus could be a frequency-specific dysfunction in the auditory cells or abnormal exacerbations of the acoustic nerve cells [15–17]. Thus, any dysfunction in these cells responsible for

hearing, or reduction in the inhibition input in the central auditory system or associated excessive stimulation are reasons associated with these theories. This leads to the occurrence of tinnitus. According to this theory, the basic organ responsible is cochlear pathology. Dysfunction occurring in the cochlea triggers the cycle of tinnitus. Nevertheless, despite several studies conducted on this subject, dysfunction of the cells responsible for hearing has still not been established as the cause.

House et al. [18], stated that tinnitus develops associated with a weakening of the ring pattern in the tonotropic alignment related to deteriorated cochlear structure as it was shown that tinnitus was not eliminated with the cutting of the auditory nerve, but continued. That study supported that the emergence of tinnitus is related to causes other than cochlear. However, when neural synchronisation is considered, the exacerbation of the neuron pattern which emerges in the primary auditory cortex related to pathology in the cochlea does not support this situation [1, 19, 20]. In a study of ears with tinnitus, severe damage was determined in the cochlea compared to those with normal hearing [21]. In the current study, a significant difference was determined in the cochlear fluid distribution in ears with tinnitus compared with healthy ears. According to this result, the fluid character changed related to infection of the fluid in the cochlea, a change in the ion balance or various other reasons and this was thought to have caused an abnormal function change in the hairy cells of this abnormal fluid.

Several audiological conditions, especially hearing loss, are a risk factor for tinnitus. Although otological anomalies may be the source of initial tinnitus, this is more likely to continue because of subsequent neural changes in the central auditory system. Despite experimental studies showing this result, there are several unexplained questions [1, 22, 23]. Various studies have included an MRI evaluation of the cortical auditory region, but there are few studies related to the imaging method applied to the cochlea [14, 24]. The current study consisted of patients with tinnitus and a control group of healthy ears and a difference in the cochlea of both ears with greater distribution in the ears with pathological tinnitus was determined with MRI histogram analysis. However, it could be said that if direct cochlea MRI slices had been taken rather than temporal MRI slices, the quality of the study would have been greater. As permitted gray level values were restricted to one pixel that could be accepted in the histogram of the texture parameters, a higher pixel count of the region to be examined would provide results increasing the quality of the research.

Pure-tone audiometry should certainly be applied to these patients and if it is thought to be necessary, a tympanogram should be added. If there are neurological findings in asymmetric tinnitus, MRI and/or Computed tomography should be requested to discount anatomic variations and tumoral formations. In the current study, texture analysis evaluation was applied as described by Ganeshan [9, 25, 26]. As one of the standard imaging methods on MRI, the entropy values were calculated which showed the potential value of the cochlear tissue analysis. In various previous studies, entropy has been used to determine the malignancy potential of tissue, to calculate tumour survival, as a guide in radiotherapy treatment, in the radiological diagnosis of otosclerosis and the use of these studies has started to increase [9, 27–30]. In the current study, the histographic evaluation to determine changes in the cochlea in patients with idiopathic tinnitus was considered to be useful.

Conclusion

The etiology of tinnitus and pathophysiology and clinical characteristics reveal different management techniques in the treatment of tinnitus in the patient population. An effective classification system which could be applied related to the pathophysiological mechanism underlying the individual tinnitus symptoms would be an important step towards personalised rehabilitation. Therefore,

there is a need for practical measurement techniques that could make this differentiation in clinics. With the entropy measurement technique applied in this study, objective data could be obtained by developing existing techniques and could be considered to be a contributory step to diagnosis and treatment.

Conflict of Interest: The authors declare no conflict of interest.

Financial Disclosure: The authors declared that this study has received no financial support.

REFERENCES

1. Baguley D, McFerran D, Hall D. Tinnitus. *Lancet*. 2013;382:1600–7.
2. De Ridder D, Verstraeten E, Van der Kelen K, De Mulder G, Sunaert S, Verlooy J, et al. Transcranial magnetic stimulation for tinnitus: influence of tinnitus duration on stimulation parameter choice and maximal tinnitus suppression. *Otol Neurotol*. 2005;26:616–9.
3. Bhimrao SK, Masterson L, Baguley DM. Systematic review of management strategies for middle ear myoclonus. *Otolaryngol Head Neck Surg*. 2012;146:698–706.
4. Nondahl DM, Cruickshanks KJ, Wiley TL, Klein R, Klein BE, Tweed TS. Prevalence and 5-year incidence of tinnitus among older adults: the epidemiology of hearing loss study. *J Am Acad Audiol*. 2002;13:323–31.
5. Jastreboff PJ, Gray WC, Mattox DE. Tinnitus and hyperacusis. In: Cummings CW, Fredrickson JM, Harker LA, Krause CJ, Richardson MA, Schuller DE, editors. *Otolaryngology Head and Neck Surgery*. 3rd ed. Philadelphia: Mosby year Book; 1998.p.3198–222.
6. Davis A, El Rafaie A. Epidemiology of tinnitus. In: Tyler RS, ed. *Tinnitus handbook*. San Diego, CA: Singular, Thomson Learning. 2000.p.1–23.
7. Chabat F, Yang G-Z, Hansell DM. Obstructive lung diseases: texture classification for differentiation at CT. *Radiology*. 2003;228:871–7.
8. Castellano G, Bonilha L, Li LM, Cendes F. Texture analysis of medical images. *Clinical Radiology*. 2004;59:1061–9.
9. Ganeshan B, Panayiotou E, Burnand K, Dizdarevic S, Miles K. Tumour heterogeneity in non-small cell lung carcinoma assessed by CT texture analysis: a potential marker of survival. *Eur Radiol*. 2012;22:796–802.
10. Molina D, J. Pérez-Beteta, B. Luque, Arregui E, Calvo M, Borrás JM, et al. Tumour heterogeneity in glioblastoma assessed by MRI texture analysis: a potential marker of survival. *Br J Radiol*. 2016;20160242.
11. Molina D, Pérez-Beteta J, Martínez-González A, Martino J, Velásquez C, Arana E, et al. Influence of gray level and space discretization on brain tumor heterogeneity measures obtained from magnetic resonance images. *Comput Biol Med*. 2016;1:49–57.
12. Zenner HP, Ernst A. A cochlear-motor, transduction and signal transfer tinnitus: model for three types of cochlear tinnitus. *Eur Arch Otorhinolaryngol*. 1993;149:447–54.
13. Coles RRA. Tinnitus. In: *Adult audiology*. 1st ed.(Stephens D, eds), Oxford: butterworth-heinemann. 1997:1–34.
14. Farhadi M, Mahmoudian S, Saddadi F, Karimian AR, Mirzaee M, Ahmadizadeh M, et al. Functional brain abnormalities localized in 55 chronic tinnitus patients: fusion of SPECT coincidence imaging and MRI. *J Cereb Blood Flow Metab*. 2010;30:864–70.
15. Londero A, Langguth B, De Ridder D, Bonfils P, Lefaucheur JP. Repetitive transcranial magnetic stimulation (rTMS): a new therapeutic ap-

- proach in subjective tinnitus? *Neurophysiologie Clinique*. 2006;36:145-55.
16. Cebi M, Tas C, Tarhan N. New Treatment Approaches in Tinnitus: The Place of Repetitive Transcranial Magnetic Stimulation and Transcranial Direct Current Stimulation. *Turk Arch Otolaryngol*. 2014;52:98-105.
 17. Eggermont JJ. Tinnitus: neurobiological substrates. *Drug Discov Today*. 2005;10: 1283-90.
 18. House JW, Brackmann DE. Tinnitus: surgical treatment. *Ciba Found Symp*. 1981;85: 204-16.
 19. Noreña AJ. An integrative model of tinnitus based on a central gain controlling neural sensitivity. *Neurosci Biobehav Rev*. 2011;35:1089-109.
 20. Seki S, Eggermont JJ. Changes in spontaneous firing rate and neural synchrony in cat primary auditory cortex after localized tone-induced hearing loss. *Hear Res*. 2003;180:28-38.
 21. Barnea G, Attias J, Gold S, Shadar A. Tinnitus with normal hearing sensitivity: extended high-frequency audiometry and auditory-nerve brain-stem-evoked responses. *Audiology*. 1990;29:36-45.
 22. Eggermont J, Roberts L. The neuroscience of tinnitus. *Trends Neurosci*. 2004;27:676-82.
 23. Noreña AJ, Eggermont JJ. Changes in spontaneous neural activity immediately after an acoustic trauma: implications for neural correlates of tinnitus. *Hear Res*. 2003;183:137-53.
 24. Mühlnickel W, Elbert T, Taub E, Flor H. Reorganization of auditory cortex in tinnitus. *Proc Natl Acad Sci*. 1998;95:10340-3.
 25. Ganeshan B, Goh V, Mandeville HC, Ng QS, Hoskin PJ, Miles KA. Non-small cell lung cancer: histopathologic correlates for texture parameters at CT. *Radiology*. 2013;266:326-36.
 26. Ganeshan B, Miles KA, Young RC, Chatwin CR. Texture analysis in non-contrast enhanced CT: impact of malignancy on texture in apparently disease-free areas of the liver. *Eur J Ra-diol*. 2009;70:101-10.
 27. Suo ST, Zhuang ZG, Cao MQ, Qian LJ, Wang X, Gao RL, et al. Differentiation of pyogenic hepatic abscesses from malignant mimickers using multislice-based texture acquired from contrast-enhanced computed tomography. *Hepatobiliary Pancreat Dis Int*. 2016;15:391-8.
 28. Aerts HJ, Bussink J, Oyen WJ, van Elmpt W, Folgering AM, Emans D, et al. Identification of residual metabolic active areas within NSCLC tumours using a pre-radiotherapy FDG-PET-CTscan: a prospective validation. *LungCancer*. 2012;75:73-6.
 29. Lambin P, Petit SF, Aerts HJ, van Elmpt WJ, Oberije CJ, Starmans MH, et al. From population to voxel-based radiotherapy: exploiting intra-tumour and intra-organ heterogeneity for advanced treatment of non-small cell lung cancer. *Radiol Oncol*. 2010;96:145-52.
 30. Yamashita K, Yoshiura T, Hiwatashi A, Togao O, Kikuchi K, Inoguchi T, et al. The radiological diagnosis of fenestral otosclerosis: the utility of histogram analysis using multidetector row CT. *Eur Arch Otorhinolaryngol*. 2014;271:3277-82.