

Comparison of Outcomes After the Triceps-Split Approach Versus the Triceps-Sparing Approach for Humerus Shaft Fractures

Humerus Şaft Kırıklarında Triseps-Split veya Triseps-Sparing Yaklaşım Sonrası Sonuçların Karşılaştırılması

Çağatay Eyüp Zengin[®], Kemal Kayaokay[®], Sertaç Saruhan[®], Cumhuriyet Davulcu[®], Muhittin Şener[®]

Ethics Committee Approval: Received from İzmir Katip Çelebi University Clinical Research Ethics Committee (14.11.2018/355)
Conflict of Interest: None
Funding: None
Informed Consent: Informed consent was obtained from all individual participants included in the study.

Cite as: Zengin ÇE, Kayaokay K, Saruhan S, Davulcu CD, Şener M. Comparison of outcomes after the triceps-split approach versus the triceps-sparing approach for humerus shaft fractures. Med Med J. 2019;34(1):54-60

ABSTRACT

Aim: The aim of the current study is to compare patients with a diagnosis of humerus shaft fracture operated on with a triceps-sparing or triceps-splitting approach.

Methods: Thirty-nine patients (18 males, 21 females) operated between 2014-2017, for humerus shaft fractures were included in the study. The patients were separated into two groups as triceps-split or triceps-sparing, groups according to the surgical approach. At the final follow-up examination, ROM, isometric elbow extension, time to union, and muscle strength were measured. Functional evaluation was made using the Disabilities of the Arm, Shoulder and Hand (DASH) Score.

Results: The average follow-up period was 18 months (range, 13-56 months). No statistically significant difference was determined between the groups in terms of elbow flexion, elbow extension contracture, or DASH score. The difference in triceps strength between the groups was statistically significant. Union was seen to occur clinically at an average of 13.2 weeks (range, 12-26 weeks).

Conclusion: Both the triceps-sparing and triceps-splitting approaches can be used safely in humerus shaft fractures, and the experience of the surgeon can help determine which is best suited to the circumstances. The triceps-sparing approach offers the superiority of protecting the integrity of the triceps and providing better postoperative triceps strength.

Keywords: Triceps sparing, triceps splitting, humerus shaft fracture, extensor mechanism

ÖZ

Amaç: Bu çalışmanın amacı, humerus şaft kırığı tanısı ile triceps sparing veya triceps splitting yaklaşım ile opere edilen hastaların sonuçlarını karşılaştırmaktır.

Yöntem: 2014-2017 yılları arasında humerus şaft kırığı tanısı ile opere edilen 39 hasta (18 erkek, 21 kadın) çalışmaya dahil edildi. Hastalar tercih edilen cerrahi yaklaşıma göre triceps-split veya triceps-sparing şeklinde iki gruba ayrıldı. Son kontrolde dirsek ROM, izometrik dirsek ekstansiyon gücü, kaynama zamanı ve kas gücü ölçüldü. Fonksiyonel değerlendirme Disabilities of the Arm, Shoulder and Hand (DASH) skoru kullanılarak yapıldı.

Bulgular: Hastaların ortalama takip süresi 18 aydı (13-56 ay). Her iki grup arasında dirsek fleksiyonu, dirsek ekstansiyon kontraktürü, DASH skoru açısından istatistiksel açıdan anlamlı fark bulunmazken, triceps gücü açısından anlamlı fark elde edildi. Klinik olarak hastalarda ortalama 13,2 (12-26) haftada kaynama gerçekleştiği görüldü.

Sonuç: Sonuç olarak, humerus şaft kırıklarında gerek triceps sparing gerekse triceps splitting yaklaşım operasyonu gerçekleştiren cerrahın tecrübesine göre güvenle kullanılabilir. Operasyonu gerçekleştirecek cerrahın tecrübesi ve kırık tipi seçilecek insizyonu belirlemede önemlidir. Triceps sparing yaklaşımın triceps bütünlüğünün korunması ve operasyon sonrası triceps gücü açısından üstünlüğü mevcuttur.

Anahtar kelimeler: Triceps sparing, triceps splitting, humerus şaft kırığı, ekstansör mekanizma

Received: 22.11.2018
Accepted: 31.01.2019
Publication date: 30.03.2019

Çağatay Eyüp Zengin
Department of Orthopaedics and
Traumatology, İzmir Katip Çelebi
University Atatürk Training and
Research Hospital,
İzmir, Turkey
✉ zengincagatay@hotmail.com
ORCID: 0000-0002-9843-790X

K. Kayaokay 0000-0003-1655-0587
S. Saruhan 0000-0002-7876-4479
C.D. Davulcu 0000-0002-6444-5047
M. Şener 0000-0002-4544-3644
Department of Orthopaedics and
Traumatology, İzmir Katip Çelebi
University Atatürk Training and
Research Hospital,
İzmir, Turkey



INTRODUCTION

Humerus shaft fractures are common, constituting 1%-3% of all fractures¹. Traditionally, these fractures are treated conservatively. It is possible to obtain good results with conservative treatment, which results in an acceptable alignment of >90%². However, surgical treatment has come to the fore in the treatment of humerus diaphyseal fractures in recent years. Surgery provides better alignment and meets patient expectations both for more rapid union and an earlier return to activity³.

The two main surgical approaches to humerus shaft fracture are plating and intramedullary nailing (IMN)⁴. External fixation is often used as a temporary measure, but it is not preferred in the definitive treatment of a humerus fracture because of the risk of deep tissue infection⁵. Plate application has advantages compared to IMN, such as providing direct compression on the fracture line and eliminating the possibility of postoperative shoulder pain⁴.

However, among surgeons who prefer plate application for treatment, there is no consensus on the optimal surgical approach or choice of technique. The literature describes the use of anterior, lateral, anterolateral, and posterior approaches for plate application in the treatment of humerus shaft fractures^{4,6,7}. The frequently preferred anterolateral incision, which continues in the distal of the deltopectoral incision, is preferred for fractures in the proximal and middle sections⁸. In fractures close to the distal metaphyseal section, application is difficult because of insufficient space for the placement of the plate in the distal, besides the anatomical position of the radial nerve makes reduction difficult⁹. The anterior approach can be used for comminuted humeral fractures and for segmental ones because this approach allows in a single incision to access the entire length of the humerus⁷. The posterior approach can be used for all diaphyseal fractures. The smooth structure of the posterior aspect of the humerus is more suitable for plate placement. The radial nerve is more easily identified and protected. Additionally, better visual-

ization allows more screws to be used in the distal part of the plate, permitting treatment of fractures near the distal end⁸.

The posterior incision includes the approaches of triceps sparing, when the triceps is mobilized from the lateral or medial, or triceps splitting, when the triceps is cut along the fibers. The triceps-sparing approach was first described by Alanso-Llames¹⁰. Compared to triceps splitting, the risk of direct damage to the muscle is reduced; because this leads to relatively less bleeding, and less scar formation^{11,12}. The two approaches have been compared in previous studies conducted on humerus distal articular or extra-articular fractures (AO/OTS 13A, 13B, 13C)^{11,12}. However, unlike previous studies, the current study compared these incisions in humerus shaft fractures. The aim of the current study was to compare patients with a diagnosis of humerus shaft fractures fixed with a triceps-sparing or triceps-splitting approach, in regard to joint range of motion (ROM), triceps extension strength, and functional results.

MATERIAL and METHOD

Approval for the study was granted by the Local Ethics Committee (Katip Celebi University Non-interventional Clinical Studies Institutional Review Board, 14.11.2018, 2018/355). Between 2014-2017 retrospective evaluation was made of patients, aged >18 years, who presented at our clinic with a humerus fracture and were treated with a 4.5 mm locking compression plate (LCP) (TST, Istanbul, Turkey) applied through a posterior incision. Fractures classified as AO/OTA 12A, 12B and 12C were included in the study. Patients were excluded from the study if they had an open fracture; pathological fracture, or periprosthetic fracture; preoperative radial nerve damage; a concomitant fracture in the same extremity that could affect postoperative rehabilitation; revision cases of malunion or non-union or if the follow-up period was <1 year.

After the decision for surgery was taken, the appropriate clinical and radiological evaluations were made.

The operations were then performed by two surgeons, co-authors of the current paper. After each patient was placed in the lateral decubitus position, the uppermost arm was put into a horizontal position in 90° abduction from the shoulder, then positioned with radiolucent padding support, allowing flexion of the elbow. The underlying arm was placed on a sterile side-table in extension. No tourniquets were used in the operations. The patients were separated into triceps-split or triceps-sparing groups, according to the surgical approach, which was applied according to the surgeon's preference.

In the triceps-split approach, a longitudinal incision was made from the midline of the posterior humerus starting eight cm distal of the acromion and continuing towards the olecranon fossa. Then the deep fascia was traversed parallel to the skin incision. Entering between the long and lateral heads of the triceps, after retracting the long head medially, the radial nerve and the deeper branches of the artery were suspended over the spiral groove. The fibers of the medial head were separated by splitting along the skin incision as far as the periosteum of the humerus. The subperiosteal surrounding of the humerus was elevated. Then, when a more proximal view was required, the visualization area was increased by

elevating laterally the lateral head of the triceps, and proximally elevating the radial nerve, taking care not to strain the nerve (Figure 1).

The triceps-sparing approach was applied as described by Gerwin et al.¹². After passing through the skin and deep fascia in the same way as in the split approach, and by retracting the triceps muscle medially, the lateral brachial cutaneous nerve was identified as the branch of the radial nerve over the posterior lateral intermuscular septum. Following the course of the nerve proximally, the location was found where the radial nerve penetrated the intermuscular septum. By opening the intermuscular septum approximately three cm above the radial nerve, easier mobilization of the radial nerve was provided. The nerve was suspended and thereby protected throughout the operation. The medial and lateral heads of the triceps were raised from the intermuscular septum laterally and subperiosteally from the posterior edge of humerus towards the ulnar side. Gauze was placed between the posterior aspect of the humerus and the triceps, then the triceps and the radial nerve were retracted medially. When a more proximal view was required, this exposure was extended as far as the axillary nerve (Figure 2).

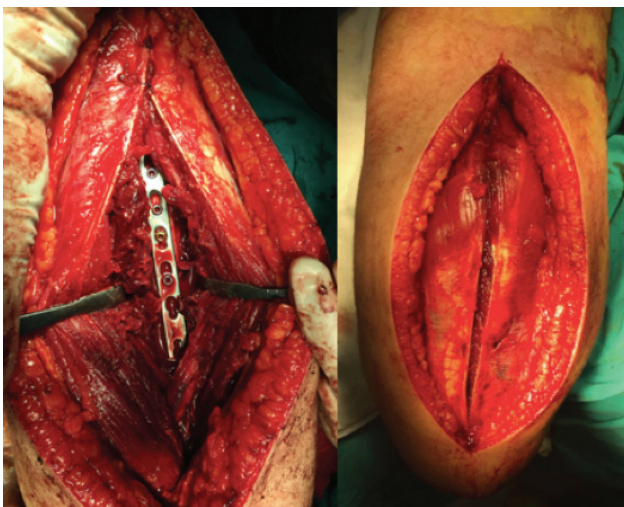

Figure 1. Triceps-splitting approach to humerus shaft with single plating. (A) During the plate application and (B) at the end of the operation.

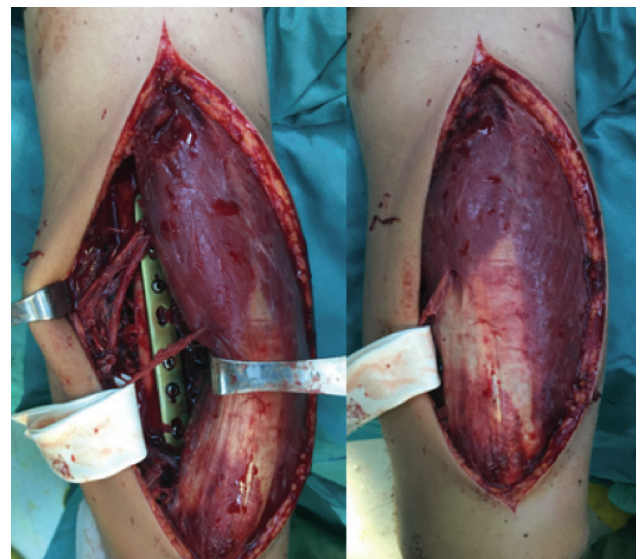


Figure 2. Triceps-sparing approach to humerus shaft with single plating. (A) During the plate application and (B) at the end of the operation.

As a single plate from the posterior was selected for all patients, the triceps was not loosened from the medial and ulnar nerve exploration was not made. Osteosynthesis was applied in all cases with a 4.5 mm LCP inserted from the posterior.

After closure of the incision bandages, rather than a plaster cast, were applied. On postoperative day 2 or 3, elbow flexion-extension exercises were started. At postoperative four weeks, elbow-strengthening exercises were added. Follow-up examinations of the patients were made at 4-week intervals until union was confirmed. Follow-up continued at 8-week intervals for 12 months postoperative.

Patients were evaluated according to the radiograms obtained on presentation and classified according to the AO/OTA classification criteria. Bone union time was recorded by evaluating the follow-up radiograms. Radiological union was accepted as the visualization of the formation of continuity in at least three cortices on the anterior-posterior and lateral radiograms. At the final follow-up examination, ROM was measured with a goniometer. Isometric elbow extension strength was measured with an analog dynamometer (SN-500, Geratech, Istanbul, Turkey) with the patient laid supine, with his/her shoulders in neutral abduction, the elbow in 90° flexion, and the forearm in a neutral position. The test measurement was compared with the contralateral, non-operated arm. The time to union, ROM, and muscle strength were measured by an independent observer. Functional evaluation was made using the Disabilities of the Arm, Shoulder and Hand (DASH) Scale Scores.

Statistical analysis

All of the statistical analyses were performed using SPSS Statistics for Windows version 15.0 (IBM Inc, Armonk, NY, USA). The categorical data were presented as the frequencies and percentages; with the normally distributed continuous data presented, as the mean with its standard deviation (SD). The differences in the groups and fracture configurations were evaluated with chi-square tests, and the differences

in the ages, ranges of motion, triceps strengths, and DASH scores were assessed with Student’s t-tests. In all of the analyses, p<0.05 was considered as statistically significant.

RESULTS

Throughout the study period, a total of 53 patients with AO/OTA 12A, 12B, and 12C fractures were managed with a posterior plate applied through triceps-sparing or triceps-splitting incisions. A total of 14 patients were excluded from the study; five patients did not attend follow-up examinations and another nine patients were removed based on other criteria. Thus, evaluation was made of 39 patients, 21 treated with the triceps-sparing approach and 18 with the triceps-splitting approach (Table 1). The mean follow-up period was 18 months (range, 13-56 months).

Table 1. Demographic characteristics data of two groups.

	Triceps Sparing	Triceps Split	P-value
Patients (n)	21	18	0.901
Female/Male (n)	16/5	11/7	0.959
Injured arms (right arm/left arm)	15/6	12/6	0.246
Mean age (years)	36±13	39±21	0.802
Classification of AO/OTA 12 (A:B:C)	5:11:5	6:8:4	0.903

No statistically significant difference was determined between the groups in terms of elbow flexion, elbow extension contracture, or DASH score. The difference in triceps strength between the groups was statistically significant (p=0.009) (Table 2).

Table 2. Comparison of clinical outcomes between two groups.

Indices	Triceps Sparing	Triceps Split	P-value
Range of elbow flexion (°)	146±4	142±6	0.475
Range of elbow extension contracture (°)	6±2	8±3	0.188
Triceps Strength (% of uninjured arm)	90±18	61±14	0.009
DASH score	7.7±3.2	12.2±4.4	0.333

Union was seen to occur clinically within a mean of 13.2±2.5 weeks. Multiple debridements were per-

formed on one patient because of infection, and the implant was removed from that patient at 26 weeks after union had developed. There were no cases of malunion, non-union, or implant failure. Postoperative radial nerve damage was seen in four (10%) patients, ie. in two members of the triceps-splitting group and two of the triceps-sparing group. The radial nerve damage was observed to have completely recovered in three patients in the 4th and in 1 patient in the 6th postoperative month.

DISCUSSION

Currently, neither triceps-splitting nor triceps-pairing is considered the superior approach. The experience of the surgeon and the type of fracture determine the incision to be employed. A comparison of the patients in the current study treated with posterior plating by means of a triceps-sparing or triceps-splitting approach in the management of humerus shaft fracture shows that higher levels of triceps muscle strength were obtained in the triceps-sparing group. No difference was determined between the groups in terms of elbow ROM, union rates, or DASH scores.

For every patient in the current study, a posterior incision was used to reach the humerus shaft and perform osteosynthesis. In a cadaver study by Gerwin et al.¹³ in which posterior approaches to the humerus diaphysis were compared, 55% of the humerus could be reached from the posterior with the standard triceps-splitting approach. However, the rate was 76% with the triceps-sparing approach because of the mobilization of the proximal radial nerve and the elevation of the triceps lateral head. By preferring an approach that protected the integrity of the triceps by subperiosteally retracting the medial and lateral heads of the triceps medially, 94% of the humerus could be reached from the posterior surface¹³. However, even if the majority of the humerus can be reached through a posterior incision, sufficient visualization of the fractures that are very close to the humerus head and proximal fractures may not be possible¹³.

The triceps-split approach applied by opening the triceps from the midline of the medial head is an incision that can be used in distal and shaft fractures of the humerus. Because this approach does not have an actual inter-nervous or inter-muscular plane, significant postoperative scar formation should, in theory, lead to reduced triceps muscle strength. The triceps-split approach is technically simple to apply, and fracture reduction is easy, as direct access is provided to the fracture line. There is no need for ulnar nerve isolation during the application of double plates, as muscle fibrils protect the ulnar nerve from the medial aspect.

Over the years, the triceps-sparing technique has been employed by many surgeons using different techniques suited to different fracture types. The bilaterotricipital incision was first used by Alonso-Llames, and its use was expanded by Schildhauer et al.¹⁴ to distal extra-articular fractures¹⁰. Gerwin et al.¹³ reported that, with modifications, it could be used for humerus shaft fractures with proximal or distal locations. With the use of this incision, there is no need for repair of the extensor mechanism at the end of the operation. The triceps muscle is protected, and a working area with less bleeding is provided. As the triceps is protected and there is less scar formation, the triceps strength is, in theory, not reduced postoperatively, and therefore contracture of the elbow does not develop. However, the triceps-sparing incision is technically difficult and, because the visualization of the triceps is restricted, the fracture reduction maneuver becomes challenging. To increase medial stability, there is a need for ulnar nerve isolation in patients for whom plate application is planned, a step not required for the triceps-split approach.

Previous studies have compared these two approaches in the treatment of distal humerus fractures. Illical et al. compared the triceps-split and triceps-sparing approaches in AO/OTA 13A2 and 13A3 humerus distal fractures and reported that the triceps-sparing approach resulted in better ROM and improved triceps strength in extra-articular distal humerus frac-

tures. Similar union rates and functional results were obtained in both approaches¹². Remia et al.¹⁵ compared the triceps-splitting and -sparing approaches in AO/OTA 13C humerus distal intra-articular fractures and reported no statistically significant difference regarding elbow ROM and triceps strength. Consistent with previous findings in the literature, the current study found that, while a statistically significant difference was determined between the triceps strength of the two groups, no significant difference in function was observed. That no difference was found in respect of ROM, contrary to previous studies, is related to the study having been conducted on patients with humerus shaft fractures.

In a study of 66 patients operated on for humerus shaft fractures using the posterior triceps-sparing approach, Gausden et al.¹⁵ reported a high union (98%) and a low complication rate (4.8%). In the current study, the longer mean time to union of 13.2 weeks was related to the infection that delayed union in 1 patient. This complication led to the removal of the implant from the patient (2%) after full bone union.

In the current study, postoperative nerve damage developed in 10% of the patients. In the literature, this rate varies between 3% and 20%^{4,6}. Claessen et al.⁶ reported that radial nerve damage developed in 1 of 9 patients treated with posterior incision. To reduce radial nerve damage, Garwin recommended that in the triceps-splitting approach, the nerve be identified and protected in the radial groove between the lateral and medial heads of the triceps, and in the triceps-sparing approach, at the level of the lateral intermuscular septum¹³. In the 4 patients of the current study who developed radial nerve damage, complete recovery was obtained in at the 6th postoperative month.

Limitations of this study may include its retrospective design, the limited number of patients, and that the selection of the surgical incision was left to the discretion of the surgeon.

In conclusion, both the triceps-sparing and triceps-splitting approaches can be used safely in humerus shaft fractures, and the experience of the surgeon can help determine which is best suited to the circumstances. The triceps-sparing approach offers the advantages of protecting the integrity of the triceps and providing better postoperative triceps strength.

Ethical approval for all procedures performed in studies involving human participants was in accordance with the ethical standards of the institutional and/or national research committee and with the 1964 Helsinki declaration and its later amendments or comparable ethical standards. The Ethical approval and grant number of the study is 14/11/2018-355.

REFERENCES

1. Epidemiology and patho-anatomical pattern of 2,011 humeral fractures: data from the Swedish Fracture Register. Bergdahl C, Ekholm C, Wennergren D, Nilsson F, Möller M. *BMC Musculoskelet Disord.* 2016;17:159. <https://doi.org/10.1186/s12891-016-1009-8>
2. Sarmiento A, Zagorski J, Zych G, Latta L, Capps C. Functional bracing for the treatment of fractures of the humeral diaphysis. *J Bone Joint Surg Am.* 2000;82(4):478-86. <https://doi.org/10.2106/00004623-200004000-00003>
3. Denard A Jr, Richards JE, Obremskey WT, Tucker MC, Floyd M, Herzog GA. Outcome of nonoperative vs operative treatment of humeral shaft fractures: a retrospective study of 213 patients. *Orthopedics.* 2010;33(8). <https://doi.org/10.3928/01477447-20100625-16>
4. Walker M, Palumbo B, Badman B, Brooks J, Gelderen JV, Mighell M. Humeral shaft fractures: a review. *J Shoulder Elbow Surg.* 2011;20(5):833-44. <https://doi.org/10.1016/j.jse.2010.11.030>
5. Doygherty PJ, Silvertown C, Yeni Y, Tashman S, Weir R. Conversion from temporary external fixation to definitive fixation: shaft fractures. *J Am Acad Orthop Surg.* 2006;14(10):124-7. <https://doi.org/10.5435/00124635-200600001-00028>
6. Claessen FM, Peters RM, Verbeek DO, Helfet DL, Ring D. Factors associated with radial nerve palsy after operative treatment of diaphyseal humeral shaft fractures. *J Shoulder Elbow Surg.* 2015;24(11):307-11. <https://doi.org/10.1016/j.jse.2015.07.012>
7. An Anterior Approach to Entire Length of Humerus and to Distal Shaft for Fracture Fixation. Lee CH, Choi H, Kim TI, Kim JB, Shin SY, Rhee SK. *Clin Shoulder Elbow.* 2016;19(4):223-8. <https://doi.org/10.5397/cise.2016.19.4.223>
8. Zlotolow DA, Catalano LW 3rd, Barron OA, Glickel SZ. Surgical exposures of the humerus. *J Am Acad Orthop Surg.* 2006;14(13):754-65. <https://doi.org/10.5435/00124635-200612000-00007>
9. Maresca A, Fantasia R, Cianforlini M, Giampaolini N, Cerbasi S, Pascarella R. Distal-third diaphyseal fractures of the humerus: choice of approach and surgical treatment. *Musculoske-*

- let Surg. 2016;100(1):97-104.
<https://doi.org/10.1007/s12306-016-0418-z>
10. Alonso-Llames M. Bilateraltricipital approach to the elbow. Its application in the osteosynthesis of supracondylar fractures of the humerus in children. *Acta Orthop Scand.* 1972;43(6):479-90.
<https://doi.org/10.3109/17453677208991270>
 11. Erpelding J, Mailander A, High R, Mormino MA, Fehringier EV. Outcomes following distal humeral fracture fixation with an extensor mechanism-on approach. *J Bone Joint Surg Am.* 2012;94:548-53.
<https://doi.org/10.2106/JBJS.J.01785>
 12. Illical EM, Farrell DJ, Siska PA, Evans AR, Gruen GS, Tarkin IS. Comparison of outcomes after triceps split versus sparing surgery for extra-articular distal humerus fractures. *Injury.* 2014;45(10):1545-8.
<https://doi.org/10.1016/j.injury.2014.04.015>
 13. Gerwin M, Hotchkiss RN, Weiland AJ. Alternative operative exposures of the posterior aspect of the humeral diaphysis with reference to the radial nerve. *J Bone Joint Surg Am.* 1996;78(11):1690-5.
<https://doi.org/10.2106/00004623-199611000-00008>
 14. Schildhauer T, Nork SE, Mills WJ, Henley MB. Extensor mechanism-sparing paratricipital posterior approach to the distal humerus. *J Orthop Trauma.* 2003;17(5):374-8.
<https://doi.org/10.1097/00005131-200305000-00009>
 15. Remia LF, Richards K, Waters PM. The Bryan-Morrey triceps-sparing approach to open reduction of T-condylar humeral fractures in adolescents. Cybex evaluation of triceps function and elbow motion. *J Pediatr Orthop.* 2004;24(6):615-9.
<https://doi.org/10.1097/01241398-200411000-00003>
 16. Gausden EB, Christ AB, Warner SJ, Levack A, Nellestein A, Lorich DG. The triceps-sparing posterior approach to plating humeral shaft fractures results in a high rate of union and low incidence of complications. *Arch Orthop Trauma Surg.* 2016;136(12):1683-9.
<https://doi.org/10.1007/s00402-016-2578-6>