

# Comparison of open, laparo-endoscopic and one-stage laparoscopic approaches for treatment of gallbladder and common bile duct stones

Nuru Bayramov, Aygun Ibrahimova

Department of Surgical Diseases, Azerbaijan Medical University, Baku, Azerbaijan

## ABSTRACT

**Introduction:** The aim of this study was to compare the results of 3 treatment methods for common bile duct (CBD) and gallbladder stones: open, 2-stage endoscopic-laparoscopic, and 1-stage laparoscopic CBD exploration.

**Materials and Methods:** A total of 229 patients with a median age of 59 years (range: 9–92 years) were enrolled in this study. All of the patients had symptomatic gallbladder stone or CBD stones, which were found preoperatively or intraoperatively using ultrasonography, magnetic resonance-cholangiography, intraoperative contrast cholangiography, or fiberoptic choledochoscopy. Three methods of management of patients were employed. The classic open approach, which consists of laparotomy, cholecystectomy, and CBD exploration was used in 78 patients. The 2-stage laparo-endoscopic approach, which includes pre- or postoperative endoscopic retrograde cholangiopancreatography and laparoscopic cholecystectomy, was performed in 84 patients. One-stage laparoscopic management consists of laparoscopic cholecystectomy and CBD exploration with intraoperative cholangiography and fiberoptic choledochoscopy, and was performed in 67 patients.

**Results:** Operation time in the open approach, laparo-endoscopic, and 1-stage laparoscopic patients was 121 minutes, 142 minutes, and 123 minutes, respectively. The stone removal rate was comparable in the 3 groups: 94.8%, 85.7%, and 97% for open, laparo-endoscopic, and 1-stage laparoscopic patients, respectively. The hospital stay was significantly shorter in the 1-stage laparoscopic group (2.3 days in 1-stage laparoscopic, 6.5 days in laparo-endoscopic, and 8.2 days in open approach group). A significant difference was also found in the complication rate. The total number of complications (19.4%) in the 1-stage laparoscopic group was significantly ( $p < 0.05$ ) lower than in the open (52.5%) and laparo-endoscopic (33.3%) groups. Most complications (92.5%) in the 1-stage laparoscopic group were minor and did not require intervention.

**Conclusion:** In comparison with the open and 2-stage laparo-endoscopic approaches, 1-stage laparoscopic cholecystectomy and CBD exploration have advantages, including shorter operative time, shorter hospital stay, lower complication rate, and greater stone removal rate, and may be considered the first choice for treatment of gallbladder and CBD stones.

**Keywords:** Common bile duct stones; gallbladder; laparoscopy.



Received: 05.07.2017 Accepted: 28.07.2017

Correspondence: Aygun Ibrahimova, M.D., Azerbaijan, Baki, Samed Vurgun str, 155 AZ1022 Baki, Azerbaijan

e-mail: dr.a.ibrahimova@gmail.com

## Introduction

One of the most common complications of gallstone disease followed by biliary colic and cholecystitis is choledocholithiasis, which is found in 8–20% cases.<sup>[1,2]</sup> Although significant improvement has been achieved thanks to magnetic resonance imaging and contrast cholangiography, which are widely used in diagnostics of choledocholithiasis in recent years, there is no unanimous approach regarding the treatment.<sup>[1,3,4]</sup> Key treatment principle of bile duct stones secondary to gallstone (cholecysto-choledocholithiasis) is cholecystectomy and stone removal from choledoch, and classical open, two-stage endoscopic-laparoscopic and one-stage laparoscopic methods, which are currently applied for this purpose, have yielded controversial outcomes. Classical open method that was extensively used before, is currently applied in 5–52% cases, and though it is cheap and efficient method, the complication rate is high.<sup>[6,7]</sup> During 1990s, with the extensive application of laparoscopic cholecystectomy, two-stage endoscopic-laparoscopic method has emerged (pre- or postoperative ERCP and laparoscopic cholecystectomy), and is considered the most common approach at present.<sup>[8,9]</sup> Two-stage endoscopic-laparoscopic approach has certain disadvantages such as complication (pancreatitis, duodenal injury), twice exposure to surgery, and high costs.<sup>[7,10]</sup> There is no unanimous opinion of surgeons and researchers about one-stage laparoscopic approach, which has emerged due to increase in laparoscopy experience, and supporters of this approach are between 3–12% and even are gradually decreasing in some countries.<sup>[8]</sup>

The aim of our study is to present the comparative results of open, two-stage endoscopic-laparoscopic and one-stage laparoscopic methods applied in the treatment of cholecysto-choledocholithiasis retrospectively.

## Materials and Methods

Surgical treatment results of 229 patients with stones in gallbladder and CBD during 2003–2016 were enrolled in the study. Median age of the patients was 59 (11–92), 69 of them were men, and 160 were women (Table 1).

### Preoperative Examinations

Patients with gallstone were subject to staged examinations (Figure 1). Examinations were based on two principles: determination of stones, complications in gallbladder, and assessment of CBD. During the first stage, gallbladder is assessed by standard clinic, laboratory

examinations (ALT, AST, GGT, ALP, bilirubin, amylase) and USG, and signs of suspected choledocholithiasis are searched. Next examination plan is selected in accordance with degree of suspected CBD pathology. Patients with high suspicion (CBD dilatation, expositive mass in CBD in USG, jaundice, acute cholecystitis, signs of cholestasis, pancreatitis, cholangitis) are subject to MR-cholangiography as a clarifying examination. Patients with moderate suspicion (ALT, AST elevation) are subject to intraoperative cholangiography (IOCG). In patients without previous and current jaundice, pancreatitis and acute cholecystitis, and with normal laboratory indicators, the CBD is assessed visually during the operation. IOCG is carried out if CBD dilatation, large gallbladder duct and small stones (<3 mm) are identified during the operation.

### Surgical Technique

Patients with acute cholecystitis, obstructive jaundice, cholangitis were intervened within 12–24 hours. Three approaches were applied for cholecysto-choledocholithiasis: classical open, two-stage laparo-endoscopic and one-stage laparoscopic. In classical open method cholecystectomy CBD opening, stone removal and T-drainage were performed through upper middle or right subcostal excision. In two-stage laparo-endoscopic method, CBD stones were removed by ERCP, and laparoscopic cholecystectomy was carried out 2–3 days later (in patients with CBD stone detected before operation). In cases when the stone was identified intraoperatively, transcystic catheter was placed, and CBD stones were removed 2–3 days later by ERCP.

In one-stage laparoscopic approach, patients were subject to cholecystectomy, and CBD was examined by fiberocholedochoscope (3 mm, 3.8 mm, 5 mm). Transcystic method was initially selected for choledochoscopy, but when it was impossible, choledochotomy was conducted. Stones were removed by washing, grasper and baskets, and impacted stones were broken and removed. Urological stonebreakers were used for breaking the stones. During choledochoscopic intervention, Oddi's sphincter and intrahepatic ducts were examined in all cases. After complete stone cleaning cystic duct was clipped, and T-drainage was placed during. In all cases, subhepatic area was drained.

### Postoperative Management

Subhepatic drainage is removed after one or two days,

**Table 1. Preoperative findings of patients**

	Total (n=229)	LCE + LCBDE (n=67)	ERCP + LCE (n=84)	Open CE and CBDE (n=78)
Age	59 (11–92)	59 (11–92)	61 (14–81)	58 (9–84)
Above 70 age	31	8	15	8
Sex (Male/Female)	69/160	21/46	26/59	22/56
Biliary colic	38	11	14	13
Acute cholecystitis	76	22	28	26
Elevation of enzymes	38	9	11	18
Jaundice	92	27	34	31
Cholangitis	30	10	11	9
Pancreatitis	27	9	10	8
CBD diameter >1 cm	103	42	50	48
Single stone	74	22	26	26
Multiple stones	155	55	58	52
Impacted stones	15	5	4	6
ASA1	95	32	44	19
ASA2	99	23	24	52
ASA3	31	10	14	7
ASA4	4	2	2	0
ASA5	0	0	0	0
Pregnancy	4	4	–	1
Cardio stimulator	3	2	–	1
Cardiac problems	20	7	6	6
Cerebrovascular	5	4	–	1
Cirrhosis	7	4	2	1
Chronic hepatitis	5	2	1	2
Diabetes	31	10	11	10
Obstructive lung disease	6	3	2	2
ESRD	4	3	2	1
Mekkel	2	1	–	1

LCE: Laparoscopic choledochal exploration; LCBDE: Laparoscopic common bile duct exploration; ERCP: Endoscopic retrograde cholangiopancreatography; CE: Choledochal exploration; CBDE: Common bile duct exploration; CBD: Common bile duct; ASA: American Society of Anaesthesiologist; ESRD: End stage renal disease.

unless bile was observed. Patients with T-drainage were subject to contrast cholangiography after one and two weeks, and T-drainage was removed two weeks later, unless there are recurrent stones, distal stricture and leak. Patients were subject to clinic, laboratory and US control after 1, 3, 6 and 12 months.

### Comparison Criteria

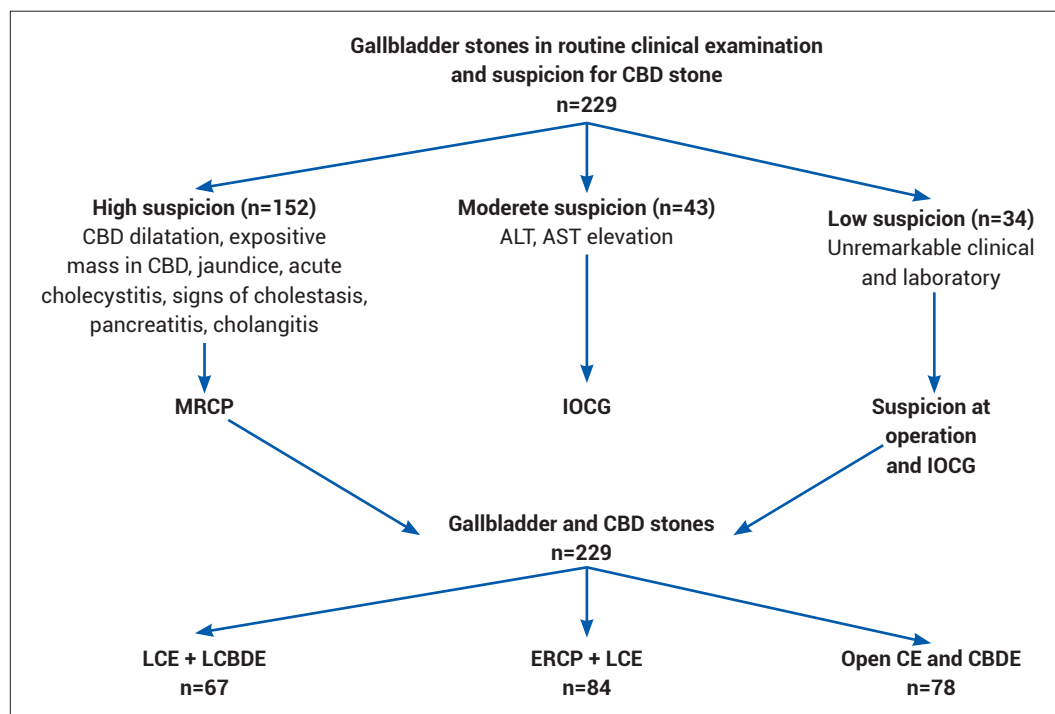
Results of three operations were compared by operation time and hospital stay, stone removal rate and complications. Operation time was taken as a period from incision

to the final suture. Clavien–Dindo classification was used for assessing complications (Table 2).

Cholangiography was taken as a basis to assess the stone removal. CBD was assessed by IOCG after ERCP, and by T-cholangiography one and two weeks after open and laparoscopic operations.

### Results

In 152 patients out of 229 (66.3%) the CBD stones was discovered by preoperative examinations, and in other patients, by intraoperative cholangiography (Figure 1). CBD



**Figure 1.** Staged examinations and results.

dilatation (44.9%) and jaundice (40.1%) were the most common signs, and multiple stones were observed in most patients (67.6%), and impacted stone in 15 patients (Table 1). Majority of patients (84.7%) were at ASA 1–2 status. Five patients were pregnant and 81 patients experienced comorbidities.

### Results of Open Cholecystectomy and Choledocholithotomy

In 74 (94.8%) patients out of 78 in open group, stone clearance was achieved (Table 3). Stones identified by postoperative cholangiography in four patients were removed

by ERCP. In open group, 41 complications (52.5%) in 26 (33.3%) patients, and lethal result in three (3.8%) patients were observed (Table 4).

Complications of first degree (16.6%) and cases requiring surgical intervention (IIIb -12.8%) were more common. In general, most common complications included wound infection (10.2%), hernia (7.6%) and sepsis (5.1%). Treatment of complications are indicated in Table 5.

### Results of Two-Stage Laparo-Endoscopic Treatment

Out of 84 patients who undergone two-stage laparo-en-

**Table 2.** Clavien-Dindo classification of postoperative complications

I degree	Deviations from normal postoperative improvement, which do not require pharmacological and invasive (surgical, endoscopic radiological) intervention. May include antiemetic, analgesics, antipyretic, electrolyte, physical therapy, wound opening.
II degree	Requires pharmacological treatment (other than I degree)
III degree	Requires invasive intervention
III a	Without general anaesthesia
III b	Under general anaesthesia
IV degree	Life-threatening complication requiring intensive care
IV a	Single organ failure
IV b	Multiorgan failure
V degree	Death

**Table 3. Perioperative findings**

	LCE + LCBDE (n=67)	ERCP+ LCE (n=84)	Open CE and CBDE (n=78)
Operating time (min)	123±7 (75–245)	152±8 (93–239)*	121±8 (75–186)
Stone removal	97% (65/67)	85.7% (72/84)*	94.8% (74/78)
Cholecystotomy	43	–	78
Transcystic	24	–	–
Hospital stay (day)	2.3±0.65 (2–7)	6.5±1.5 (3–27)*	8.2±2.7 (5–48)*

\*p≤0.05 compared to one-stage laparoscopic method (LCE + LCBDE). LCE: Laparoscopic choledochal exploration; LCBDE: Laparoscopic common bile duct exploration; ERCP: Endoscopic retrograde cholangiopancreatography; CE: Choledochal exploration; CBDE: Common bile duct exploration.

**Table 4. Complications and their degree by Cavien-Dindo classification**

	LCE + LCBDE (n=67)	ERCP+ LCE (n=84)	Open CE and CBDE (n=78)
Number of patients with complications	10 (14.9%)	21 (25%)*	26 (33.3%)*
Total number of complications	13 (19.4%)	28 (33.3%)*	41 (52.5%)*
I degree	10 (14.9%)	9 (10.7%)	13 (16.6%)
Hyperamylasemy	–	3	–
Bile leakage	3	–	1
Wound festering	4	6	8
Drainage relocation	1	–	2
Atelectasis	2	2	2
II degree	2 (2.9%)	7 (8.3%)*	9 (11.5%)*
Pancreatitis	–	5	2
Pneumonia	–	1	2
Thrombophlebitis	1	–	2
Urinary tract infection	1	1	3
IIIa degree	0%	4 (5.9%)*	5 (6.4%)*
Gastrointestinal bleeding	–	2	1
Intraabdominal abscess	–	1	2
Bile leakage/Bilioma	–	1	2
IIIb degree	1 (1.5%)	5 (5.9%)*	10 (12.8%)*
Bile leakage peritonitis	1	1	1
Intraabdominal bleeding	–	1	1
Intestine damage	–	–	–
Duodenum damage	–	3	1
Eventration	–	–	1
Intestinal obstruction	–	–	1
Postoperative hernia	–	–	5
IV degree	0%	3 (3.5%)	4 (5.1%)*
Acute sepsis and organ failure	–	3	4
V degree	0%	0%	3 (3.8%)*

\*p≤0.05 compared to one-stage laparoscopic method (LCE + LCBDE). LCE: Laparoscopic choledochal exploration; LCBDE: Laparoscopic common bile duct exploration; ERCP: Endoscopic retrograde cholangiopancreatography; CE: Choledochal exploration; CBDE: Common bile duct exploration.

**Table 5. Complication management**

Complications of I degree	
Hyperamylasemia	Conservative treatment
Bile leakage	Spontaneous recovery
Wound infection	Wound opening and dressings
Drainage dislocation	Drainage removal
Atelectasis	Physical therapy
Complications of II degree	
Pancreatitis	Conservative treatment
Pneumonia	Antibiotic treatment
Thrombophlebitis	Anticoagulant and elastic stocking
Urinary tract infection	Antibiotics treatment
Complications of IIIa degree	
Gastrointestinal bleeding	Endoscopic coagulation
Intraabdominal abscess	Percutaneous drainage
Bile leakage/bilioma	Endoscopic stent
Complications of IIIb degree	
Intraabdominal bleeding	Haemostasis with re-laparoscopy and re-laparotomy
Bowel injury	Re-laparotomy, suturing the perforation
Duodenal injury	Laparotomy, suturing the perforation, diversion, drainages (common bile duct jejunostomy, gastrostomy)
Evisseration	Re-laparotomy and prolen mesh e
Intestinal obstruction	Re-laparotomy
Complications of IV degree	
Acute sepsis and organ failure	Intensive care treatment

doscopy treatment, ERCP was conducted before laparoscopy in 58 patients, and after operation in 26 patients. Stones were cleared in 72 patients (85.7%), but retained in 12 patients, 10 of which were identified by IOCG, and two by MR-cholangiography (Table 3). Retained stones were removed by repeated ERCP in 7 patients, laparoscopic CBD exploration in 4 and open method in one patient. No lethal result was found in two-stage group, total of 28 (33.3%\*) complications were observed in 21 patients out of 84 (Table 4). Complications of lower degree (I and II degree) were more common (19%). These patients mainly experienced wound infection (7.1%) and pancreatitis (5.9%). 11.8% of complications required intervention.

### Results of One-Stage Laparoscopic Treatment

Stones were removed in 65 (97%) patients out of 67, who received one-stage treatment. Retained stones which were identified by T-cholangiography in the first week were removed by ERCP. CBD stones were removed by transcystic way in 24 patients, and by choledochotomy in 43 patients.

No lethal result was found in one-stage group, and total of 13 (19.4%\*) complications were observed in 10 patients (14.9%). Majority of complications were of the first and second degree (14.9% and 2.9%, respectively). Biliary leak and bile peritonitis were observed in one patient due to dislocation of T-drainage, and this patient was managed by re-laparoscopy.

### Comparison of Groups

Operating time was not much different between one-stage laparoscopic and open groups, but was significantly long in two-stage group (Table 3). In terms of stone removal, one-stage laparoscopic method was the most effective, but two-stage intervention was the least effective one. Hospital stay was the longest (8.2 days) in open method, and the shortest (2.3 days) in one-stage laparoscopic method. Mortality was observed in open group (3.8%), but not in other two groups.

Complications were most observed in open group (52.5%), but least in laparoscopic group (19.4%) (Table 4). Majority of



complications in laparoscopic group were of lower degree (I and II degree), while half of the complications in open group required intervention and intensive care treatment. However, complications of both low and high degrees were observed in two-stage laparo-endoscopic group.

Wound infection, pancreatitis, duodenal injury, hernia, sepsis were noticed in open group. However, pancreatitis, gastrointestinal bleeding and duodenal injury were mostly observed in two-stage laparo-endoscopic group.

## Discussion

According to the study results, comparison of three intervention methods for gallbladder and CBD stones reveals that one-stage laparoscopic cholecystectomy and choledochotomy are better than the other two methods in terms of stone removal, operating time, hospital stay and complications. Wound complications, hospital stay, mortality, severe complications are more common in open group, while in two-stage laparo-endoscopic method the stone removal rate is low, and the risk of pancreatitis, duodenal injury and gastrointestinal bleeding is high.

Currently, there is no unanimous opinion regarding the treatment of choice among three principal treatment methods of cholecysto-choledocholithiasis. Pursuant to SAGES protocol, two-stage laparo-endoscopic and one-stage laparoscopic methods demonstrate similar efficiency, and depending on opportunity and experience, both of them may be the treatment of choice.<sup>[5]</sup> According to EASL (2016) protocol, two-stage laparo-endoscopic approach is the treatment of choice, but if it is unsuccessful, one-stage laparoscopic method can be applied.<sup>[1]</sup> Several American results indicate that open approach is applied in 5–52%.<sup>[7,9]</sup> In Europe-Africa survey, one-stage laparoscopic approach is being applied in 12% of patients.<sup>[8]</sup> American study shows that during 1998-2016, supporters of two-stage approach increase, but those of laparoscopic and open methods decrease.<sup>[9]</sup>

Though the supporters of open method are few, this method is being justified in some countries due to its low costs and when laparoscopic and endoscopic approaches failure.<sup>[6,7]</sup> After open surgeries carried out in our study, common complications (33.3%), severe complications (24.3%), mortality (3.8%) and hospital stay (8.2±2.7 days) were found to be significantly higher than other methods.

The most controversial issue in the literature is the comparison between two-stage laparo-endoscopic and one-

stage laparoscopic methods. In most studies, including in randomized, meta-analysis and cohort studies, one-stage laparoscopic management showed similar results to two-stage laparo-endoscopic management, but was preferable in terms of costs, complication. One of the latest randomized studies<sup>[10]</sup> has revealed that complications (13.3% versus 4.7%), unsuccessful stone clearance rate (7% versus 3%) are more common after two-stage laparo-endoscopic management compared to one-stage laparoscopic management. According to the results of meta-analysis published in 2016, there was no significant differences between one-stage and two-stage management in terms of stone clearance rate, complication, mortality, operating time and hospital stay, however, one-stage management reduced the number of procedures and anaesthesia.<sup>[11]</sup>

Another meta-analysis revealed that compared to two-stage method, in one-stage laparoscopic method the stone clearance rate was higher, the lengths of hospital stay and operating times were shorter, but no significant difference between the two methods regarding complication and conversion to other procedures.<sup>[12]</sup>

Our study also indicates that more total and severe complications, longer hospital stay have been observed in two-stage laparo-endoscopic method compared to one-stage laparoscopic management.

The most significant disadvantage of two-stage laparo-endoscopic approach are addition to the second intervention, Oddi sphincter damage and duodenobiliary reflux. Randomized clinic study of Yuan Y and co-authors investigated the impact of endoscopic sphincterotomy and laparoscopic CBD exploration on Oddi sphincter. According to the results, three months after endoscopic sphincterotomy, basal and contraction pressures decreased, and the duodenobiliary reflux and stone recurrence rates increased.<sup>[13]</sup>

The intervention way (transcystic or transcholedocheal) and management of choledochotomy wound (primary suture, T-drainage or stend) are unsolved issues in laparoscopic CBD exploration. In our experience, we implemented transcystic in 35% cases, and transcholedocheal intervention in remaining cases. Meta-analysis by Feng Q and co-authors revealed that there were no significant differences between laparoscopic choledochotomy and transcystic interventions regarding stone clearance, general complications, operating time, however, better results were observed in transcystic group in terms of biliary

complications, hospital stay and expenses.<sup>[14]</sup> Despite of its several advantages, transcystic management also has some disadvantages such as cannulation difficulty, transition to choledochotomy in large stones,<sup>[8,15]</sup> and lithotripsy.<sup>[16]</sup> Some authors consider the transcystic approach as risky in stones of larger than 20 mm.<sup>[17]</sup>

There is no unanimous opinion regarding the completion of choledochotomy with T-drainage, primary suture or stend, which is another issue of laparoscopic choledochotomy. We used T-drainage in all patients during our study, and T-drainage dislocation was observed in one patient, which was resolved by relaparoscopy. Primary suture is found to result in bile leaks in 3-11% cases,<sup>[18-20]</sup> even in death,<sup>[20]</sup> and is risky in small diameter CBD and in less experienced hands.<sup>[19]</sup> Some authors suggest stend reduce bile leaks,<sup>[21]</sup> however additional endoscopic intervention may be required to remove the stend.

According to SAGES protocol, laparoscopic CBD exploration is a relative contraindication for older, cirrhotic patients with secondary disease.<sup>[5]</sup> However, some recent studies proved laparoscopic CBD exploration to be successful in older and cirrhotic patients.<sup>[22-24]</sup> Among our patients, serious secondary conditions were observed in 28.3% cases, including pregnancy in four patients, cirrhosis in four patients and older age in seven patients, and no complication was identified regarding such conditions.

Impacted stones comprise the main reasons of failures both in laparoscopic and endoscopic managements. We observed impacted stones in 15 patients, and five of them were removed through laparoscopy. We used urological forceps and lithotripters in our experience. Literature recommends lithotripsy and abdominal lithotripter tools for removal of riveted stones.<sup>[16,25]</sup>

Our study has a number of limitation, which include non-randomization of groups, and failure to provide dimensions of stones and choledoch.

In conclusion, according to the study results, one-stage laparoscopic cholecystectomy and CBD exploration are preferable than two-stage laparo-endoscopic and classical open methods in terms of stone clearance rate, operating time, hospital stay and complications, and may be the treatment of choice in gallbladder and bile duct stones.

## Disclosures

**Ethics Committee Approval:** The study was approved by the Local Ethics Committee.

**Peer-review:** Externally peer-reviewed.

**Conflict of Interest:** None declared.

## References

1. European Association for the Study of the Liver (EASL). EASL Clinical Practice Guidelines on the prevention, diagnosis and treatment of gallstones. *J Hepatol* 2016;65:146–81. [\[CrossRef\]](#)
2. Kama NA, Atli M, Doganay M, Kologlu M, Reis E, Dolapci M. Practical recommendations for the prediction and management of common bile duct stones in patients with gallstones. *Surg Endosc* 2001;15:942–5. [\[CrossRef\]](#)
3. Baïramov Nlu, Giuraras AS, Pashazade VA. Comparative characteristic of preoperative magnetic resonance and intraoperative cholangiography in diagnostics of the common biliary duct disorder. *Klin Khir* 2013;20–3.
4. Yin P, Wang M, Qin R, Zhang J, Xiao G, Yu H, et al. Intraoperative endoscopic nasobiliary drainage over primary closure of the common bile duct for choledocholithiasis combined with cholecystolithiasis: a cohort study of 211 cases. *Surg Endosc* 2017;31:3219–26. [\[CrossRef\]](#)
5. Overby DW, Apelgren KN, Richardson W, Fanelli R; Society of American Gastrointestinal and Endoscopic Surgeons. SAGES guidelines for the clinical application of laparoscopic biliary tract surgery. *Surg Endosc* 2010;24:2368–86. [\[CrossRef\]](#)
6. Halawani HM, Tamim H, Khalifeh F, Mailhac A, Taher A, Hobballah J, et al. Outcomes of Laparoscopic vs Open Common Bile Duct Exploration: Analysis of the NSQIP Database. *J Am Coll Surg* 2017;224:833–40. [\[CrossRef\]](#)
7. Du JW, Jin JH, Hu WX, Wang ZX, Zhao HP. Comparison of three surgical patterns for cholecysto-choledocholithiasis. *Zhonghua Yi Xue Za Zhi* 2017;97:276–9.
8. Vannijvel M, Lesurtel M, Bouckaert W, Houben B, Knol J, Vangertruyden G, et al. A survey of European-African surgeons' management of common bile duct stones. *HPB (Oxford)* 2016;18:959–64. [\[CrossRef\]](#)
9. Wandling MW, Hungness ES, Pavey ES, Stulberg JJ, Schwab B, Yang AD, et al. Nationwide Assessment of Trends in Choledocholithiasis Management in the United States From 1998 to 2013. *JAMA Surg* 2016;151:1125–30. [\[CrossRef\]](#)
10. Barreras González JE, Torres Peña R, Ruiz Torres J, Martínez Alfonso MÁ, Brizuela Quintanilla R, Morera Pérez M. Endoscopic versus laparoscopic treatment for choledocholithiasis: a prospective randomized controlled trial. *Endosc Int Open* 2016;4:E1188–93. [\[CrossRef\]](#)
11. Prasson P, Bai X, Zhang Q, Liang T. One-stage laproendoscopic procedure versus two-stage procedure in the management for gallstone disease and biliary duct calculi: a systemic review and meta-analysis. *Surg Endosc* 2016;30:3582–90.
12. Zhu HY, Xu M, Shen HJ, Yang C, Li F, Li KW, et al. A meta-analysis of single-stage versus two-stage management for concomitant gallstones and common bile duct stones. *Clin Res Hepatol Gastroenterol* 2015;39:584–93. [\[CrossRef\]](#)
13. Yuan Y, Gao J, Zang J, Zhang C, Yang X, Chen X, et al. A Randomized, Clinical Trial Involving Different Surgical Methods



- Affecting the Sphincter of Oddi in Patients With Choledocholithiasis. *Surg Laparosc Endosc Percutan Tech* 2016;26:124–7.
14. Feng Q, Huang Y, Wang K, Yuan R, Xiong X, Wu L. Laparoscopic Transcystic Common Bile Duct Exploration: Advantages over Laparoscopic Choledochotomy. *PLoS One* 2016;11:e0162885. [\[CrossRef\]](#)
  15. Quaresima S, Balla A, Guerrieri M, Campagnacci R, Lezoche E, Paganini AM. A 23 year experience with laparoscopic common bile duct exploration. *HPB (Oxford)* 2017;19:29–35.
  16. Liu J, Jin L, Zhang Z. Laparoscopic Transcystic Treatment Biliary Calculi by Laser Lithotripsy. *JLS* 2016;20. pii:e2016.00068.
  17. Otani T, Yokoyama N, Sato D, Kobayashi K, Iwaya A, Kuwabara S, et al. Safety and efficacy of a novel continuous incision technique for laparoscopic transcystic choledocholithotomy. *Asian J Endosc Surg* 2017;10:282–8. [\[CrossRef\]](#)
  18. Wen SQ, Hu QH, Wan M, Tai S, Xie XY, Wu Q, et al. Appropriate Patient Selection Is Essential for the Success of Primary Closure After Laparoscopic Common Bile Duct Exploration. *Dig Dis Sci* 2017;62:1321–6. [\[CrossRef\]](#)
  19. Liu D, Cao F, Liu J, Xu D, Wang Y, Li F. Risk factors for bile leakage after primary closure following laparoscopic common bile duct exploration: a retrospective cohort study. *BMC Surg* 2017;17:1. [\[CrossRef\]](#)
  20. Hua J, Meng H, Yao L, Gong J, Xu B, Yang T, et al. Five hundred consecutive laparoscopic common bile duct explorations: 5-year experience at a single institution. *Surg Endosc* 2016 Dec 30 [Epub ahead of print], doi: 10.1007/s00464-016-5388-6. [\[CrossRef\]](#)
  21. Xu Y, Dong C, Ma K, Long F, Jiang K, Shao P, et al. Spontaneously removed biliary stent drainage versus T-tube drainage after laparoscopic common bile duct exploration. *Medicine (Baltimore)* 2016;95:e5011. [\[CrossRef\]](#)
  22. Zheng C, Huang Y, Xie E, Xie D, Peng Y, Wang X. Laparoscopic common bile duct exploration: a safe and definitive treatment for elderly patients. *Surg Endosc* 2017;31:2541–7.
  23. Zhu JG, Guo W, Han W, Zhang ZT. Laparoscopic Transcystic Common Bile Duct Exploration in the Elderly is as Effective and Safe as in Younger Patients. *J Laparoendosc Adv Surg Tech A* 2017;27:48–52. [\[CrossRef\]](#)
  24. Gui L, Liu Y, Qin J, Zheng L, Huang YJ, He Y, et al. Laparoscopic Common Bile Duct Exploration Versus Open Approach in Cirrhotic Patients with Choledocholithiasis: A Retrospective Study. *J Laparoendosc Adv Surg Tech A* 2016;26:972–7.
  25. Jiang H, Wang SY, Jin XL, Jin JC, Gu HB, Zhang FM. Surgical treatment of incarcerated calculi via laparoscopic bile duct exploration using laparotomy biliary lithotomy forceps. *Exp Ther Med* 2016;12:2314–6. [\[CrossRef\]](#)