



Cecal Ameboma: An Uncommon Inflammatory Cecal Mass in Elderly

Yaşlılarda Nadir Görülen Enflamatuvar Bir Çekal Kitle: Çekal Ameboma

© Ahmet Burak Çiftci¹, © Aziz Bulut¹, © İdris Özdaş², © Nezahat Yıldırım³

¹Bingöl State Hospital, Clinic of General Surgery, Bingöl, Turkey

²Bingöl State Hospital, Clinic of Radiology, Bingöl, Turkey

³Elazığ Training and Research Hospital, Clinic of Pathology, Elazığ, Turkey

ABSTRACT

Amebiasis is an infectious disease caused by the intestinal protozoan *Entamoeba histolytica*, and is one of the most common parasitoses worldwide. Ameboma is a rare presentation of invasive amebiasis. Amebomas are generally difficult to diagnose and can mimic colon carcinoma. In this report, we describe an elderly woman who presented to the emergency department with cramping abdominal pain. The patient underwent surgery after an initial diagnosis of inflamed cecal mass and appendicitis. Histological examination of the surgical specimen showed the presence of trophozoites of *E. histolytica*, leading to a diagnosis of cecal ameboma. Although the elderly population has a higher incidence of colonic malignancy, ameboma should be considered in the differential diagnosis of colonic tumors, especially in endemic areas.

Keywords: Ameboma, *Entamoeba histolytica*, invasive amebiasis, cecal cancer

ÖZ

Amebiyazis, bir intestinal protozoan olan *Entamoeba histolitika*'nın neden olduğu enfeksiyöz bir hastalık olup dünyada en sık görülen parazitozlardan biridir. Ameboma invaziv amebiyazisin nadir görülen bir şeklidir. Amebomaların tanısı genellikle zordur ve kolon kanserleri ile karışabilmektedir. Bu yazıda acil servise şiddetli karın ağrısı ile başvuran ileri yaş bir kadın hasta sunulmaktadır. Bu hastaya inflame çekal kitle ve plastrone apandisit ön tanılarıyla acil sağ hemikolektomi yapılmış olup ameliyat sonrası cerrahi spesimenlerin patolojik incelemesinde *E. histolitika* trofozitleri görülerek çekal ameboma tanısı konuldu. Yaşlı popülasyonda kolon malignitelerinin insidansı yüksek olmasına karşın özellikle endemik bölgelerde çekal kitelerin ayrıncı tanısında amebomalar akılda tutulmalıdır.

Anahtar Kelimeler: Ameboma, *Entamoeba histolitika*, invaziv amebiyazis, çekal kanser

Introduction

Amebiasis is a worldwide infectious disease caused by a potent protozoan *Entamoeba histolytica*.¹ It has significantly higher prevalence rates in developing countries that have poorer socioeconomic conditions and sanitation levels. But it also seen in specific risk groups in the developed world.^{2,3} Ameboma is a rare presentation of amebiasis occurring in 1.5% of cases and it usually occurs in the untreated or inadequately treated patients with amebiasis years after the last attack of dysentery.⁴ Because of the variability of signs and symptoms and the rarity of ameboma the diagnosis can be easily overlooked. In most cases diagnosis can be

made only after surgical interventions as this case that we presented here.

Case Report

A 74 year old female patient applied to emergency service with abdominal pain in the right lower quadrant and nausea. She had no fever, diarrhea, vomiting or weight loss but the pain severity increased in two days and she had experienced poor appetite and general malaise. Physical examination revealed severe tenderness, rebound tenderness and palpable mass in the right lower quadrant of abdomen. At admission the blood pressure and pulse rate of the patient were normal.



Address for Correspondence/Yazışma Adresi: Ahmet Burak Çiftci MD

Bingöl State Hospital, Clinic of General Surgery, Bingöl, Turkey

Phone: +90 530 527 73 02 E-mail: drburakciftci@yahoo.com ORCID ID: orcid.org/0000-0002-1814-4008

Received/Geliş Tarihi: 22.10.2017 Accepted/Kabul Tarihi: 01.02.2018

She had no family history of colorectal carcinoma. Initial laboratory test results showed normal complete blood counts, electrolytes, liver and renal functions. Contrast-enhanced tomography (CT) scan of the abdomen revealed concentric and diffuse thickening of the cecum wall and the wall of appendix was edematous and mesenteric several lenf nodes and heterogeneous density were detected in pericecal region (Figure 1). Because of these findings a preliminary diagnosis was made of an inflamed cecal mass and a perforated and plastron appendicitis. An emergency explorative laparotomy was performed due to the findings of CT scan that reveals the suspicion of the perforated appendicitis. During surgery we observed a cecal mass measured about 8x6 cm in dimension and invaded to lateral part of the abdominal wall. A right hemicolectomy with ileotransverse anastomosis was performed. Postoperative treatment involved antibiotherapy (ceftriaxone 2x1 gr and metronidazole 3x500 mg). Histopathological examination of the resected specimen revealed the deep ulcer in the cecum mucosa and the presence of trophozoites of *E. histolytica* (Figure 2). So invasive amebiasis with colonic ameboma was diagnosed.

Discussion

Amebiasis is still an important public health problem in developing countries and it is second leading cause of death from parasitic disease worldwide.¹ Trophozoites of *entamoeba histolytica* are responsible for the amebic colitis. Transmission of amebic colitis is mostly by ingestion of contaminated food or water containing the cyst form of this parasite but venereal transmission by fecal-oral route also occurs.² Its clinical findings are generally; a several-week history of gradual onset of abdominalpain and tenderness,

diarrhea, bloody stools and weight loss. Extraintestinal manifestations such as liver and brain abscess can also be seen.² In this case the clinical findings were atypical because the patient had no diarrhea, weight loss or the history of rectal bleeding and the abdominal pain was acute onset. But she lived in an area where amebiasis is not so rare. Ameboma is an inflammatory, exophytic and cicatricial mass lesion usually seen in patients with long standing and untreated or inadequately treated amebic infections.⁵ Amebomas are variable in size and may cause obstructive symptoms.⁶ Its differential diagnosis should be made with Crohn's disease and complicated appendicitis in younger patients, and colon cancer and diverticulitis in the elderly ones.⁷ Our patient was 74 years old and she had a palpable mass and rebound tenderness in the right lower quadrant. But she had no obstructive symptoms and no history of an amebic infection treatment. CT revealed concentric thickening of the cecum wall, pericecal heterogeneous density and suspicion of perforated appendicitis. When considered these clinical and radiologic findings, an initial diagnosis was made of an inflamed cecal mass and appendicitis and surgical intervention was seen necessary. In literature there has been only a few cases of cecal ameboma reported until now. And in almost all reported cases, ameboma was diagnosed after surgery which was performed for a preliminary diagnosis of carcinoma, appendicitis or lymphoma.⁸ As many other case reports in literature, in this case we diagnosed cecal ameboma after histopathologic evaluation of surgical specimen. On contrary there is only a few reported cases that ameboma diagnosed before surgery and improved after few weeks of medical treatment. These medical treatments contain oral metronidazole therapy for 5-10 days and to eradicate colonization its followed by a luminal agent as

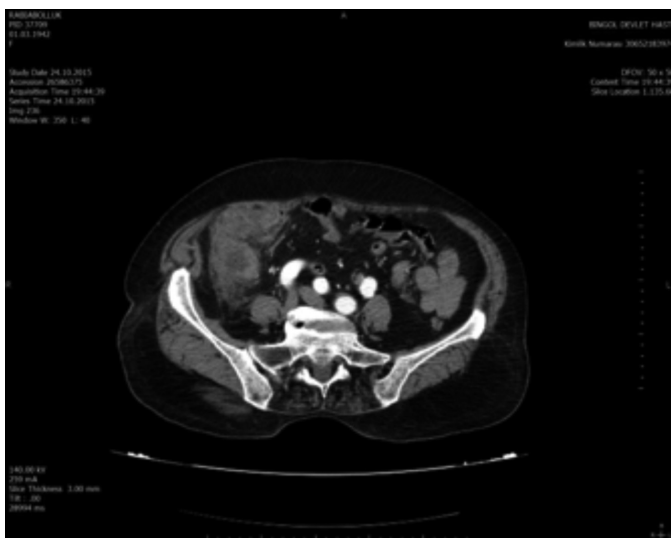

Figure 1. Computed tomography scan of the abdomen showing diffuse thickening of the cecum wall

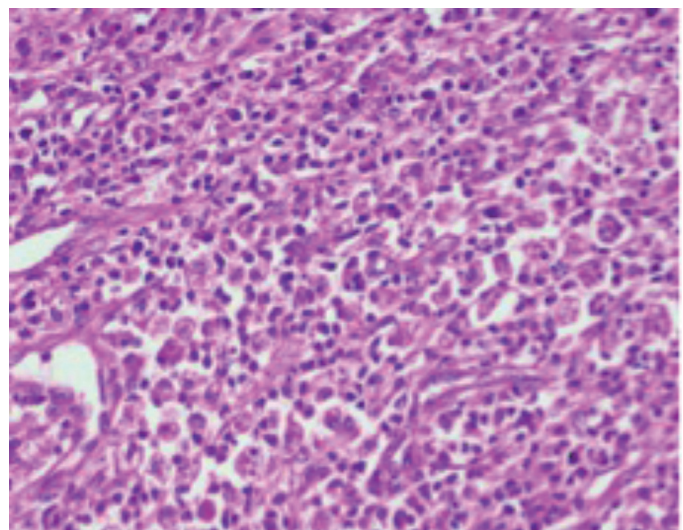


Figure 2. Histopathological examination showing ingested red blood cells and the trophozoites of *E. histolytica*

paromomycin, iodoquinol or diloxanide furoate for 5-20 days.⁸ Since medical treatment of ameboma is reported as successful the physicians must be more careful in the approach of cecal mass lesions to avoid unnecessary surgery. In conclusion differentiating ameboma from colorectal carcinoma is still problematic. Because the diagnosis can be easily overlooked ameboma should be kept in mind in the differential diagnosis of colonic mass lesions especially in endemic areas.

Ethics

Informed Consent: Consent form was filled out by the patient.

Peer-review: External and internal peer-reviewed.

Authorship Contributions

Surgical and Medical Practices: A.B.Ç., A.B., İ.Ö., N.Y., Concept: A.B.Ç., A.B., Design: A.B.Ç., Data Collection or Processing: A.B.Ç., A.B., Analysis or Interpretation: A.B.Ç., A.B., Literature Search: A.B.Ç., Writing: A.B.Ç.

Conflict of Interest: No conflict of interest was declared by the authors.

Financial Disclosure: The authors declared that this study received no financial support.

References

1. Stanley SL Jr. Amoebiasis. *Lancet* 2003;361:1025-1034.
2. Petri WA Jr, Singh U. Diagnosis and management of amebiasis. *Clin Infect Dis* 1999;29:1117-1125.
3. Hardin RE, Ferzli GS, Zenilman ME, Gadangi PK, Bowne WB. Invasive amebiasis and ameboma formation presenting as a rectal mass: An uncommon case of malignant masquerade at a western medical center. *World J Gastroenterol* 2007;13:5659-5661.
4. Misra SP, Misra V, Dwivedi M. Ileocecal masses in patients with amebic liver abscess: etiology and management. *World J Gastroenterol* 2006;12:1933-1936.
5. Jaiswal SS, Mehra R, Pattnaik MR. Amoeboma-lest we forget!!! *Indian J Surg* 2015;77:190-192.
6. Pirtti OP, Koçak E, Güler O, Koçak G, Altunkaya C, Caydere M, Köklü S. An unusual cause of unilateral hydronephrosis: invasive colonic amebiasis. *Ren Fail* 2012;34:798-800.
7. Mishra A, Azzabi M, Hamadto M, Mishra J, Bugren S, Hresha W, Addalla S, Ehtuish EF. Right abdominal mass: keep an open mind. *Libyan J Med* 2010;5.
8. Simşek H, Elsürer R, Sökmensüer C, Balaban HY, Tatar G. Ameboma mimicking carcinoma of the cecum: case report. *Gastrointest Endosc* 2004;59:453-454.