



A Rare Case of Anorectal Abscess due to Foreign Ingested Foreign Body

Yutulmuş Yabancı Cisime Bağlı Gelişen Anorektal Apse Olgusu

© Hakan Eroğlu, © Tuğçe Çalt, © Mahmut Serkan Sarıkaya, © Resul Kuzu, © Murat Başbuğ, © Hayrullah Derici

Balıkesir University Faculty of Medicine, Department of General Surgery, Balıkesir, Turkey

ABSTRACT

Anorectal abscesses caused by foreign bodies are rare, but are often caused by the ingestion of fish bones or bone fragments. Rectal or proctoscopic examination performed under general anesthesia can be used to diagnose a perianal abscess but may not reveal the foreign body, which can lead to the development of chronic abscesses. Draining the abscess and removing the causative foreign body allows for rapid healing. Therefore, foreign bodies should be considered in the etiology of chronic abscesses that do not resolve with drainage. In this study, an anorectal abscess due to a swallowed toothpick is presented.

Keywords: Ingested foreign body, anorectal abscess, perianal abscess

ÖZ

Yabancı cisime bağlı olarak oluşan anorektal apseler klinikte pek karşılaşılmayan durumlar arasında bulunmaktadır. Anal apselerin oluşumuna neden olan yabancı cisimler arasında balık kılıcı ve kemik parçasına sık rastlanmaktadır. Genel anestezi altında yapılacak rektal muayene ve/veya proktoskopik tetkik anal apse tanısını koydursa da yabancı cisimlerin varlığını göstermeyebilir dolayısıyla apse zamanla kronikleşebilir. Bununla birlikte yabancı cisime bağlı apselerde drenajın yapılması ve apseye neden olan etkeni çıkarılması hastanın kliniğinde hızla düzelmeye sağlamaktadır. Drenaja rağmen düzelmeyen kronik apselerde yabancı cisim etiolojide düşünülmelidir. Bu çalışmada yutulmuş kürdana bağlı olarak gelişmiş anorektal apse olgusu sunulmuştur.

Anahtar Kelimeler: Yutulmuş yabancı cisim, anorektal apse, perianal apse

Introduction

Anorectal abscess is an infectious, suppurative disease that usually develops due to the infection of anal glands in the intersphincter plane. The most common cause in the etiology of anorectal abscesses and fistulas is obstruction of anal crypts due to increased intersphincter tone.^{1,2} Less common causes include Crohn's disease, trauma, malignancies, and immunodeficiencies.³ Perianal apse related to foreign bodies, which are among etiologic causes, is rarely encountered.⁴ An anorectal abscess placement was given in 42.7 perianal, 22.7% ischiorectal, 21.4% intersphincteric, 7.3% supralelevator in a study involving one thousand patients from Ortiz et al.⁵ In this study; it is intended to present a case of abscess in the ischiolectal region which is formed by the swallowed toothpick treated in our clinic.

Case Report

A 54-year-old female patient admitted to a medical center with complaints of pain and fever in the right gluteal area that have began about a week ago. In the medical center, the patient's perianal abscess was drained. Due to the presence of gaseous, purulent drainage from the perianal abscess pouch and color change in the skin, the patient was referred to our clinic with the preponderance of "fournier gangrene". In the physical examination of the patient; there was a incision made for drainage on the right gluteal region. It was observed that there was a blue-purple color change on the skin around the incision and the necrosis of subcutaneous fat tissue. There was a second abscess pouch in the area of approximately 8*10 cm in the area of about 4-5 cm above of the incision. Vital findings were stable,



Address for Correspondence/Yazışma Adresi: Hakan Eroğlu MD

Balıkesir University Faculty of Medicine, Department of General Surgery, Balıkesir, Turkey

Phone: +90 544 285 20 83 E-mail: eroglu.hakan@yandex.com ORCID ID: orcid.org/0000-0002-7466-5051

Received/Geliş Tarihi: 20.10.2017 Accepted/Kabul Tarihi: 21.12.2017

fever was 37.5 °C. Laboratory values were, white blood cell: $11.9 \times 10^3/\mu\text{L}$, C-reactive protein $>210 \text{ mg/dL}$. There was no tenderness in the abdominal examination did not reveal additional findings on digital rectal examination except mild tenderness. The affected area was irrigated with abundant saline-diluted hydrogen peroxide solution and dressed. The patient was hospitalized for intravenous (i.v.) antibiotic therapy, debridement and dressing. Considering that the drainage of the abscess was not enough, debridement was planned under anesthesia. Sterile dyeing and covering were performed in the jack knife position under spinal anesthesia. In the examination with an anoscop, no internal orifice was seen in the rectum after saline-diluted hydrogen peroxide solution was given to the abscess cavity. The first drainage incision was extended to the superiolateral direction where necrosis progressed. For microbiological culture, multiple samples are collected from the abscess cavity. The cavity was irrigated with abundant saline and the necrosis tissues were debrided. In the necrosis area which advances towards the ischioanal area a hard object was palpated, with appropriate exploration a yellowish foreign body was seen (Figure 1). Foreign body removed from ischioanal area with the help of forceps. It was seen that the foreign body was a broken toothpick (Figure 2). After adequate debridement and drainage, one penrose drain was placed in the ischioanal area. It was learned that the patient had taken a toothpick soaked meal about 10-15 days ago in her detailed anamnesis after the operation and did not use her prosthetic teeth that day. 2*1 sterile dressings per day were performed in the clinic. *Escherichia coli*, *Klebsiella pneumonia* and *Citrobacter koseri* grown in culture results were susceptible to imipenem. The patient was consulted with the infectious diseases clinic and imipenem 2*400 mg i.v. was started in the direction of the recommendation. On the 14th day of antibiotherapy, the infection was clinically regressed, and appropriate oral antibiotics were prescribed, and the patient was called to polyclinic control one week later. On control examination, it was seen that subcutaneous area was began

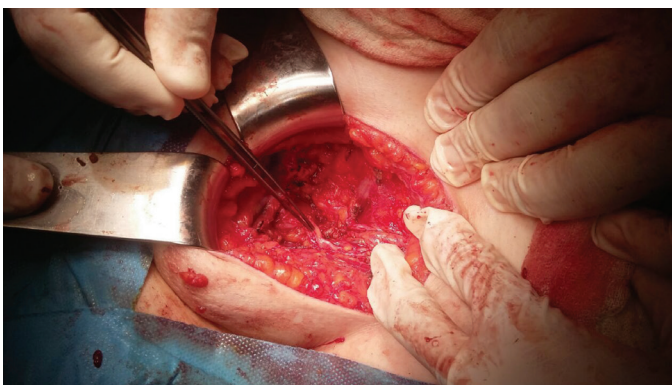


Figure 1. Foreign body spotted during the exploration of the abscess

to close up with granulation tissue. At the 3rd week (Figure 3) and 6th week (Figure 4) controls, the patient's complete healing was observed.

Written informed consent was obtained from patient in this case.

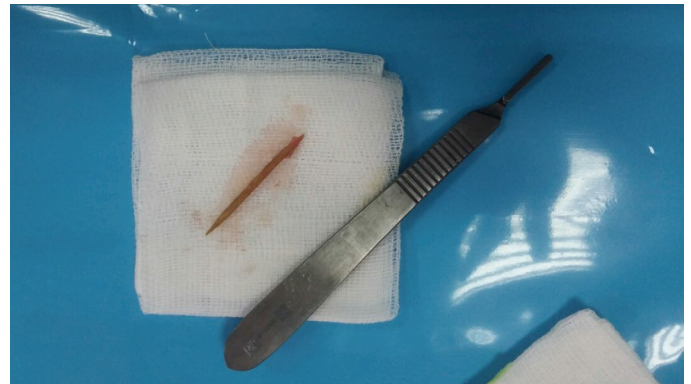

Figure 2. The toothpick removed from the abscess

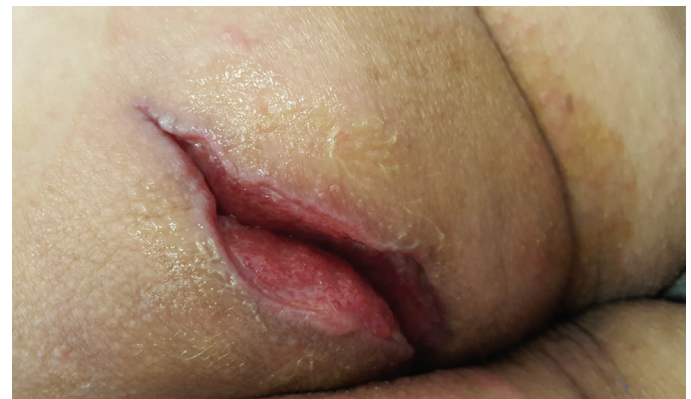

Figure 3. The patient's healing observed 3 weeks after the procedure

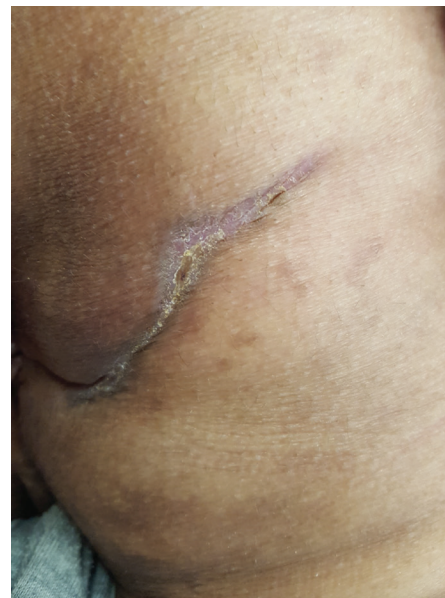

Figure 4. The patient's healing observed 6 weeks after the procedure

Discussion

A perianal abscess due to foreign bodies is not a common occurrence. Patient's anamnesis, which was taken at the beginning, has an important place in revealing the cause. Patients with foreign body related anorectal abscesses; usually have sensory loss in the mouth, dental problems and anal stenosis due to anal surgery or unconsciousness periods like alcoholics.^{6,7,8} Therefore, patients may not be able to give a foreign body swallowing story in their anamnesis.⁴ There was no foreign body swallowing story in our patient anamnesis too. The pain at the beginning of the process is due to the spasm in the external and internal anal sphincter caused by foreign bodies stuck in the anal canal but then the abscess formation around the foreign body, which is pushed out of the wall of the anal canal.⁸ In our case the patient had an ongoing pain for a week. Presence of perianal abscess can be diagnosed with careful rectal examination and proctoscopy⁹ but foreign body may not be detected. Additional imaging modalities (e.g. endoscopic rectal ultrasound, computed tomography and magnetic resonance imaging) may be needed for the diagnosis of abscess in suspected cases.¹⁰ No additional imaging was needed because the foreign body was not mentioned or suspected in the patient's history. A proper exploration of the abscess during the operation is very important for diagnosis.⁴ In our case, no foreign body was detected because of the lack of proper exploration during the first intervention at the external center. As a result, the healing process has not been achieved sufficiently. The removal of a foreign body in such a case, exploration with an adequate incision will provide rapid treatment of the present situation.^{4,11} As a result, swallowed foreign bodies may cause perianal abscess formation. In cases of perianal abscesses with predisposing factors and prolonged healing, the presence of foreign bodies is one of the conditions that should be kept in mind.

Ethics

Informed Consent: Written informed consent was obtained from patient in this case.

Peer-review: External and internal peer-reviewed.

Authorship Contributions

Surgical and Medical Practices: H.E., Concept: H.E., M.B., Design: H.E., H.D., Data Collection or Processing: T.Ç., M.S.S., Analysis or Interpretation: H.E., R.K., Literature Search: T.Ç., Writing: H.E., M.B.

Conflict of Interest: No conflict of interest was declared by the authors.

Financial Disclosure: The authors declared that this study has received no financial support.

References

1. Rizzo JA, Naig AL, Johnson EK. Anorectal abscess and fistula-in-ano: evidence-based management. *Surg Clin North Am* 2010;90:45-68.
2. Hamadani A, Haigh PI, Liu IL, Abbas MA. Who is at risk for developing chronic anal fistula or recurrent anal sepsis after initial perianal abscess?. *Dis Colon Rectum* 2009;52:217-221.
3. Whiteford MH. Perianal abscess/fistula disease. *Clin Colon Rectal Surg* 2007;20:102-109.
4. Delikoukos S, Zacharoulis D, Hatzitheofilou C. Perianal abscesses due to ingested foreign bodies. *Int J Clin Pract* 2005;59:856-857.
5. Ortiz H, Marzo M, de Miguel M, Ciga MA, Otezia F, Armendariz P. Length of follow-up after fistulotomy and fistulectomy associated with endorectal advancement flap repair for fistula in ano. *Br J Surg* 2008;95:484-487.
6. Singh RP, Gardner JA. Perforation of the sigmoid colon by swallowed chicken bone: case reports and review. *Int Surg* 1981;66:181-183.
7. Ooi BS, Ho YH, Eu KW, Nyam D, Leong A, SeowChoen F. Management of anorectal foreign bodies: a cause of obscure anal pain. *Aust N Z J Surg* 1998;68:852-855.
8. Carlson GL, Ingram G. Acute anal pain and ingested foreign body impaction. *Br J Clin Pract* 1990;44:244-246.
9. Reddy SK, Griffith GS, Goldstein JA et al. Toothpick impaction with localized sigmoid perforation: successful colonoscopic management. *Gastrointest Endosc* 1999;50:708-709.
10. Takada M, Kashiwagi R, Sakane M, Tabata F, Kuroda Y. 3D-CT diagnosis for ingested foreign bodies. *Am J Emerg Med* 2000;18:192-193.
11. Seow C, Leong AF, Goh HS. Acute anal pain due to ingested bone. *Int J Colorectal Dis* 1991;6:212-213.