

Traumatic Perforation of the Sigmoid Colon

Travmatik Sigmoid Kolon Perforasyonu

Nurullah Damburacı, Barış Sevinç, Ömer Karahan

Uşak University Faculty of Medicine, Department of General Surgery, Uşak, Turkey

ABSTRACT

Although it is a rare condition, traumatic colonic perforation has a significant morbidity and mortality rate. Especially in cases with sexual abuse, the patient may not give detailed information and this may cause delays in diagnosis and treatment. Here, we present a patient with acute abdominal findings who was diagnosed with traumatic colonic perforation intraoperatively. In cases with gastrointestinal perforation, traumatic colonic perforation should be kept in mind and patients must be asked about trauma.

Keywords: Colonic perforation, trauma, acute abdomen

ÖZ

Travmatik kolon perforasyonları nadir görülmesine rağmen acil cerrahi gerektiren bir durumdur. Özellikle cinsel istismar olgularında hastaların hikayeyi gizleme çabası nedeniyle tanı ve tedavide olan gecikmeler mortalite ve morbiditeyi artırmaktadır. Bu yazımızda akut karın sendromu ile acil servise başvuran, ameliyat esnasında kolon perforasyonu tespit edilen bir olguyu sunmayı amaçladık. Gastrointestinal sistem perforasyonu düşünülen olgularda kolonik yaralanmalarda akıld tutularak bu hastalar travma yönünden de sorgulanmalıdır.

Anahtar Kelimeler: Kolon perforasyonu, travma, akut batın

Introduction

Foreign bodies inserted into the anal canal may cause complications in the rectum and sigmoid colon which require urgent intervention.¹ Rectal foreign bodies can be encountered in the form of self-administered treatments for constipation and anorectal diseases, related to sexual abuse, in psychiatric cases, through accidents, and often used for sexual purposes.^{1,2} Diagnosis of pathologies caused by rectal foreign body can be delayed due to conflicting statements from patients and their relatives and inconsistencies with physical examinations.³ Here in, we present a case of sigmoid colon perforation detected in a patient undergoing emergency surgery for acute abdomen.

Case Report

A 45-year-old male patient presented to the emergency department complaining of abdominal pain for the last 2 days. The patient had a history of chronic constipation and chronic hemorrhoids. On physical examination performed

in the emergency department, there was generalized abdominal sensitivity, defense, and rebound. Laboratory testing revealed C-reactive protein level was 214 mg/L and white blood cell count was 4800. Pneumoperitoneum was observed on abdominal X-ray in standing position (Figure 1). Computed tomography revealed a extensive free air in the abdomen but no perforation site could be detected (Figure 2). Based on these findings, the patient was admitted for emergency surgery with a preliminary diagnosis of hollow organ perforation. During the operation, the abdomen was found to be dirty with extremely purulent contents and the small bowel was distended. On exploration, an area of perforation about 1 cm in diameter was observed in the sigmoid colon. The mesothelium was opened and evaluated but no signs of diverticulitis were detected. There were no other pathological findings distal to the lesion or in the rest of the colon. Resection with Hartmann colostomy was performed due to the extremely contaminated abdomen. While informing the patient postoperatively, it was learned



Address for Correspondence/Yazışma Adresi: Nurullah Damburacı MD

Uşak University Faculty of Medicine, Department of General Surgery, Uşak, Turkey

Phone: +90 276 224 46 41 E-mail: nurullahdamburaci@gmail.com ORCID ID: orcid.org/0000-0001-7574-4571

Received/Geliş Tarihi: 30.05.2017 Accepted/Kabul Tarihi: 16.08.2017

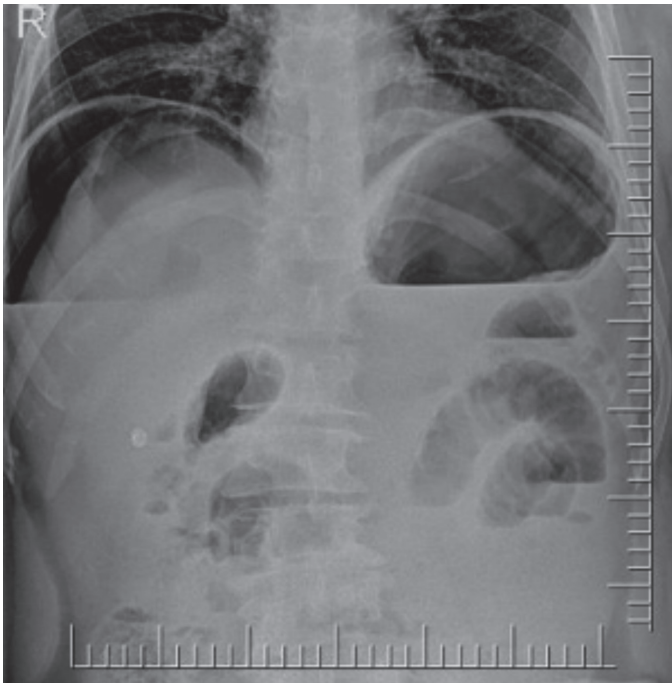


Figure 1. Pronounced pneumoperitoneum is apparent on abdominal X-ray

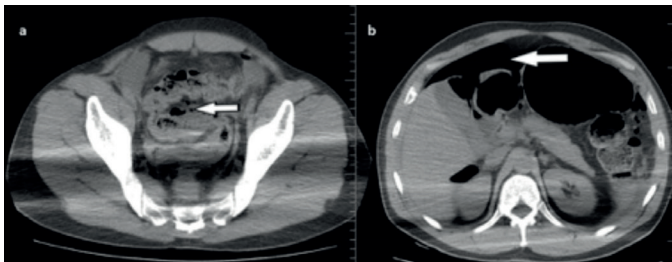


Figure 2. Computed tomography shows pneumoperitoneum; a) Free gas is seen above the liver (white arrow), b) Localized free gas is seen between the bowel loops surrounding the sigmoid colon (white arrow)

that he had self-administered an enema using a garden hose inserted into his anal canal in order to relieve constipation. The hose was determined to have caused the perforation. The patient passed stool the stoma on postoperative day 2 and was discharged on day 5 after tolerating oral intake. The patient provided written informed consent for this case report.

Discussion

Injury of the anorectal region or the presence of a foreign body in the rectum is often reported as forensic cases because they generally occur as a result of trauma, accidents, and sexual abuse. Cases of foreign bodies in the rectum due to attempted self-treatment have been previously reported. There is also a case reported in the literature with a psychiatric disorder (Munchausen's syndrome).⁴

In 1984, J.A. Berry classified spontaneous colonic perforations into “stercoral” and “idiopathic” perforations. Stercoral perforations occur at or near the recto-sigmoid junction as a result of ischemic necrosis caused by hardened feces. Perforations associated with ischemia are round or oval in shape, while the perforations seen in idiopathic cases are linear.⁵ About 3.2% of all colonic perforations are stercoral.⁶ Idiopathic perforations are reported less frequently than stercoral perforations. In terms of prognosis, idiopathic perforations are better because there is less fecal contamination.⁷

Insertion of foreign bodies into the rectum is encountered more frequently in young and middle-aged men than in women. The purpose for young and middle-aged men is usually anal eroticism, while in older individuals it is done to alleviate constipation or for prostate massage.^{1,8} In the present case, the patient used a garden hose in an attempt to eliminate constipation and rectal prolapse.

Such patients generally tend to hide the truth when they present to the emergency department. They usually report abdominal pain, constipation, and complaints of anorectal pain and hemorrhoids with intermittent bleeding.^{1,8,9} In our case, the patient presented no findings other than clinical signs of acute abdomen syndrome.

There are reports in the literature of various complications associated with rectal foreign bodies, including rectal bleeding, rectal mucosal abrasion and tears, rectal inflammation, pararectal abscess and fistulization to neighboring organs, rectal perforation, and peritonitis.¹⁰ Despite detecting no injury to the anal canal or rectal area in our patient, we found a sigmoid colon injury causing peritonitis.

The clinical presentation of cases with colonic perforation differs in terms of the area affected and peritoneal irritation. Abdominal pain and distention are the most common symptoms. Diagnostic direct X-rays may show pneumoperitoneum in less than 10% of these patients. This can also be evaluated as normal, especially because the air is located within the retroperitoneal space or under the skin. Computerized tomography is particularly helpful in such cases.^{11,12} Computed tomography using triple or dual contrast media can be used to monitor patients, especially those who are being followed without surgery.¹³

There is a lack of consensus regarding the treatment of patients with pneumoperitoneum and suspected colonic perforation. Clinician experience and site of perforation are important when monitoring treatment in these cases. They can be managed both operatively and nonoperatively.^{14,15} Although treatment of colonic perforations traditionally required open surgery, in recent years there has been a

trend toward nonoperative follow-up in selected cases with laparoscopic interventions as necessary.¹⁶

The patient discussed here presented to the emergency department with clinical picture of acute abdominal syndrome. Because he did not give sufficient information about the events leading to his condition, the clinical findings were evaluated as upper gastrointestinal system perforation. This case illustrates the need to obtain a more detailed history in the emergency department, especially in patients with psychological problems and clinical presentation of acute abdomen.

Ethics

Informed Consent: Consent form was filled out by the participant.

Peer-review: Internally peer-reviewed.

Authorship Contributions

Surgical and Medical Practices: N.D., B.S., Concept: N.D., B.S., Design: N.D., B.S., Data Collection or Processing: N.D., Ö.K., Analysis or Interpretation: N.D., Ö.K., Literature Search: N.D., B.S., Writing: N.D., B.S.

Conflict of Interest: No conflict of interest was declared by the authors.

Financial Disclosure: The authors declared that this study received no financial support.

References

1. Atila K, Sirmen S, Astarcioğlu H, Canda E. Rektumda yabancı cisim: Dört olgu sunumu. *Ulus Travma Derg* 2004;10:253-256.
2. Berghoff KR, Franklin ME Jr. Laparoscopic-assisted rectal foreign body removal: report of a case. *Dis Colon Rectum* 2005;48:1975-1977.
3. Oruç C, Uğur M, Akkücüçük S, Çelikel A, Kiliç E, Ortanca İ. Inorganic Foreign Body in Rectum: Case Report. *Int J Basic Clin Med* 2015;3:131-134.
4. Khan SA, Davey CA, Khan SA, Trigwell PJ, Chintapatla S. Munchausen's syndrome presenting as rectal foreign body insertion: a case report. *Cases J* 2008;1:243.
5. Huttunen R, Heikkinen E, Larmi TK. Stercoraceous and idiopathic perforations of the colon. *Surg Gynecol Obstet* 1975;140:756-760.
6. Maurer CA, Renzulli P, Mazzucchelli L, Egger B, Seiler CA, Buchler MW. Use of accurate diagnostic criteria may increase incidence of stercoral perforation of the colon. *Dis Colon Rectum* 2000;43:991-998.
7. Al Shukry S. Spontaneous perforation of the colon clinical review of five episodes in four patients. *Oman Med J* 2009;24:137-141.
8. Tüzün A, Aday U, Önder A, Kapan M, Keleş C. Barsak tıkanıklığı ve üriner retansiyona yol açan rektal yabancı cisim. *Genel Tıp Dergisi* 2011;21:71-73.
9. Demir MT, Baydin A, Ersözlü E, Güzel M, Özsoy S. A Rare Reason of Intestinal Obstruction: A Foreign Body in Rectum. *J Clin Anal Med* 2013;4(Suppl 3):252-254.
10. Albayrak D, İbiş AC, Hatipoğlu AR, İrfanoğlu ME. Rektumda yabancı cisim: üç olgu sunumu. *Trakya Univ Tıp Fak Derg* 2007;24:240-243.
11. Park HR, Baek SK, Bae OS, Park SD. Treatment of colon perforation associated with colonoscopy. *J Korean Soc Coloproctol* 2008;24:322-328.
12. Gedebo TM, Wong RA, Rappaport WD, Jaffe P, Kahsai D, Hunter GC. Clinical presentation and management of iatrogenic colon perforations. *Am J Surg* 1996;172:454-457.
13. Shanmuganathan K, Mirvis SE, Chiu WC, Killeen KL, Scalea TM. Triple-contrast helical CT in penetrating torso trauma: a prospective study to determine peritoneal violation and the need for laparotomy. *AJR Am J Roentgenol* 2001;177:1247-1256.
14. Holmes JF, Offerman SR, Chang CH, Randel BE, Hahn DD, Frankovsky MJ, Wisner DH. Performance of helical computed tomography without oral contrast for the detection of gastrointestinal injuries. *Ann Emerg Med* 2004;43:120-128.
15. Avgerinos DV, Llaguna OH, Lo AY, Leitman IM. Evolving management of colonoscopic perforations. *J Gastrointest Surg* 2008;12:1783-1789.
16. Hansen AJ, Tessier DJ, Anderson ML, Schlinkert RT. Laparoscopic repair of colonoscopic perforations: indications and guidelines. *J Gastrointest Surg* 2007;11:655-659.