



# Grade II-III Hemorrhoidal Disease Treatment: Rubber Band Ligation versus Hemorrhoidal Artery Ligation

## Grade II-III Hemoroidal Hastalık Tedavisi: Lastik Bant Ligasyonu ve Hemoroidal Arter Ligasyonu Karşılaştırılması

İbrahim Yılmaz<sup>1</sup>, Dursun Özgür Karakaş<sup>2</sup>, İlker Sücüllü<sup>3</sup>, Mehmet Saydam<sup>1</sup>

<sup>1</sup>Dışkapı Yıldırım Beyazıt Training and Research Hospital, Clinic of General Surgery, Ankara, Turkey

<sup>2</sup>Okmeydanı Training and Research Hospital, Clinic of General Surgery, İstanbul, Turkey

<sup>3</sup>Haydarpaşa Sultan Abdülhamid Han Training and Research Hospital, Clinic of General Surgery, İstanbul, Turkey

### ABSTRACT

**Aim:** Comparison the application and effectiveness of hemorrhoidal artery ligation (HAL) and rubber band ligation (RBL) techniques in the treatment of grade II and III hemorrhoidal disease.

**Method:** HAL was performed in 50 patients between December 2006 and May 2007 and RBL was performed in 96 patients between August 2011 and October 2014. A total of 146 patients with grade II-III hemorrhoidal disease were included in this retrospective study. Surgery duration, performed ligations, pain on postoperative day 7 visual analog scale, complications, and ratio of symptom-free patients at 6 months were statistically analyzed for both procedures.

**Results:** Patients who underwent HAL returned to work earlier and had less pain on postoperative day 7 than those who underwent RBL; in addition, the RBL procedure was statistically more cost-effective and had shorter surgery times. There was no statistical difference between the HAL and RBL groups in proportion of patients who were symptom-free at postoperative 6 months (94% and 96.6%, respectively).

**Conclusion:** The RBL and HAL procedures are both effective and have low complication, and can be used safely together or separately in the treatment of grade II-III hemorrhoidal disease.

**Keywords:** Hemorrhoidal disease, rubber band ligation, hemorrhoidal artery ligation

### ÖZ

**Amaç:** Grade II ve III hemoroidal hastalık tedavisinde; lastik bant ligasyonu (LBL) ve hemoroidal arter ligasyonu (HAL) yöntemlerinin uygulama şekli ve etkinliğini karşılaştırmaktır.

**Yöntem:** HAL işlemi Aralık 2006-Mayıs 2007 tarihleri arasında 50 hastaya ve LBL işlemi Ağustos 2011-Eylül 2014 tarihleri arasında 96 hastaya uygulandı. Grade II-III hemoroidal hastalığı olan toplam 146 hasta retrospektif çalışmamıza dahil edildi. Operasyon süresi, uygulanan ligasyon sayısı, postoperatif 7. gün vizüel analog skala değerleri, komplikasyonlar ve 6. ay sonunda semptomsuz hasta sayıları her iki işlem için istatistiksel olarak karşılaştırıldı.

**Bulgular:** HAL yöntemi uygulanan hastaların LBL uygulanan hastalara göre daha erken işe döndüğü ve postoperatif 7. gün daha az ağrılarının olduğu ve LBL yönteminin ise daha düşük maliyete ve kısa operasyon süresine sahip olduğu istatistiksel olarak saptandı. Semptomsuz hasta oranları 6. ay sonunda her iki yöntem için de benzer olarak (%94 ve %91,66) saptanmış olup istatistiksel olarak fark yoktu.

**Sonuç:** HAL ve LBL yöntemleri yüksek etkinlik ve düşük komplikasyon oranlarıyla grade II-III hemoroidal hastalık tedavisinde ayrı ayrı veya birlikte güvenle uygulanabilir.

**Anahtar Kelimeler:** Hemoroidal hastalık, lastik bant ligasyonu, hemoroidal arter ligasyonu



Address for Correspondence/Yazışma Adresi: İbrahim Yılmaz MD

Dışkapı Yıldırım Beyazıt Training and Research Hospital, Clinic of General Surgery, Ankara, Turkey

Phone: +90 505 812 75 55 E-mail: dibrabimiyilmaz@yahoo.com

Received/Geliş Tarihi: 28.02.2017 Accepted/Kabul Tarihi: 03.05.2017

## Introduction

Hemorrhoidal disease has been one of the most distressing diseases since the dawn of human, and many procedures have been described for treatment until today.<sup>1</sup> Hemoroidectomy which includes hemorrhoidal cushions' removal from anal canal, is the choice of treatment, though its high complication rates; such as fecal incontinence, anal stricture and high postoperative pain.<sup>2</sup> Hemorrhoidal cushions are the part of normal anatomy and physiology of anal canal and also have an important role in anal continence,<sup>3</sup> so keeping in mind this hemoroidectomy shouldn't be gold standard for hemorrhoidal disease treatment. The ideal surgical procedure has to target minimal tissue damage with low complication rates and minimal postoperative pain and be proper for physiological anatomy of anal region.<sup>4</sup>

Rubber band ligation (RBL) is defined by Barron for the first time in 1963, includes placing a rubber band at the base of the hemorrhoid cushion with a special instrument above dentate line and following with ischemic necrosis ulceration and tissue fixation with the formation of scar tissue.<sup>5</sup> Procedure is reported as; an effective, outpatient, safe, easy to use and non-surgical procedure with high patients' satisfaction and low postoperative complication rates for hemorrhoidal disease<sup>6</sup> which seems to fulfil the ideal surgery technique description above. RBL can be performed under any type of anesthesia; topical, local, regional or general anesthesia after a rectal cleansing before surgery. In one session of treatment maximum 3 band ligations replacement at least 2 cm away from dentate line is recommended to prevent postoperative pain.<sup>7</sup> Recurrence rates vary from 11% to over 50% and especially for grade IV prolapsing hemorrhoidal disease cases RBL procedure seems to be ineffective but rebanding could be done at any time.<sup>6</sup>

Hemorrhoidal artery ligation (HAL) technique has been described as the ligation of submucosal superior hemorrhoidal artery terminal branches with the help of a Doppler probe. HAL was first discribed in 1995 by Morinaga et al.<sup>8</sup> as the selective ligation of submucosal superior hemorrhoidal artery distal branches which leads decreasing blood flow to hemorrhoidal cushions, results in shrink and following scar tissue formation lifts cushions back into anal canal. It is a non-excisiniol and outpatient procedure for hemorrhoidal disease. Reccurence rates at 6<sup>th</sup> month were reported as high as 80-90%. The procedure can be done any type of anesthesia; with rectal cleansing, there is no limitation for number of ligations or treatment session numbers. None major complications were reported and seems to fulfil the ideal surgery technique description above as RBL.<sup>9</sup>

Both RBL and HAL are reported effective, safe and outpatient procedures with low complication rates for grade II-III hemorrhoidal disease treatment.<sup>10,11</sup>

The aim of this study is to compare the application and effectiveness of HAL and RBL techniques in grade II-III hemorrhoidal disease treatment.

## Materials and Methods

HAL procedure performed 50 patients through December 2006 to May 2007 and RBL performed to 96 patients through August 2011 to October 2014. Total 146 patients with grade II or III hemorrhoidal disease were included in this retrospective study. Patients medical records were examined retrospectively after obtaining institutional ethical permission and informed written consent was waived because of the retrospective nature of study. The study was approved by the Haydarpaşa Sultan Abdülhamid Han Training and Research Hospital Local Ethics Committee (Approval number: 065).

Length of operation time, performed ligations, postoperative 7<sup>th</sup> day visual analog scale (VAS), complications and rate of symptom free patients at 6<sup>th</sup> month were retrospectively analyzed with SPSS 16 software (SPSS Inc. Chicago, Illinois) for both procedures. The chi-square or Fisher's exact tests were used to analyze multiple variables. Values of p less than 0.05 were considered statistically significant. Postoperative pain was measured by VAS which 0 corresponds to "no pain" and 10 to "maximum pain" postoperative first and 7<sup>th</sup> days.

RBL procedure was performed under topical anesthesia. Topical 5% lidocaine applied to anoderm and into anal canal. After 5 minutes anoscope inserted into anal canal and ligations were made. Maximum 3 ligations were made in one session, and always watched out to be away at least 2 cm away from dentate line (Figure 1). Bands were removed in three cases because of severe intraoperative pain and then the patients were rebanded.

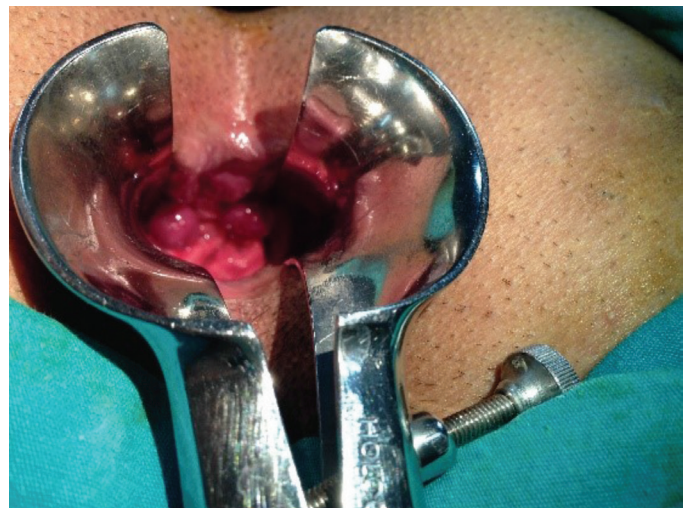


Figure 1. Rubber band ligation procedure

HAL procedures were done by Transanal Haemorrhoidal Dearterialiser (THD®-G.F. Medical Division, Correggio, Italy), device and special equipments. Local anesthesia was achieved by injection of mixture of 5 mL 2% prilocaine and 5 mL 0.9% NaCl equally to cutaneous and subcutaneous regions of 3-6-9-12 o'clock perianal areas around the anus. THD device was placed into the anal canal and anoscope rotated clockwise to search for an arterial flow Doppler sound. An eight-shaped suture was applied to the area of arterial sound using absorbable suture. Loss of the arterial sound was regarded as the sign of successful ligation (Figure 2). The procedure was completed when the arterial flow sounds disappeared.

Grade I and IV hemorrhoidal disease cases were excluded from study.

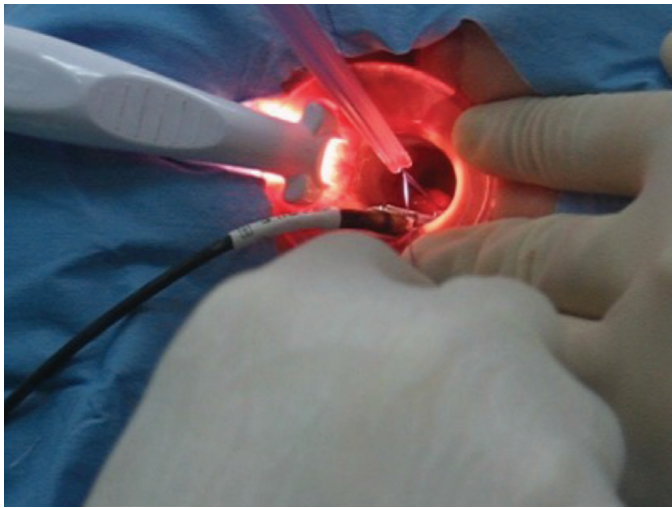


Figure 2. Hemorrhoidal artery ligation procedure

## Results

HAL procedure was applied to 50 patients (29 female and 21 male). The average age was 26.4 (20-54) years and 22 (44%) patients had grade II hemorrhoidal disease whose most presenting symptom was bleeding (76%). RBL procedure was applied to 96 patients (24 female and 72 male). The average age was 24.8 (20-46) years and 69 (71.8%) patients had grade II hemorrhoidal disease whose most presenting symptom was also bleeding (71.8%). There wasn't statistically significant difference between two groups except higher number of male patients in RBL group (Table 1).

Rectal cleansing was performed at the night of a day before and morning of the operation for both techniques and was enough for performing procedures. Local anesthesia for HAL cases and topical anesthesia for RBL cases were performed. Intraoperative no additional anesthesia was required and all patients tolerated.

To avoid postoperative pain and decrease VAS; maximum attention was shown for ligations and bandings were far away at least 2 cm from dentate line for both procedures. Maximum 3 with a mean 2.2 bandings in one session was applied for RBL cases but if needed additional bandings performed with additional sessions. Ligation replacement continued until arterial sounds disappear in proximal anal canal which meant effective ligation was done and mean 5.8 ligations were performed for Doppler-guided HAL (DGHAL) group. Comparing two groups; although number of ligations were statically significant ( $p < 0.05$ ), it was clinically insignificant. Time off work mean was 2.8 days for HAL group and 7.4 days for RBL group which was significant ( $p < 0.05$ ). The difference was due to the patients' beginning work after bands' dropping from anal canal.

Table 1. Preoperative patients' characteristics comparison of rubber band ligation and hemorrhoidal artery ligation

	HAL	RBL	p*
Number of patients	50 (29 F, 21 M)	96 (24 F, 72 M)	p=0.14
Age (years)	26.4 (mean)	24.8 (mean)	NS
Grade II patients (n)	22 (44%)	41 (42.7%)	NS
Grade III patients (n)	28 (56%)	55 (53.1%)	NS
Duration of complaints (months)	6.4	7.1	NS
Main complaints			
Bleeding	38 (76%)	69 (71.8%)	NS
Prolapsus	24 (48%)	42 (43.7%)	NS
Pain	27 (54%)	51 (53.1%)	NS
Itching	20 (40%)	35 (36.4%)	NS

\*P values calculated with the Pearson chi-square test (significant:  $p < 0.05$ )

HAL: Hemorrhoidal artery ligation, RBL: Rubber band ligation, NS: Not significant, F: Female, M: Male

Postoperative mean VAS was 1.7 for HAL patients and 2.4 for RBL cases which was statically significant ( $p < 0.05$ ).

Mean operation time for RBL group was 16.2 minutes and shorter than DGHAL cases which was 20 minutes ( $p < 0.05$ ). The cost ratio of RBL was lower than HAL because of special instruments and Doppler probe necessity.

Patients were examined at 6<sup>th</sup> month by physical examination and anoscopy for success rates of both procedures. Symptom free patients were recorded as successful procedure. HAL and RBL had similar success rates respectively: 94% and 91.6% at 6<sup>th</sup> month for grade II-III hemorrhoidal disease treatment.

No major complications were recorded. Bleeding and postoperative pain were the minor complications of both procedures which were treated easily (Table 2).

## Discussion

Hemorrhoidal disease is one of the most prevalent benign anorectal disease described as symptomatic enlargement, prolapse or bleeding of hemorrhoidal cushions which are the anal canal's normal functional and anatomical structures.<sup>1</sup> Also taking into account their roles in continence, minimal tissue damage should be targeted during surgery.<sup>3</sup> Despite Milligan-Morgan hemorrhoidectomy and modified versions accepted as the gold standard treatment of hemorrhoidal disease; surgeons intend to prefer minimally invasive outpatient techniques because of hemorrhoidectomy

complications such as postoperative pain and sphincter damage.<sup>2</sup> Having thought that treatment of choice procedure should not have major complications, we aimed to discuss and compare RBL and HAL for grade II-III hemorrhoidal disease treatment which were both reported as an outpatient procedures with minimal postoperative pain and complication rates and high patient satisfaction rates in literature.<sup>11</sup>

Grade II-III hemorrhoidal disease cases included in this study. Because we considered that grade I cases should be treated by conservative methods without surgery and grade IV cases with mucosal prolapses should be treated more effectively by other surgical procedures such as; HAL + Mucopexy, stapler hemorrhoidopexy or classic hemorrhoidectomy due to our clinical experience as reported in the literature.<sup>12</sup>

RBL and HAL could be performed to all hemorrhoidal disease patients. RBL is contraindicated in immune deficiency patients because of perianal sepsis risk and anticoagulant medicated patients because of late severe hemorrhage,<sup>13</sup> but any significant contraindication is not defined for HAL technique.<sup>14</sup> Both procedures can be done any type of anesthesia with only rectal cleansing. The type of anesthesia is important for elderly patients with comorbidities. We performed two procedures under topical and local anesthesia and didn't encounter with locoregional or general anesthesia complications. Two procedures can be performed to patients who couldn't get general or locoregional anesthesia safely and easily.

Table 2. Comparison results of rubber band ligation and hemorrhoidal artery ligation

	DGHAL	RBL	p
Cleansing	Rectal cleansing	Rectal cleansing	
Type of anesthesia	Local	Topical	
Hospital stay	Outpatient	Outpatient	
Mean operation time (minutes)	20 minute	16.2 minute	<0.05
Mean number of ligations	5.8	2.2	<0.05
Time off work (days)	2.8 days	7.4 days	<0.05
Postoperative VAS (1 <sup>st</sup> week)	1.7	2.4	<0.05
Major complications	None	None	
Success rate (6 <sup>th</sup> month)	94%	91.66%	NS
Major complication	None	None	
Complications	8	13	
Bleeding	3	7	
Pain	5	6	
Infection	None	None	
Cost	300€	100€	<0.05

DGHAL: Doppler-guided hemorrhoidal artery ligation, RBL: Rubber band ligation, VAS: Visual analog scale, NS: Not significant

No major postoperative complications were reported after HAL technique, but postoperative lethal complications such as acute perianal sepsis, tetanus-related deaths and pyogenic liver abscess have been reported for RBL.<sup>15</sup> HAL procedure is a new technique and doesn't have long-term results and high number of cases, so we concluded that being new could decrease the major complication rates. It seems that over years we could face HAL's rare but deadly complications. There were no major complications for both two techniques except postoperative minor bleeding and pain which were easily treated in our study.

Sohn et al.<sup>16</sup> reported that they applied HAL and Shanmugam et al.<sup>17</sup> reported RBL as a daily surgery and discharged all of the patients at the same day as similar to this study. In Dal Monte et al.'s<sup>18</sup> study, 330 patients evaluated one week after HAL with VAS and postoperative pain score was 1.7. In our study, VAS score on the postoperative first week was 1.7. Post-banding pain is the most popular complication of RBL in the literature and Lam and Felt-Bersma<sup>19</sup> reported postoperative VAS 5.5 on the day of RBL procedure and suggested anal cooler for post-banding pain. It is obvious that pain is related to banding area's relation to dentate line. In our experience banding at least 2 cm away from dentate line will decrease postoperative pain like in our study; postoperative first week mean VAS was 2.4 compare to HAL group it was statistically significant ( $p < 0.05$ ). The advantage of performing RBL under topical anesthesia was; after banding near to dentate line the patient had pain during banding. In three cases we had to remove bands and rebanded for RBL cases. If the procedures performed correctly; there would be less postoperative pain for either RBL or HAL.

Cantero et al.<sup>20</sup> reported that return to work time as 2-3 days for HAL procedure and our study yielded a mean of 2.8 days. Murie et al.<sup>21</sup> reported work off time 3 days which was 7.4 days in our study which was statistically significant compared with HAL cases. RBL cases returned their work after bands' removal from anal canal which led 5-11 days which created difference.

Doppler probe and special proctoscope requirements increased markedly the cost ratio of HAL when compared to cost ratio of RBL. RBL concluded cheaper procedure than HAL for hemorrhoidal disease treatment.

Comparison of five years follow up results both RBL and HAL have similar results 75-90% and 73-90% respectively.<sup>6,9</sup> The success rate decreases with the increase of the follow-up period in both procedures. The direct proportion of follow-up period and recurrence rate is considered to be related with the continuation of etiologic factors and revascularization due to wound healing process. The success rates at 6<sup>th</sup> month follow-up period for both

techniques were similar rates as 90-95% in our study which was statistically insignificant.

In summary; HAL performed patients return to work earlier and had less pain at postoperative 7<sup>th</sup> day than RBL performed patients; in addition, RBL group had shorter operation time and more cost-effective than HAL group statistically in grade II-III hemorrhoidal diseases treatment. Symptom free patient rates at 6<sup>th</sup> month were similar and both procedures were highly effective with minimal postoperative complications.

RBL and HAL techniques have satisfactory short-term results for grade II-III hemorrhoidal disease treatment and both techniques were assessed as easy to perform, repeatable, minimal postoperative complications and can be used safely together or separately.

### Ethics

**Ethics Committee Approval:** The study was approved by the Haydarpaşa Sultan Abdülhamid Han Training and Research Hospital Local Ethics Committee (Approval number: 065).

**Informed Consent:** Consent form was waived because of retrospective nature of study.

**Peer-review:** Internally peer-reviewed.

### Authorship Contributions

Surgical and Medical Practices: İ.Y., Concept: İ.Y., İ.S., Design: D.Ö.K., Data Collection or Processing: M.S., İ.Y., Analysis or Interpretation: İ.Y., M.S., D.Ö.K., Literature Search: D.Ö.K., Writing: İ.Y., M.S.

**Conflict of Interest:** No conflict of interest was declared by the authors.

**Financial Disclosure:** The authors declared that this study received no financial support.

### References

1. Bruch HP, Roblick UJ. Pathophysiology of hemorrhoids. *Chirurg* 2001;72:656-659.
2. Bleday R, Pena JP, Rothenberger DA, Goldberg SM, Buls JG. Symptomatic hemorrhoids: Current incidence and complications of operative therapy. *Dis Colon Rectum* 1992;35:477-481.
3. Lohsiriwat V. Hemorrhoids: from basic pathophysiology to clinical management. *World J Gastroenterol* 2012;18:2009-2017.
4. Altomare DF, Roveran A, Pecorella G, Gaj F, Stortini E. The treatment of hemorrhoids: guidelines of the Italian Society of Colorectal Surgery. *Tech Coloproctol* 2006;10:181-186.
5. İskender Sayek. *Basic Surgery*. 3th ed. 2004:1256-1262.
6. Iyer VS, Shrier I, Gordon PH. Long-term outcome of rubber band ligation for symptomatic primary and recurrent internal hemorrhoids. *Dis Colon Rectum* 2004;47:1364-1370.
7. Sneider EB, Maykel JA. Diagnosis and management of symptomatic hemorrhoids. *Surg Clin North Am* 2010;90:17-32.
8. Morinaga K, Hasuda K, Ikeda T. A novel therapy for internal hemorrhoids: ligation of the hemorrhoidal artery with a newly devised instrument (Moricorn) in conjunction with a Doppler flowmeter. *Am J Gastroenterol* 1995;90:610-613.

9. Giordano P, Overton J, Madeddu F, Zaman S, Gravante G. Transanal hemorrhoidal dearterialization: a systematic review. *Dis Colon Rectum* 2009;52:1665-1671.
10. Ramirez JM, Aguilera V, Elia M, Gracia JA, Martínez M. Doppler-guided hemorrhoidal artery ligation in the management of symptomatic hemorrhoids. *Rev Esp Enferm Dig* 2005;97:97-103.
11. Shehata A, Saleh AF, Elheny A. Clinical outcome after Doppler-guided hemorrhoidal artery ligation and rubber-band ligation for the treatment of primary symptomatic hemorrhoids. *Egyptian J Surgery* 2016;35:5-10.
12. Sun Z, Migaly J. Review of Hemorrhoid Disease: Presentation and Management. *Clin Colon Rectal Surg* 2016;29:22-29.
13. KU JJ, Marfan M, Wall D. Pyogenic liver abscess after haemorrhoidal banding. *ANZ J Surg* 2005;75:828-830.
14. Yılmaz İ, Sücüllü İ, Karakaş DÖ, Özdemir Y, Yücel E, Akin ML. Doppler-guided hemorrhoidal artery ligation: experience with 2 years follow-up. *Am Surg* 2012;78:344-348.
15. Bat L, Melzer E, Koler M, Dreznick Z, Shemesh E. Complications of rubber band ligation of symptomatic internal hemorrhoids. *Dis Colon Rectum* 1993;36:287-290.
16. Sohn N, Aronoff JS, Cohen FS, Weinstein MA. Transanal hemorrhoidal dearterialization is an alternative to operative hemorrhoidectomy. *Am J Surg* 2001;182:515-519.
17. Shanmugam V, Thaha MA, Rabindranath KS, Campbell KL, Steele RJ, Loudon MA. Systematic review of randomized trials comparing rubber band ligation with excisional haemorrhoidectomy. *Br J Surg* 2005;92:1481-1487.
18. Dal Monte PP, Tagariello C, Sarago M, Giordano P, Shafi A, Cudazzo E, Franzini M. Transanal haemorrhoidal dearterialisation: nonexcisional surgery for the treatment of haemorrhoidal disease. *Tech Coloproctol* 2007;11:333-339.
19. Lam TJ, Felt-Bersma RJ. A novel device reduces anal pain after rubber band ligation: a randomized controlled trial. *Tech Coloproctol* 2012;16:221-226.
20. Cantero R, Balibrea JM, Ferrigni C, Sanz M, García Pérez JC, Pérez R, Luffiego A, Forero RG, Balibrea JL. Doppler-guided transanal haemorrhoidal dearterialisation. An alternative treatment for haemorrhoids. *Cir Esp* 2008;83:252-255.
21. Murie JA, Mackenzie I, Sim AJ. Comparison of rubber band ligation and haemorrhoidectomy for second- and third-degree haemorrhoids: a prospective clinical trial. *Br J Surg* 1980;67:786-788.