



# Rare Complications of an Unproblematic Colonoscopy: Subcutaneous Emphysema, Pneumoretroperitoneum and Pneumomediastinum

## Sorunsuz Tamamlandığı Düşünülen Kolonoskopinin Nadir Bir Komplikasyonu: Deri Altı Amfizem, Pnömoretroperitoneum ve Pnömomediastinum

**Durmuş Ali Çetin, Ebubekir Gündeş, Hüseyin Çiyiltepe, Ulaş Aday, Kamuran Cumhuri Değer, Erdal Polat**

Kartal Koşuyolu High Speciality Training and Research Hospital, Clinic of Gastroenterological Surgery, İstanbul, Turkey

### ABSTRACT

Colonoscopy is a commonly used procedure for diagnosis and treatment. Perforation during colonoscopy is a rare complication. We aimed to present a case which is extremely rare with pneumoretroperitoneum, pneumomediastinum and subcutaneous emphysema occurred after perforation during colonoscopy.

**Keywords:** Colonoscopy, perforation, subcutaneous emphysema, pneumoretroperitoneum, pneumomediastinum

### ÖZ

Kolonoskopi tanı ve tedavi amacıyla yaygın olarak kullanılan bir yöntemdir. Kolonoskopi uygulaması sırasında perforasyon nadir görülen bir komplikasyondur. Biz perforasyon sonrası çok daha nadir olarak görülen pnömoretroperitoneum, pnömomediastinum ve deri altı amfizem gelişen olgumuzu sunmayı amaçladık.

**Anahtar Kelimeler:** Kolonoskopi, perforasyon, deri altı amfizem, pnömoretroperitoneum, pnömomediastinum

## Introduction

Colonoscopy is a method widely used for diagnosis and treatment. Colonoscopic perforation is rarely seen with an incidence rate of nearly 0.15-0.19%.<sup>1,2</sup> Subdiaphragmatic air, intraperitoneal air, pneumoretroperitoneum, pneumothorax and subcutaneous emphysema may be seen following colonic perforation. Herein, clinical presentation, diagnosis and treatment of a case with retroperitoneal air, pneumomediastinum and subcutaneous emphysema after colonoscopy have been reported.

## Case Report

An 80-year-old female patient visited our polyclinic for abdominal pain and constipation for a long time. Colonoscopy

procedure was performed under sedation. Colonoscopy demonstrated a diminutive polyp in the sigmoid colon, and polypectomy was performed using forceps. No pathology was detected in the other colonic segments. The procedure was completed without problem. The physical examination of the patient, who visited the emergency room with shortness of breath and back pain 12 hours after colonoscopy, revealed crepitation in the neck and anterior chest wall. Abdominal examination was unremarkable. On her laboratory analysis, white blood cell count was 7600/mm<sup>3</sup>, hemoglobin was 13.9 gr/dL, and hematocrit was 42%. Chest x-ray demonstrated subcutaneous emphysema (Figure 1). No subdiaphragmatic air was detected on plain abdominal radiography in standing position (PARSP). Accordingly, the patient underwent



Address for Correspondence/Yazışma Adresi: Durmuş Ali Çetin MD

Kartal Koşuyolu High Speciality Training and Research Hospital, Clinic of Gastroenterological Surgery, İstanbul, Turkey

Phone: +90 505 437 86 67 E-mail: drdac2001@hotmail.com

Received/Geliş Tarihi: 31.05.2016 Accepted/Kabul Tarihi: 02.07.2016

©Turk J Colorectal Dis, Published by Galenos Publishing House.

This article is distributed under the terms of the "Creative Commons Attribution NonCommercial 4.0 International Licence (CC BY-NC 4.0)".

thoracic and abdominal computed tomography (CT). CT revealed pneumomediastinum, pneumoretroperitoneum, intraperitoneal air and subcutaneous emphysema (Figure 2, 3, 4). The patient, who had no peritoneal irritation sign or leukocytosis, was hospitalized for observation based on existing findings. Oral intake was discontinued and antibiotherapy was arranged. On the 3<sup>rd</sup> day of hospitalization, oral liquid diet was started because her abdominal examination was unremarkable and the passage of intestinal gas and stool was positive. The patient, who tolerated oral intake, was discharged from the hospital without problem.

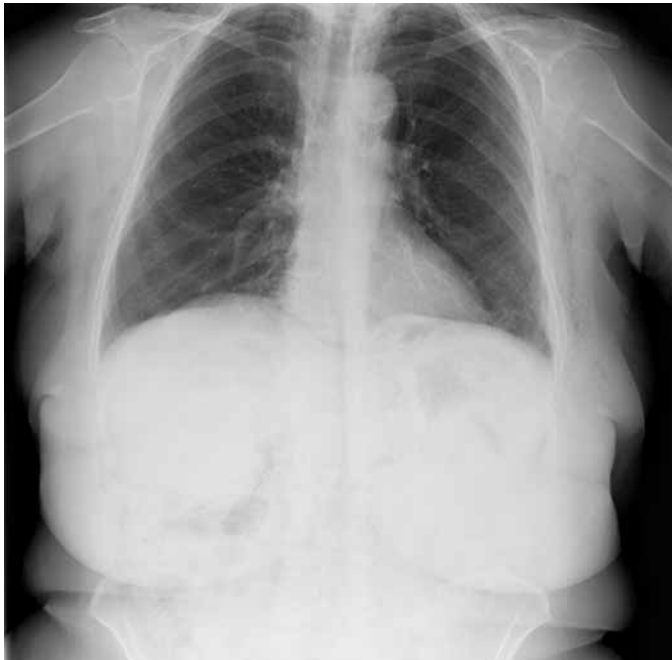

Figure 1. Subcutaneous emphysema on the chest x-ray

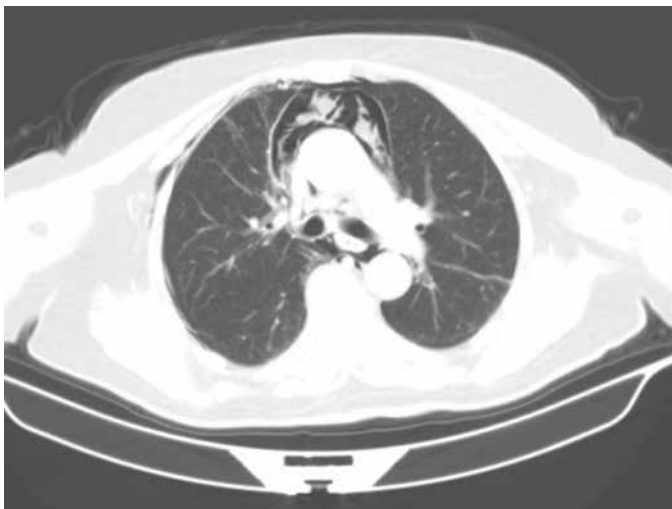


Figure 2. Pneumomediastinum on thorax computed tomography

## Discussion

Colonoscopy is widely used as a diagnostic and therapeutic tool in the colorectal diseases. There may be many complications associated with colonoscopy. Bleeding is the most prevalent complication, where perforation is less common. It has been suggested that many different mechanisms including pneumatic, mechanical and therapeutic mechanisms cause perforation. The incidence of perforation increases in the patients who have colonic mass, diverticula, inflammatory bowel diseases or history of previous abdominal surgery.<sup>3</sup> In the present case, we considered perforation due to therapeutic procedure.

In case of perforation, extracolonic air may pass through the retroperitoneal tissue layers and cause subcutaneous emphysema in the neck, axilla, anterior chest wall and scrotum. Moreover, it may lead to pneumothorax,

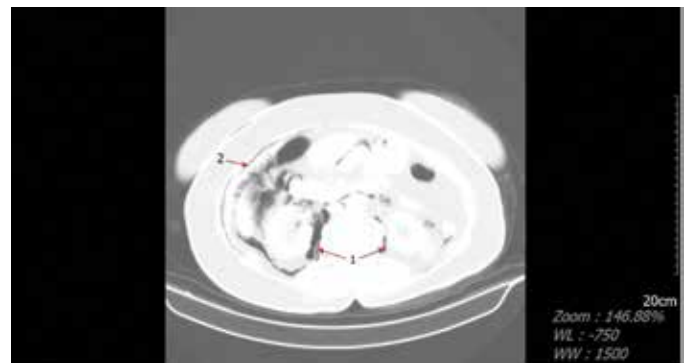


Figure 3. Retroperitoneal (1) and intraperitoneal (2) air on abdominal computed tomography

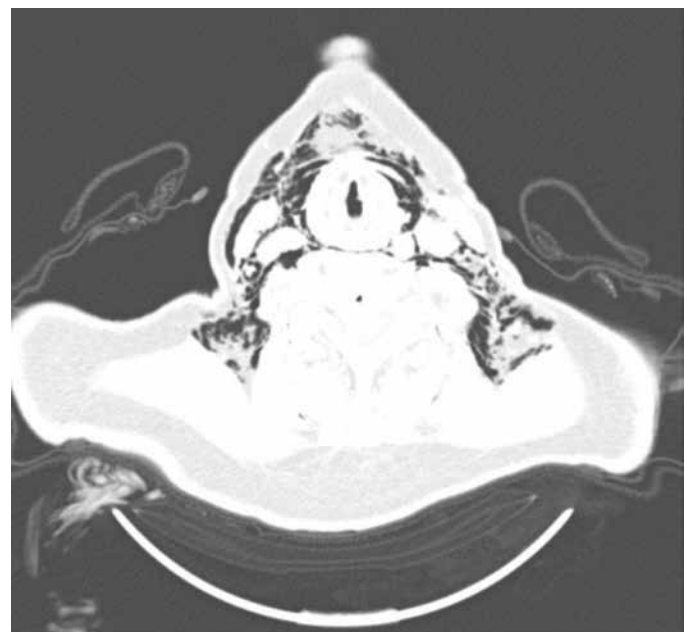


Figure 4. Subcutaneous emphysema in the neck and anterior chest wall on thorax computed tomography

pneumopericardium, pneumomediastinum and pneumatosis cystoides intestinalis.<sup>4,5,6</sup> In the present case, PARSP revealed no subdiaphragmatic free air but limited intraperitoneal and retroperitoneal air was detected on thoracic and abdominal CT. In addition, pneumomediastinum and subcutaneous emphysema in the neck and anterior chest wall were observed.

Approaching to perforation after colonoscopy includes conservative, endoscopic and surgical approaches. Conservative approach consists of bed rest, discontinuation of oral intake, broad-spectrum antibiotherapy, and close monitoring via radiological methods. Patients that require conservative therapy account for a small proportion of overall perforation cases, and the symptoms of the cases regress in 24 hours. Such patients generally have retroperitoneal perforation and/or perforation after therapeutic procedure.<sup>3</sup> In the present case, surgical intervention was not considered in the first plan as her clinical status was stable, she had no sign of sepsis or peritonitis, and cleansing of her bowel has been performed precisely. The patient received conservative treatment because her clinical, laboratory and radiological findings showed no significant change.

In conclusion, colonoscopic perforation can be seen even though it is uncommon. In addition, intraperitoneal air, pneumomediastinum, pneumoretroperitoneum and subcutaneous emphysema as well may accompany perforation. Conservative approach should be kept in mind as a therapeutic option in the patients with no sign of peritoneal irritation.

## Ethics

Informed Consent: It was taken.

Peer-review: Internal peer-reviewed.

## Authorship Contributions

Surgical and Medical Practices: Durmuş Ali Çetin, Concept: Ebubekir Gündeş, Design: Durmuş Ali Çetin, Ulaş Aday, Data Collection or Processing: Hüseyin Çiyiltepe, Analysis or Interpretation: Erdal Polat, Kamuran Cumhuri Değer, Literature Search: Durmuş Ali Çetin, Writing: Durmuş Ali Çetin, Ebubekir Gündeş.

Conflict of Interest: No conflict of interest was declared by the authors.

Financial Disclosure: The authors declared that this study received no financial support.

## References

1. Anderson ML, Pasha TM, Leighton JA. Endoscopic perforation of the colon: lessons from a 10-year study. *Am J Gastroenterol* 2000;95:3418-3422.
2. Taku K, Sano Y, Fu KI, Saito Y, Matsuda T, Uraoka T, Yoshino T, Yamaguchi Y, Fujita M, Hattori S, Ishikawa T, Saito D, Fujii T, Kaneko E, Yoshida S. Iatrogenic perforation associated with therapeutic colonoscopy: a multicenter study in Japan. *J Gastroenterol Hepatol* 2007;22:1409-1414.
3. Lohsiriwat V. Colonoscopic perforation: Incidence, risk factors, management and outcome. *World J Gastroenterol* 2010;16:425-430.
4. Maunder RJ, Pierson DJ, Hudson LD. Subcutaneous and mediastinal emphysema. Pathophysiology, diagnosis, and management. *Arch Intern Med* 1984;144:1447-1453.
5. Marwan K, Farmer KC, Varley C, Chapple KS. Pneumothorax, pneumomediastinum, pneumoperitoneum, pneumoretroperitoneum and subcutaneous emphysema following diagnostic colonoscopy. *Ann R Coll Surg Engl* 2007;89:20-21.
6. Webb T. Pneumothorax and Pneumomediastinum During Colonoscopy. *Anaesth Intensive Care* 1998;26:302-304.