

## Osteoid Osteoma with Double Nidus

Mahmut N. AYTEKİN<sup>1</sup>, Mehmet A.E. AKSEKİLİ<sup>1</sup>, Hakan ATALAR<sup>2</sup>, Okan ATEŞ<sup>1</sup>, Kasım KILIÇARSLAN<sup>1</sup>, Mahmut UĞURLU<sup>1</sup>

<sup>1</sup>Department of Orthopedics and Traumatology, Yıldırım Beyazıt University Ankara Atatürk Training and Research Hospital, Ankara, Turkey.

<sup>2</sup>Department of Orthopedics and Traumatology, Medical Faculty, Gazi University, Ankara, Turkey.

Dear Editor,

Osteoid osteoma is a benign bone tumor composed of a central zone called nidus, which is an atypical bone completely enclosed within a well-vascularized stroma and a peripheral sclerotic reaction zone (1). Its etiology and pathogenesis are unknown (1).

This study reports the case of a 22-year-old male patient with dull pain below his right knee with osteoid osteoma, who was operated and his pains passed away. The pain increased at nights and was relieved by aspirin or nonsteroid anti-inflammatory drugs. No abnormal finding was noted during his physical examination and on his laboratory blood tests. Interestingly, this osteoid osteoma case presents double nidus. It is important to share this finding, as only few osteoid osteoma cases with double nidus have been reported in the literature (2,3).

His anteroposterior knee x-ray was normal, and the lateral view of knee x-ray showed a bone tumor on his proximal tibia (Figure 1). On further evaluation with CT scanning, a tumor that looks like osteoid osteoma was found (Figure 2).

Osteoid osteoma was diagnosed on the basis of his history and radiological evaluation. The nidus was taken out, and curettage was done. The allograft was inserted into the cavity after cauterization. The patient's pain resolved just after the operation. The pathological evaluation of the material was done to verify the diagnosis.

Osteoid osteoma is usually seen in the second or third decades of life, and approximately twice as many men as women are affected (4-6). The most common complaint of osteoid osteoma is pain, often described as being more severe at night. The pain is relieved after taking aspirin (4). The pain relief can be used for diagnosis. In the present case, an interesting osteoid osteoma was observed that showed double nidus on computerized tomography views. Careful and enough curettage should be done for the successful treatment of this disease.

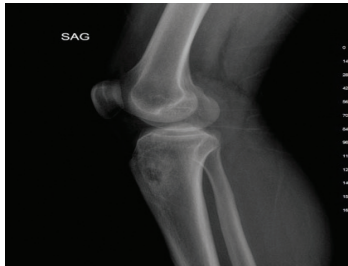

FIGURE 1: Preoperative lateral x-ray of the knee of the patient.

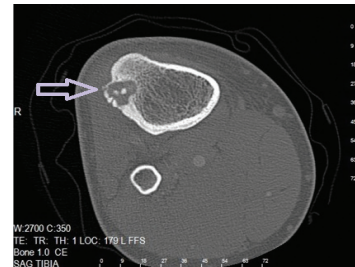


FIGURE 2: Preoperative CT scan of the tibia of the patient; arrow shows double nidus.

Correspondence:

Mahmut Nedim Aytekin

Yıldırım Beyazıt Üniversitesi, Ankara Atatürk Eğitim ve Araştırma Hastanesi, Ortopedi ve Travmatoloji Bölümü, Ankara, Türkiye.

e-mail: nedimaytekin@hotmail.com

## REFERENCES

1. Hashemi J, Gharahdaghi M, Ansaripour E, Jedi F, Hashemi S, Radiological features of osteoid osteoma: pictorial review, Iran J Radiol. 2011 8:182-9. doi: 10.5812/kmp.iranradiol.17351065.3392. Epub 2011 Nov 25.
2. Aynaci O, Turgutoglu O, Kerimoglu S, Aydin H, Cobanoglu U. Osteoid osteoma with a multicentric nidus: a case report and review of the literature. Arch Orthop Trauma Surg. 2007 Dec;127(10):863-6. Epub 2007 Sep 8.
3. Matera D, Campanacci DA, Caldora P, Mazza E, Capanna R, Osteoid osteoma of the femur with a double nidus: a case report, Chir Organi Mov. 2005 Jan-Mar;90(1):75-9. English, Italian.
4. Healey JH, Ghelman B. Osteoid Osteoma and Osteoblastoma: current concepts and recent advances. Clin Orthop. 1986;204:76-85.
5. Bender MS, McCormack RR, Glasser D, Weiland AJ. Osteoid Osteoma of the upper extremity. J Hand Surg. 1993;18A:1019-1025.
6. Wold LE, McLeod RA, Sim FH, Unni KK. Atlas of Orthopaedic pathology. Philadelphia: WE Saunders; 1990; pp 90-9.