

CASE REPORT

Hepatotoxicity After Desflurane Anesthesia

Ekrem Aslan¹, Can Gönen², Ayça Saltürk², Fatih Güzelbulut²

¹Department of Gastroenterology, Liv Hospital, Istanbul, Turkey

²Department of Gastroenterology, Haydarpaşa Numune Training and Research Hospital, Istanbul, Turkey

Abstract

Halogenated inhalational anesthetics, which have been used for the induction and maintenance of general anesthesia, can cause liver injury, ranging from temporary transaminase elevation to hepatic necrosis. It is rare but causes serious morbidity and mortality. Herein we present a case of severe transaminase elevation after using desflurane anesthesia for obesity surgery.

Keywords: Anesthesia; desflurane hepatitis; liver injury.

Inhalational anesthetics are the most commonly used agents for the induction and maintenance of general anesthesia [1]. Halothane, enflurane, isoflurane, desflurane, and sevoflurane are well-known inhalational anesthetics. Drug-induced liver injury, which may develop after using inhalational anesthetics, can range from asymptomatic transaminase elevations to fatal hepatic necrosis [2]. Hepatotoxicity after halothane inhalation is a common occurrence and has been extensively studied. However, fewer cases of hepatotoxicity have been reported for the newest agents such as desflurane and sevoflurane. Here, we present a case of severe transaminase elevations after desflurane anesthesia.

Case Report

A 47-year-old woman with a complaint of morbid obesity was admitted to our hospital for obesity surgery. She had a history of diabetes mellitus and depression and had a history of metformin and duloxetine administration. She was

surgery-naive and had no history of jaundice, blood transfusions, or alcohol use. She was immunized against hepatitis B. Preoperative laboratory study findings are summarized in Table 1. The patient underwent sleeve gastrectomy under general anesthesia using fentanyl, propofol, N₂O, and desflurane. The patient remained hemodynamically stable throughout the surgery and no blood products were administered. Twenty-four hours following surgery, the patient suffered from subfebrile fever and nausea and her laboratory test findings showed markedly elevated aminotransferase levels but no evidence of hyperbilirubinemia or coagulopathy. Clinical and laboratory parameters were monitored (Table 1). Her hepatitis and human immunodeficiency virus serology findings were negative for acute infection, and serology findings for hepatitis B surface antibody and hepatitis A immunoglobulin G were positive. Her Epstein barr virus and cytomegalovirus serology findings were negative. Antinuclear antibody and anti-smooth muscle antibody screens were also negative. Iron panel

Correspondence (İletişim): Ekrem Aslan, M.D. Liv Hastanesi, Gastroenteroloji Anabilim Dalı, Istanbul, Turkey

Phone (Telefon): +90 505 754 60 84 **E-mail (E-posta):** ekremaslan@yahoo.com

Submitted Date (Başvuru Tarihi): 21.03.2018 **Accepted Date (Kabul Tarihi):** 04.05.2018

Copyright 2018 Haydarpaşa Numune Medical Journal

This is an open access article under the CC BY-NC license (<http://creativecommons.org/licenses/by-nc/4.0/>).



Table 1. Preoperative and postoperative laboratory test results

| Value | Preoperative Day | Postoperative Day 1 | Postoperative Day 2 | Postoperative Day 3 | Postoperative Day 4 | Postoperative Day 5 | Postoperative Day 7 | Normal Range |
|--------------------------------------|------------------|---------------------|---------------------|---------------------|---------------------|---------------------|---------------------|---------------------------------|
| Aspartate aminotransferase (AST) | 18 | 2538 | 2466 | 863 | 651 | 152 | 48 | 10-42 IU/L |
| Alanine aminotransferase (ALT) | 16 | 1654 | 1648 | 412 | 237 | 35 | 20 | 10-60 IU/L |
| Alcaline phospatase (ALP) | 105 | 92 | 100 | 102 | 100 | 100 | 102 | 42-121 IU/L |
| Gama glutamyl transferase (GGT) | 17 | 28 | 24 | 20 | 19 | 18 | 19 | 10-30 IU/L |
| Total bilirubine | 0.33 | 0.42 | 0.43 | 0.48 | 0.59 | 0.7 | 0.41 | 0.2-01 mg/dL |
| Direct bilirubin | 016 | 0.17 | 0.17 | 0.33 | 0.32 | 0.31 | 0.21 | 0-0.31 mg/dL |
| Lactate dehydrogenase (LDH) | 200 | 2774 | 1046 | 528 | 427 | 240 | 205 | 14-280 IU/L |
| International normalized ratio (INR) | 1.1 | 1.2 | 1.17 | 1.12 | 1.12 | 1.14 | 1.01 | 0.8-1.2 |
| Whşte blood cells | 10.100 | 16.900 | 15.000 | 11.600 | 11.300 | 9.000 | 9.500 | 4.00-11.000 mm ³ |
| Platelet | 282.000 | 280.000 | 276.000 | 280.000 | 282.000 | 286.000 | 290.000 | 150.000-450.000 mm ³ |
| C reactive protein | 2 | 7.8 | 12.6 | 14.9 | 8.9 | 6 | 5 | 0-5 mg/L |
| Creatinine | 0.58 | 0.62 | 0.62 | 0.67 | 0.60 | 0.61 | 0.59 | 0.06-1.2 mg/dL |

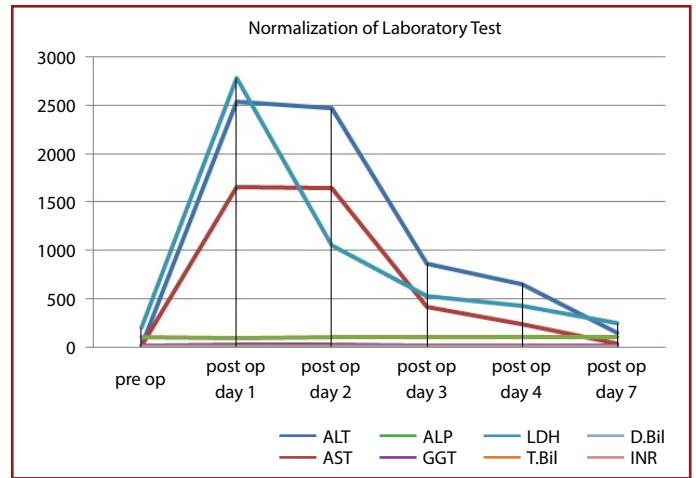


Figure 1. Normalization of laboratory findings.

findings were in the normal range. Other serological values included the following: ceruloplasmin, 30 mg/dl (normal, 18–36 mg/dl) and serum copper 87 mg/dl (normal, 70–155 mg/dl). Her electrolyte values were within the normal range and she had no clinical or laboratory signs of sepsis. An ultrasound of the liver and gallbladder was unremarkable and there was no evidence of ascites. The decision was made to continue conservative management. There was gradual clinical improvement and her laboratory values completely normalized seven days following the surgery as seen in Figure 1.

Discussion

For more than 50 years, halogenated inhalational anesthetics have been used for general anesthesia and their use is reportedly associated with liver injury [1]. Risk factors include obesity, female sex, middle age, and multiple anesthetics over a short period of time [4]. Obesity, female sex, and middle age were present in our patient as risk factors.

In approximately 20% of patients who were repeatedly administered halothane anesthesia, a mild hepatitis with low-grade fever, nausea, and a mild transient elevation of liver enzymes was observed. In contrast, a fulminant hepatitis occurred in 1 in 20.000 patients exposed to halothane and was characterized by jaundice, hepatomegaly, hepatic encephalopathy, and markedly increased liver enzymes [5]. However, halothane is no longer used in many developed countries as in our country. Fortunately, fewer cases of hepatotoxicity have been reported for the newest agents [6]. Most hypotheses on the mechanism of halogenated anesthetics induced hepatic injury are based on the production of metabolites causing immunoallergic reaction in patients [7]. Enflurane, isoflurane, and desflurane metabolized and produced hepatotoxic proteins, containing trifluoroacety-

lated (TFA) components, some of which may be immunogenic [3]. In contrast with other halogenated anesthetics, sevoflurane metabolism did not result in the formation of TFA, suggesting that evoflurane has a low hepatotoxic potential [1]. Nevertheless, autoantigen-specific IgG4 antibodies have reportedly been associated with hepatotoxicity [8]. The occurrence of hepatic injury following desflurane anesthesia was once believed to be rare. However, reports of complications associated with the use of this anesthetic continue to be accumulated. Generally, treatment of hepatotoxicity and hepatitis caused by halogenated anesthetics are supportive care and medical follow up [9]. In addition, some case reports show the benefit of glucocorticoids in the literature [10]. In the setting of acute liver failure, the case fatality rate can be as high as 80% in those who develop hepatic encephalopathy. Severe, progressive cases may require emergent liver transplantation. Fortunately, in our patient, with close laboratory monitoring and supportive care completely normalized laboratory parameters and clinical improvement within one week were observed.

Even though anesthesia-induced liver injury is not a common occurrence, we should be aware of the association of the disease with the use of halogenated anesthetics.

Informed Consent: Approval was obtained from the patients.

Peer-review: Externally peer-reviewed.

Conflict of Interest: None declared.

Authorship Contributions: Concept: E.A.; Design: A.S.; Data Collection or Processing: C.G.; Analysis or Interpretation: F.G.; Literature Search: E.A., Writing: E.A.

Financial Disclosure: The authors declared that this study received no financial support.

References

1. Safari S, Motavaf M, Seyed Siamdoust SA, Alavian SM. Hepatotoxicity of halogenated inhalational anesthetics. *Iran Red Crescent Med J* 2014;16:e20153. [CrossRef]
2. Lin J, Moore D, Hockey B, Di Lernia R, Gorelik A, Liew D, et al. Drug-induced hepatotoxicity: incidence of abnormal liver function tests consistent with volatile anaesthetic hepatitis in trauma patients. *Liver Int* 2014;34:576–82. [CrossRef]
3. Singhal S, Gray T, Guzman G, Verma A, Anand K. Sevoflurane hepatotoxicity: a case report of sevoflurane hepatic necrosis and review of the literature. *Am J Ther* 2010;17:219–22. [CrossRef]
4. Eghtesadi-Araghi P, Sohrabpour A, Vahedi H, Saberi-Firoozi M. Halothane hepatitis in Iran: a review of 59 cases. *World J Gastroenterol*. 2008 Sep 14;14:5322–6. [CrossRef]
5. Walton B, Simpson BR, Strunin L, Doniach D, Perrin J, Appleyard AJ. Unexplained hepatitis following halothane. *Br Med J* 1976;1:1171–6. [CrossRef]
6. Tung D, Yoshida EM, Wang CS, Steinbrecher UP. Severe desflurane hepatotoxicity after colon surgery in an elderly patient. *Can J Anaesth* 2005;52:133–6. [CrossRef]
7. Habibollahi P, Mahboobi N, Esmaeili S, Safari S, Dabbagh A, Alavian SM. Halothane-induced hepatitis: A forgotten issue in developing countries: Halothane-induced hepatitis. *Hepat Mon* 2011;11:3–6.
8. Anderson JS, Rose NR, Martin JL, Eger EI, Njoku DB. Desflurane hepatitis associated with hapten and autoantigen-specific IgG4 antibodies. *Anesth Analg* 2007;104:1452–3. [CrossRef]
9. Lo SK, Wendon J, Mieli-Vergani G, Williams R. Halothane-induced acute liver failure: continuing occurrence and use of liver transplantation. *Eur J Gastroenterol Hepatol* 1998;10:635–9.
10. Moore DH, Benson GD. Prolonged halothane hepatitis. Prompt resolution of severe lesion with corticosteroid therapy. *Dig Dis Sci* 1986;31:1269–72. [CrossRef]