

Is the Sulfonamide Group of Tamsulosin the Main Factor in the Pathophysiology of Floppy Iris Syndrome?

 Ahmet Ürkmez¹,  Özgür Haki Yüksel²

¹Department of Urology, Health Science University, Haydarpaşa Numune Training and Research Hospital, Istanbul, Turkey

²Department of Urology, Health Science University, Fatih Sultan Mehmet Training and Research Hospital, Istanbul, Turkey

Abstract

Intraoperative floppy iris syndrome (IFIS) was first described by Chang et al. in 2005 in using α -blockers. Tamsulosin a selective α -1(a) adrenergic receptor (AR) antagonist is a commonly prescribed drug for benign hyperplasia of the prostate (BPH), and it has been shown to have the strongest association with IFIS. Other drugs that predispose to IFIS include alfuzosin, doxazosin, terazosin, finasteride, labetalol, mianserin, chlorpromazine, donepezil and other antipsychotic agents. In literature reviews, the pathophysiological evaluation of IFIS has not yielded clear results. In the present study, we examined this pathophysiological mechanism from a different perspective and somewhat hypothetically analyzed the chemical composition of these drugs. We analyzed their chemical formulas and pharmacological effects in combination. We compared tamsulosin with other IFIS-inducing α -blockers and propose that its sulfonamide group might be a causative factor.

Keywords: Chemical formulas; floppy iris syndrome; sulfonamide bond; tamsulosin.

Intraoperative floppy iris syndrome (IFIS) was first described by Chang et al.^[1] in 2005 using α -blockers. According to this first description, IFIS has three clinical criteria: (a) floppy iris stromal fluctuating with fluid flow, (b) tendency of iris tissue to prolapse from the wound site, and (c) progressive intraoperative papilla narrowing. IFIS can only be diagnosed intra-operatively, and it is associated with serious complications adversely affecting prognosis^[2].

Tamsulosin a selective α -1(a) adrenergic receptor (AR) antagonist is a commonly prescribed drug for benign hyperplasia of prostate (BPH), and it has been shown to have the strongest association with IFIS. Patients using alfuzosin another α -blocker showed a lesser risk of IFIS development compared with those using tamsulosin^[3]. Other drugs that

predispose to IFIS include doxazosin, terazosin, finasteride, labetalol, mianserin, chlorpromazine, donepezil, and other antipsychotic agents^[4-11]. Systemic factors that have been implicated for predisposition to IFIS include diabetes and hypertension^[12]. Saw palmetto (*Serenoa repens*), a widely used alternative therapy for BPH, was also associated with IFIS in a few patients^[13]. In this article, we compared tamsulosin with other IFIS-inducing α -blockers and propose that its sulfonamide group might be a causative factor.

Material and Methods

In literature reviews, the pathophysiological evaluation of IFIS has not yielded clear results. Most of the studies performed have been tamsulosin-based comparative studies or

Correspondence (İletişim): Ahmet Ürkmez, M.D. Department of Urology, Health Science University, Haydarpaşa Numune Training and Research Hospital, Istanbul, Turkey

Phone (Telefon): +90 507 766 83 00 **E-mail (E-posta):** ahmeturkmez@hotmail.com

Submitted Date (Başvuru Tarihi): 21.02.2018 **Accepted Date (Kabul Tarihi):** 04.05.2018

Copyright 2018 Haydarpaşa Numune Medical Journal

This is an open access article under the CC BY-NC license (<http://creativecommons.org/licenses/by-nc/4.0/>).



case reports. In the present study, we examined this pathophysiological mechanism from a different perspective and somewhat hypothetically analyzed the chemical composition of these drugs. We analyzed their chemical formulas (Fig. 1) and pharmacological effects in combination (Table 1).

Results

Terazosin, doxazosin, and alfuzosin are quinazoline derivatives, while tamsulosin is a derivative of methoxybenzene sulfonamide. This structure of tamsulosin is different from non-selective quinazoline derivative α -blockers. When we examined the pathophysiology of association between IFIS and tamsulosin, despite the lack of sufficient amount of evidence, the following mechanisms can be suggested: (a) prolonged stay of tamsulosin in anterior chamber and its irreversible affinity to iris smooth muscle ARs in experimental animal trials and its induction of muscle atrophy; (b) stronger α -1 receptor affinity of tamsulosin compared with that of

other α -blockers and its activities potentially mediated via an α 1L receptor, and (c) affinity of tamsulosin for non-ARs in iris. The interaction in the binding of tamsulosin to α -1 AR subtypes using molecular modelling was reported by Ishiguro et al., [14] 2002; According to this report, the functional groups of tamsulosin, i.e., ethylamine nitrogen, sulphonamide nitrogen and methoxy oxygen of the benzene ring may interact with α -1A, α -1B, and α -1D ARs. Sulphonamide nitrogen of tamsulosin interacts with α -1D AR. This is probably due to the more acidic nature of sulphonamide and the long bond lengths of the C-S and S-N bonds, which would enable the sulphonamide to bind α -1D AR.

Here, we observed that the chemical formula of tamsulosin was different from that of other α -blockers. When we further extrapolated this observation, we detected a sulfonamide group in acetazolamide, which is used in open-angle glaucoma and demonstrates its effects by decreasing the amount of humor aqueous with resultant vasodilator

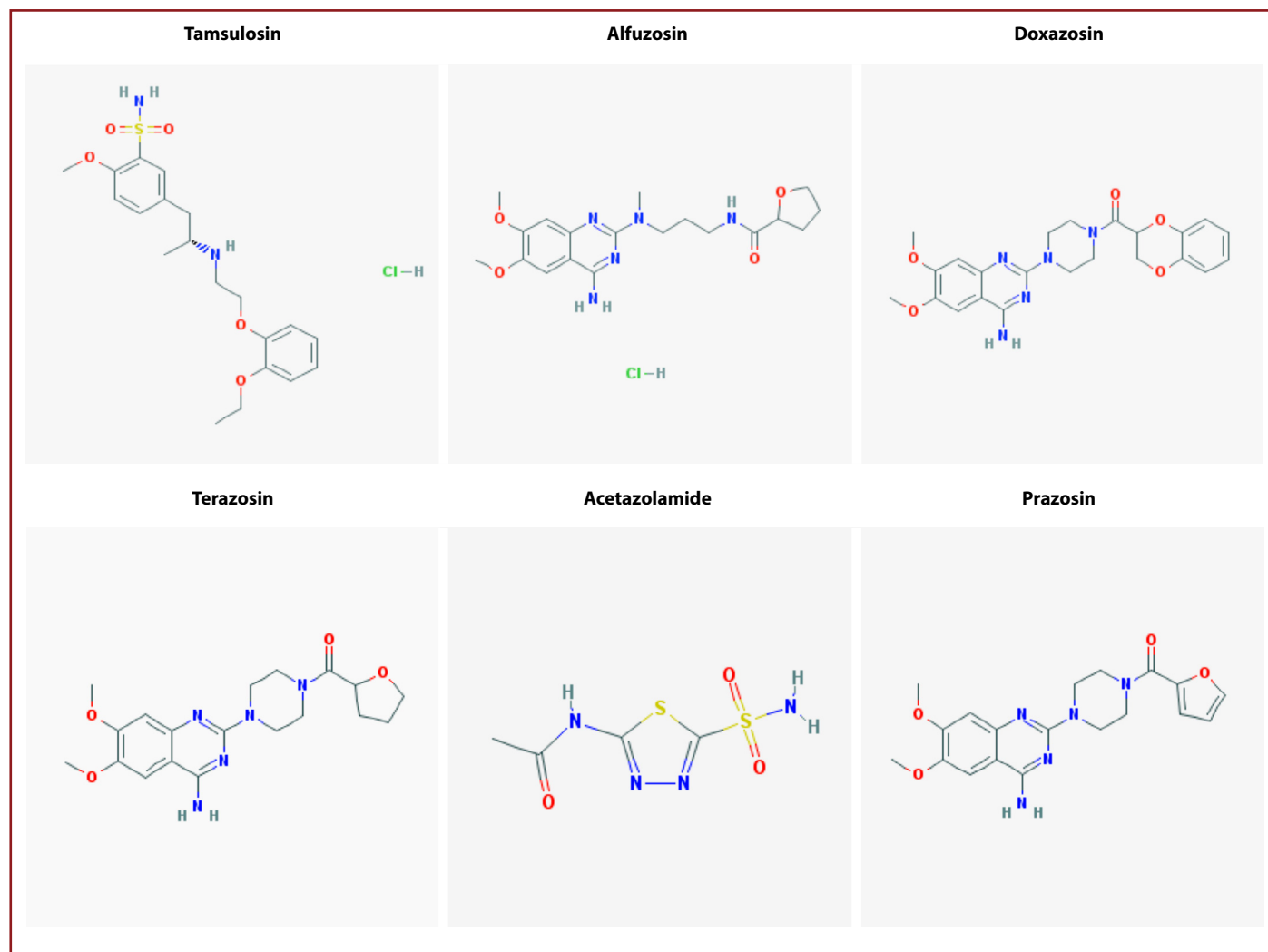


Figure 1. Chemical formulas of tamsulosin, alfuzosin, doxazosin, terazosin, prazosin, and acetazolamide.

Table 1. Comparative analysis of the mechanisms and effects of tamsulosin, other adrenergic receptor and acetazolamide antagonists

Generic name of the drug	Chemical formula	Receptor subtype	Their functions and effects
Tamsulosin	C₂₀H₂₈N₂O₅S (SULFONAMIDE)	Tamsulosin is an irreversible antagonist to norepinephrine in human isolated prostate and the iris dilator muscle in an animal study α 1A + α 1D and α 1L NA receptors dopaminergic (D) receptors	Greater affinity for α 1A + α 1D receptors than other α 1 blockers α 1L receptor might mediate iris dilatation tamsulosin is more potent antagonist of 1L receptor
Terazosin	C₁₉H₂₅N₅O₄	Non-selective competitive receptor subtype - α 1A, α 1B and α 1D receptors	No selectivity toward α 1A receptor which is thought to predominate in iris α 1A + α 1D – uroselective α 1B – vascular epithelium
Alfuzosin	C₁₉H₂₇N₅O₄	Competitive antagonist balanced binding affinity for the α 1 receptor subtypes	The effect of alfuzosin on iris smooth muscle has not been studied, but it has a similar structure to prazosin might mean that alfuzosin also behaves as a competitive antagonist in iris smooth muscle. Similar uroselectivity to tamsulosin
Doxazosin	C₂₃H₂₅N₅O₅	Competitive non-selective antagonist	α 1A – uroselective α 1B – vascular epithelium
Prazosin	C₁₉H₂₁N₅O₄	Competitive antagonist	Prazosin is a competitive antagonist in iris dilator smooth muscle. α 1A – uroselective α 1B – vascular epithelium
Naftopidil	C₂₄H₂₈N₂O₃	Selective α 1-adrenergic receptor antagonist	Decreases production of humor aqueous and increases
Acetazolamide	C₄H₆N₄O₃S₂ (SULFONAMIDE)	Carbonic anhydrase inhibitor	hemorrhagic congestion in eye tissue

effects on eyes.

Discussion

IFIS, a recently defined syndrome characterized by small pupil, should be considered in cases of inadequate pupillary dilatation before surgery as well as cases of intraoperative progressive myosis. Even though IFIS has been reported in 0.6%–2.0% of the population in general, its incidence has been reported to be 57%–100 % among the male population undergoing tamsulosin therapy [3].

Although the precise mechanism through which tamsulosin can lead to IFIS remains unknown, Chang et al. [1] have suggested that tamsulosin has a high affinity and specificity for α -1A AR, which is thought to be the dominant receptor in the IRIS. They have discussed data pertaining to a retrospective and another prospective study, which support an association between tamsulosin and IFIS. In the retrospective arm of the study on IFIS, 16 of the 511 patients were using tamsulosin, and 10 of these 16 patients (63%)

had IFIS, whereas none of the 11 patients using α -1 antagonists other than tamsulosin had IFIS. In the prospective arm of the same study performed on 741 patients, IFIS was observed in 16 patients (2.2%), and 15 of these 16 patients (94%) were either currently using tamsulosin or had used tamsulosin for some time [1]. Chang et al. [15] noted that IFIS was not observed in patients using tamsulosin for less than 4–6 months, and in the surgical population with IFIS, sphincterotomy and mechanical pupillary dilatation maneuvers performed to provide proper pupillary dilatation were ineffective. In another study including 332 patients, 64 patients were either still using tamsulosin or alfuzosin or had previously used and discontinued it. IFIS was seen in 19 out of 22 patients (86.4%) using tamsulosin on an average of 38 months, and at the same time, IFIS was observed in only 2 out of 13 patients (15.4%) using alfuzosin for 20 months on an average. In 5 patients using tamsulosin, although the drug was stopped 2 months before surgery, as recommended by an ophthalmologist, IFIS was observed

in all patients [3]. Nonetheless, in the literature, IFIS was observed in a patient who did not use any other α -1 antagonist after the discontinuation of his tamsulosin therapy 3 years before surgery [16]. Therefore, tamsulosin is thought to exert irreversible effects on iris muscles. Although IFIS was encountered in patients who discontinued tamsulosin 1 year before surgery, many eye centers of UK discontinue tamsulosin use at least 2 weeks before cataract surgery and suggest the reinstatement of tamsulosin therapy immediately after surgery [17]. In another study, despite the discontinuation of tamsulosin use 7–28 days before surgery, floppy iris tissue was detected in these patients [18]. Therefore, a consensus has not been reached on the timing of the cessation of tamsulosin use. Animal studies have demonstrated 24-times stronger α -1 affinity of tamsulosin to α -1A relative to α -1B [19]. Besides, it has been observed that tamsulosin remains relatively longer in the anterior chamber, and during its half-life of 48–72 hours, it induces relatively permanent blockade with resultant atrophy of iris dilator smooth muscle [1]. This phenomenon explains floppy iris syndrome observed after the cessation of the drug. However, tamsulosin users should cease using this drug as early as possible before cataract surgery. Precise information about the duration of its use is lacking. Taben et al. [20] have reported a case of IFIS after 1 day of tamsulosin (1 dose) therapy, indicating that α -1 blockade alone without disuse atrophy could be enough to cause IFIS. Shah et al. [21] have also published a case of IFIS occurring only 2 days after tamsulosin was initiated.

The most comprehensive review of ARs in relation to the potential pathophysiology of IFIS was recently published [22]. The α -1 receptor subgroups of dilator smooth muscles of the human iris had not been determined yet [1]. However, detailed findings have demonstrated their resemblance to those of rabbits. In some studies performed in rabbits, a dominance of α -1 ARs and especially α -1A subtype in dilator muscles of iris has been detected [23, 24]. However, in another study performed on rabbits, the presence of α -1A (60%) and α -1B (40%) subtypes was demonstrated [25]. There are 3 subtypes of α -1 ARs α 1A, α 1B, and α 1D all of which have been cloned and characterized [26]. A fourth subtype α 1L AR has been pharmacologically defined but not fully characterized or cloned yet. Tiwari et al. [27] have also proposed an important role of the α 1L subtype receptor in the mediation of iris dilatation in the human eye, and tamsulosin was considered to be a more potent antagonist of this receptor subtype rather than terazosin or doxazosin. As the exact mechanism by which tamsulosin induces IFIS is yet to be established, the role of other non-ARs (i.e.,

dopaminergic and serotonergic receptors) in inducing pupillary changes warrants consideration [28–31]. Tamsulosin seems to have a potent affinity with dopaminergic receptors as well [32]. Tamsulosin is a chiral molecule. An animal study has shown one form to be 140 times more potent in the prostate than the other [33]. The more potent form is an irreversible antagonist of norepinephrine in human isolated prostate [34] and the iris dilator muscle as shown in an experimental animal study [35]. However, in another study, it has been advocated that the blocking effect of tamsulosin on the α -1 receptors on iris tissue can be prevented by binding these receptors with the natural agonist epinephrine. For this purpose, epinephrine was administered to the anterior chamber, and it was observed that iris dilator muscle tonus and iris rigidity increased thereafter [36]. Structural differences and well-defined mechanisms of action of AR antagonists might account for substantial differences in cases of IFIS. Alfuzosin has been reported to show selectivity only for the α 1A subtype [37], and act as a pure competitive antagonist in human prostatic smooth muscle [38], as do terazosin [34] and prazosin [39]. Similar to prazosin [40], alfuzosin behaves as a competitive antagonist in human iris smooth muscle. Settas et al. [41] have suggested that the overall affinity of α 1 AR antagonists toward α 1A receptors might explain IFIS. Figure 1 compares the mechanisms and effects of tamsulosin and other AR antagonists. In addition, Schwinn et al. [12] have proposed that IFIS might be associated with various diseases and medications. They have stated that in animal studies, nitric oxide has been shown to relax iris sphincter and dilator smooth muscle. Daily use of a nitroglycerin patch could be another potential cause of IFIS. However, there are no clinical cases or human studies showing an association of nitrates and IFIS. The α -1 AR-mediated iris dilator smooth muscle contraction occurs due to α 1A ARs, whereas iris arteriolar contraction occurs due to α 1B ARs. After reviewing IFIS, strengths/weaknesses of supporting data, and iris biology, a case is made that rather than being drug-specific (α 1AR antagonists), IFIS may represent the “tip of the iceberg.” Relaxed iris dilator muscle resistant to adrenergic agonists should be expected to develop by the use of drugs with mydriatic activity (e.g., antagonists at α 1AR, endothelin-A, angiotensin receptors, and nitric oxide donors such as nitrates) and/or diseases associated with endothelial dysregulation (e.g., congestive heart failure, diabetes, and hypertension). Rather than a rare, unexpected, unpredictable syndrome due to one drug, a careful medical history should elucidate predisposing factors of IFIS. Just as anticoagulants are discontinued prior to elective surgery, in consultation with the patient's primary physician, dis-

continuation of drugs with mydriatic activity used in the conservative management of elderly patients should be considered prior to cataract surgery [12]. Some researchers have suggested that iris contraction and relaxation is the result of a balance of competing for neural pathways and pathways regulated by prostaglandin and nitric oxide [42, 43]. Carbonic anhydrases (CAs) constitute a group of enzymes with a physiological importance, which are widely distributed in the body. It has been demonstrated that CA has 14 iso-enzymes. In humans, type I, II, and IV were detected in the eye. Types 1 and II are localized in cell cytoplasm, while type IV is bound to cell membranes. None of the currently used clinical drugs exhibit selectivity for a specific CA isoform. In a study to design selective sulfonamides, two complementary approaches have been proposed: "ring" and "tail" [44]. It is clear that balanced hydro- and liposolubility is required for optimum in vivo activity since therapeutically useful anti-glaucoma medications are aromatic and heterocyclic sulfonamides. One of the conditions necessary for a sulfonamide to act as an effective intraocular pressure reducing agent is the presence of moderate lipid solubility [45]. Acetazolamide is a potent carbonic anhydrase inhibitor. Acetazolamide is not a mercury-based diuretic. It is a non-bacteriostatic sulfonamide with a chemical structure and pharmacological effectiveness quite different from bacteriostatic sulfonamides. CAs are believed to cause vasodilation by increasing intracytoplasmic CO₂ levels. A 37% increase in retinal blood flow has been demonstrated by the systemic use of acetazolamide [46].

Conclusion

Sulfonamide group is a component present in the structure of acetazolamide, which exerts vasodilatory effects on relaxation of the vascular smooth muscle of the eye, and tamsulosin, which relaxes the urethral smooth muscle in BPH treatment. In addition, although this study cannot make a definitive decision, our findings suggest that sulfonamide group in tamsulosin may explain the specific pathophysiology of IFIS. However, we believe that there is a need for more extensive studies on this topic. Clarification of this issue from a pharmacokinetic perspective can conceivably decrease this peculiar and prevalent side effect of this drug, which imposes challenging difficulties to ophthalmologists.

Peer-review: Externally peer-reviewed.

Authorship Contributions: Concept: A.U., O.H.Y.; Design: A.U., O.H.Y.; Data Collection or Processing: A.U., O.H.Y.; Analysis or Interpretation: A.U., O.H.Y.; Literature Search: A.U., O.H.Y.; Writing: A.U., O.H.Y.

Conflict of Interest: None declared.

Financial Disclosure: The authors declared that this study received no financial support.

References

1. Chang DF, Campbell JR. Intraoperative floppy iris syndrome associated with tamsulosin. *J Cataract Refract Surg* 2005;31:664–73.
2. Nguyen DQ, Sebastian RT, Kyle G. Surgeon's experiences of the intraoperative floppy iris syndrome in the United Kingdom. *Eye (Lond)* 2007;21:443–4.
3. Blouin MC, Blouin J, Perreault S, Lapointe A, Dragomir A. Intraoperative floppy-iris syndrome associated with alpha1-adrenoreceptors: comparison of tamsulosin and alfuzosin. *J Cataract Refract Surg* 2007;33:1227–34.
4. Dhingra N, Rajkumar KN, Kumar V. Intraoperative floppy iris syndrome with doxazosin. *Eye (Lond)* 2007; 21:678–9.
5. Venkatesh R, Veena K, Gupta S, Ravindran RD. Intraoperative floppy iris syndrome associated with terazosin. *Indian J Ophthalmol* 2007;55:395–6.
6. Issa SA, Dagres E. Intraoperative floppy-iris syndrome and finasteride intake. *J Cataract Refract Surg* 2007;33:2142–3.
7. Calotti F, Steen D. Labetalol causing intraoperative floppy-iris syndrome. *J Cataract Refract Surg* 2007;33:170–1.
8. Ugarte M, Leong T, Rassam S, Kon CH. Intraoperative floppy-iris syndrome, alpha1-adrenergic antagonists, and chronic intake of mianserin: Is there an association? *J Cataract Refract Surg* 2007;33:170.
9. Unal M, Yücel I, Tenlik A. Intraoperative floppy-iris syndrome associated with chronic use of chlorpromazine. *Eye (Lond)* 2007;21:1241–2.
10. Papadopoulos R, Bachariou A. Intraoperative floppy-iris syndrome associated with chronic intake of donepezil. *J Cataract Refract Surg* 2007;33:1997–8.
11. Pringle E, Packard R. Antipsychotic agent as an etiologic agent of IFIS. *J Cataract Refract Surg* 2005;31:2240–1.
12. Schwinn DA, Afshari NA. alpha(1)-Adrenergic receptor antagonists and the iris: new mechanistic insights into floppy iris syndrome. *Surv Ophthalmol* 2006;51:501–12.
13. Yeu E, Grostern R. Saw palmetto and intraoperative floppy-iris syndrome. *J Cataract Refract Surg* 2007;33:927–8.
14. Ishiguro M, Futabayashi Y, Ohnuki T, Ahmed M, Muramatsu I, Nagatomo T. Identification of binding sites of prazosin, tamsulosin and KMD-3213 with alpha(1)-adrenergic receptor subtypes by molecular modeling. *Life Sci* 2002;71:2531–41.
15. Chang DF. The Intraoperative floppy iris syndrome, Cover Story. *Cataract and Refractive Surg Today* 2005;4:64–8.
16. Osher RH. Association between IFIS and Flomax. *J Cataract Refract Surg* 2006;32:547.
17. Brogden PR, Backhouse OC, Saldana M. Intraoperative floppy iris syndrome associated with tamsulosin. *Can Fam Physician* 2007;53:1148.
18. Pärssinen O, Leppänen E, Keski-Rahkonen P, Mauriala T, Dugué B, Lehtonen M. Influence of tamsulosin on the iris and

- its implications for cataract surgery. *Invest Ophthalmol Vis Sci* 2006;47:3766–71.
19. Chadha V, Borooah S, Tey A, Styles C, Singh J. Floppy iris behaviour during cataract surgery: associations and variations. *Br J Ophthalmol* 2007;91:40–2.
 20. Taben R, Thakuria P, Jones M, Lohman LE: Intraoperative floppy-iris syndrome after one day of tamsulosin therapy. Available at: http://stream.expoplanner.com/ascrs2007/powerpoints/000092_IFIS_Case_ASCRS_Presentation.ppt.
 21. Shah N, Tendulkar M, Brown R. Should we anticipate intraoperative floppy iris syndrome (IFIS) even with very short history of tamsulosin? *Eye (Lond)* 2009;23:740.
 22. Srinivasan S, Radomski S, Chung J, Plazker T, Singer S, Slo-movic AR. Intraoperative floppy-iris syndrome during cataract surgery in men using alpha-blockers for benign prostatic hypertrophy. *J Cataract Refract Surg* 2007;33:1826–7.
 23. Nakamura S, Taniguchi T, Suzuki F, Akagi Y, Muramatsu I. Evaluation of alpha1-adrenoceptors in the rabbit iris: pharmacological characterization and expression of mRNA. *Br J Pharmacol* 1999;12:1367–74.
 24. Suzuki F, Taniguchi T, Nakamura S, Akagi Y, Kubota C, Satoh M, et al. Distribution of alpha-1 adrenoceptor subtypes in RNA and protein in rabbit eyes. *Br J Pharmacol* 2002;135:600–8.
 25. Wikberg-Matsson A, Uhlén S, Wikberg JE. Characterization of alpha(1)-adrenoceptor subtypes in the eye. *Exp Eye Res* 2000;70:51–60.
 26. Hieble JP, Bylund DB, Clarke DE, Eikenburg DC, Langer SZ, Lefkowitz RJ, et al. International Union of Pharmacology. X. Recommendation for nomenclature of alpha 1-adrenoceptors: consensus update. *Pharmacol Rev* 1995;47:267–70.
 27. Tiwari A. Tamsulosin and floppy iris syndrome in benign prostatic hyperplasia patients. *Expert Opin Investig Drugs*. 2006; 15:443–446.
 28. Fanciullacci M, Sicuteri R, Alessandri M, Geppetti P. Buspirone, but not sumatriptan, induces miosis in humans: relevance for a serotonergic pupil control. *Clin Pharmacol Ther* 1995;57:349–55.
 29. Pringle E, Packard R. Antipsychotic agent as an etiologic agent of IFIS. *J Cataract Refract Surg* 2005;31:2240–1.
 30. Giuliano F. Impact of medical treatments for benign prostatic hyperplasia on sexual function. *BJU Int* 2006;97 Suppl 2:34–8.
 31. Clément P, Bernabé J, Kia HK, Alexandre L, Giuliano F. D2-like receptors mediate the expulsion phase of ejaculation elicited by 8-hydroxy-2-(di-N-propylamino)tetralin in rats. *J Pharmacol Exp Ther* 2006;316:830–4.
 32. Leonardi A, Hieble JP, Guarneri L, Naselsky DP, Poggesi E, Sironi G, et al. Pharmacological characterization of the uroselective alpha-1 antagonist Rec 15/2739 (SB 216469): role of the alpha-1L adrenoceptor in tissue selectivity, part I. *J Pharmacol Exp Ther* 1997;281:1272–83.
 33. Honda K, Nakagawa C. Alpha-1 adrenoceptor antagonist effects of the optical isomers of YM-12617 in rabbit lower urinary tract and prostate. *Journal of Pharmacology and Experimental Therapeutics* 1986;239:512–6.
 34. Muramatsu I, Taniguchi T, Okada K. Tamsulosin: alpha1-adrenoceptor subtype-selectivity and comparison with terazosin. *Jpn J Pharmacol* 1998;78:331–5.
 35. Takayanagi I, Konno F, Kameda H, Kubo H, Furukawa A, Toyoda T. A difference in mode of antagonism between optical isomers of a potent selective alpha 1-adrenoceptor blocker (YM-12617) and norepinephrine in isolated rabbit iris dilator and aorta. *Jpn J Pharmacol* 1986;42:579–82.
 36. Shugar JK. Use of epinephrine for IFIS prophylaxis. *J Cataract Refract Surg* 2006;32:1074–5.
 37. Martin DJ, Angel I, Arbilla S. Functional uroselectivity. *Eur Urol* 1998;33:12–8.
 38. Palea S, Barras M, Deplanne V, Vallancien G. Antagonistic effects of alfuzosin on concentration-response curves to phenylephrine and noradrenaline in human prostatic adenoma. *Neurourol Urodyn* 2000;19:431–3.
 39. Teng CM, Guh JH, Ko FN. Functional identification of alpha 1-adrenoceptor subtypes in human prostate: comparison with those in rat vas deferens and spleen. *Eur J Pharmacol* 1994;265:61–6.
 40. Ishikawa H, Miller DD, Patil PN. Comparison of post-junctional alpha-adrenoceptors in iris dilator muscle of humans, and albino and pigmented rabbits. *Naunyn Schmiedebergs Arch Pharmacol* 1996;354:765–72.
 41. Settas G, Fitt AW. Intraoperative floppy iris syndrome in a patient taking alfuzosin for benign prostatic hypertrophy. *Eye (Lond)* 2006;20:1431–2.
 42. Chuman T, Chuman H, Nao-i N, Sawada A, Yamamoto R, Wada A. Nitric oxide-sensitive and -insensitive contractions of the isolated rabbit iris sphincter muscle. *Invest Ophthalmol Vis Sci* 1996;3:1437–43.
 43. Pianka P, Oron Y, Lazar M, Geyer O. Nonadrenergic, noncholinergic relaxation of bovine iris sphincter: role of endogenous nitric oxide. *Invest Ophthalmol Vis Sci* 2000;41:880–6.
 44. Yorulmaz N, Oltulu O, Eroğlu E. Development of selective QSAR models and molecular docking study for inhibitory activity of sulfonamide derivatives against carbonic anhydrase isoforms II and IX. *Journal of Molecular Structure* 2018;1163:270–9.
 45. Remko M. Molecular structure, pKa, lipophilicity, solubility and absorption of biologically active aromatic and heterocyclic sulfonamides. *Journal of Molecular Structure THEOCHEM* 2010;944:34–42.
 46. Rassam SM, Patel V, Kohner EM. The effect of acetazolamide on the retinal circulation. *Eye (Lond)* 1993;7:697–702.