

Performing 180-Watt GreenLight® Laser Prostatectomy using Periprostatic Block

Ömer Onur Çakır¹, Mehmet Gökhan Çulha², Hüseyin Lüleci³, Ahmet Yaser Müslümanoğlu¹

¹Department of Urology, University of Health Sciences, Bağcılar Training and Research Hospital, Istanbul, Turkey

²Department of Urology, University of Health Sciences, Okmeydanı Training and Research Hospital, Istanbul, Turkey

³Department of Urology, Istanbul Medistate Hospital, Istanbul, Turkey

Abstract

Introduction: GreenLight® photoselective vaporization of the prostate (PVP) is an effective minimally invasive surgical treatment for lower urinary tract symptoms suggestive of benign prostatic hyperplasia (BPH/LUTS). This study aimed to assess the feasibility of using local anesthesia during the 180-Watt GreenLight® PVP procedure in patients who are unsuitable for general or regional anesthesia.

Methods: The study involved 52 patients who underwent PVP using the 180-Watt GreenLight® system at our institution under periprostatic block between December 2013 and August 2015. All patients completed International Prostate Symptom Score (IPSS) and underwent uroflowmetric evaluation to determine maximum flow rate (Q_{max}). Post-void residual urine and prostate volumes were measured by transpubic and transrectal ultrasonography, respectively. Before the operation, 20 ml of bupivacaine hydrochloride (5 mg/ml) was injected into the prostate capsule through the perineum using a 22 G Spinocan® needle under the guidance of an index finger inserted into the rectum. Following the procedure, each patient was assessed for pain using the visual analog scale (VAS), and all patients were followed up 3 months after surgery.

Results: Mean patient age was 74.88±7.16 years. All operations were successfully completed without the need to convert to general anesthesia. PVP resulted in a significant improvement in IPSS (28.6±3.83 vs. 10.73±2.62, p<0.0001) and Q_{max} (6.88±1.1 vs. 23.87±2.8, p<0.0001). Mean operative time, indwelling catheter duration, and length of hospital stay were 57.13±15.32 min, 1.25±0.44 days, and 1.37±0.56 days, respectively. No severe perioperative complications were recorded. The majority of patients did not exhibit any evidence of pain during the procedure (46 of 52 patients had a VAS of 0), and the mean VAS score was 0.40±1.27.

Discussion and Conclusion: Periprostatic block appears to be a feasible and safe alternative to general or regional anesthesia during PVP using a 180-Watt GreenLight® system. This type of anesthesia may be preferred for use in elderly patients with BPH/LUTS who cannot tolerate general and/or regional anesthesia due to comorbidities.

Keywords: Benign prostate hyperplasia; GreenLight laser; periprostatic block; local anesthesia.

Since its introduction in 1932^[1], transurethral resection of prostate (TUR-P) has been the gold standard treatment for lower urinary tract symptoms suggestive of benign prostatic hyperplasia (BPH/LUTS). However, recent advances in minimally invasive prostatic procedures resulted

in a decline in the TUR-P in the past decade^[2]. Especially, photoselective vaporization of the prostate technique (PVP, GreenLight laser prostatectomy) has become an alternative option for BPH/LUTS, after its launch in 1998^[3]. The efficacy and safety of GreenLight PVP is comparable to

Correspondence (İletişim): Mehmet Gökhan Çulha, M.D. Sağlık Bilimleri Üniversitesi, Okmeydanı Eğitim ve Araştırma Hastanesi, Üroloji Kliniği, Turkey

Phone (Telefon): +90 532 562 04 96 **E-mail (E-posta):** gokhan_culha64@hotmail.com

Submitted Date (Başvuru Tarihi): 30.06.2018 **Accepted Date (Kabul Tarihi):** 26.07.2018

Copyright 2019 Haydarpaşa Numune Medical Journal

This is an open access article under the CC BY-NC license (<http://creativecommons.org/licenses/by-nc/4.0/>).



TUR-P and it is superior to TUR-P in terms of the duration of hospital stay and catheterization time [4, 5].

Several studies have demonstrated the benefits of this system in terms of the intraoperative and post-operative course of patients [6, 7]. Since the majority of men with BPH/LUTS are older than 50 years, they may exhibit significant comorbid medical conditions that place them at a high anesthetic risk. Although endoscopic transurethral [8], retropubic [9], perineal [10], or combinations of transurethral and perineal [11] local prostate anesthetic blocks have been suggested for prostatic surgery, they are not commonly adopted by urologists. However, increasing pressure from health-care providers to reduce medical costs has led to shift of research on urological procedures from the hospital to outpatient surgery centers and to adopting local anesthesia wherever possible.

This study aimed to assess the feasibility of using local anesthesia during the 180-Watt GreenLight® PVP procedure among patients who were unsuitable for general or regional anesthesia.

Materials and Methods

This study protocol has been approved by the institutional review board. After obtaining their informed consent, 52 patients who underwent PVP using the 180-Watt GreenLight system (American Medical Systems, Minnetonka, MN, USA) at our institution under periprostatic block between December 2013 and August 2015 have been included into this prospective study. Inclusion criteria: Patients with an indication for BPH operation and patients with comorbidity that would not be able to tolerate general anesthesia were included in the study. All patients completed an International Prostate Symptom Score (IPSS) and underwent uroflowmetric evaluation to determine the maximum flow rate (Qmax). Prostate volumes were measured by transrectal ultrasonography, and prostate-specific antigen (PSA) levels were analyzed.

Before surgery, a 27-gauge needle was inserted into the perineal region and the transperineal tract, leading to the prostate anesthetized with 5 cc of bupivacaine hydrochloride with adrenalin (5 mg/ml) (Marcaïn, AstraZeneca, Cambridge, UK). Subsequently, 20 ml of bupivacaine hydrochloride with adrenalin (5 mg/ml) was injected into the periprostatic area through a 22-gauge Spinocan® needle (B. Braun Medical Inc., PA, USA), which was guided into the plane between the rectum and prostate under the guidance of an index finger inserted in the rectum (Fig. 1). In addition, all patients received 10 cc of intraurethral 2% li-

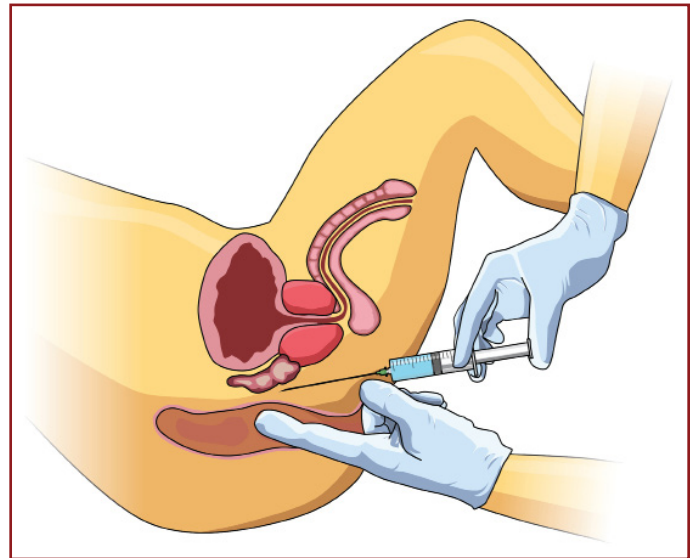


Figure 1. The illustration of the periprostatic block. Prior to surgery, a 27-gauge needle was inserted into the perineal region, and the transperineal tract leading to the prostate anaesthetised with 5 cc of bupivacaine hydrochloride with adrenalin (5 mg/ml). 20 ml of bupivacaine hydrochloride with adrenalin (5 mg/ml) was injected into the periprostatic area and prostate capsule via a 22-gauge Spinocan® needle which was guided into the plane between the rectum and prostate under the guidance of an index finger inserted in the rectum.

docaine gel (Cathejell® BioSyent Pharma Inc., Toronto, ON, Canada). To retain consistency, all periprostatic blocks and PVP operations were performed by the same urologist (OOC). Pain was assessed using the visual analog scale (VAS) [12] immediately after the procedure. 3 months after surgery, patients were reassessed and their IPSS, Qmax, post-void residual, and PSA levels were reanalyzed.

The statistical analyses were carried out using the Statistical Package for the Social Sciences Version 20 (SPSS, Chicago, IL, USA). In addition to the descriptive analyses, paired t-test was used to compare the pre-operative and post-operative variables. Statistical significance level was set as $p < 0.05$.

Results

Mean patient age was 74.88 ± 7.16 (range: 61–90) years and the mean PSA level was 1.74 ± 0.46 (0.65–2.46) ng/dl. Of the patients, 44 (84.62%), 30 (57.69%), 17 (32.69%), and 4 (7.69%) had hypertension, diabetes mellitus, coronary artery disease, and chronic obstructive pulmonary disease, respectively.

The mean operation, hospitalization, and catheterization time of the patients are demonstrated in Table 1. All operations were successfully completed without requiring conversion to general anesthesia. No perioperative complications were recorded. The majority of patients did not

Table 1. The patient characteristics

Characteristics	Mean±SD (Range)
Operation time (min)	57.13±15.32 (30-90)
Hospitalization time (day)	1.37±0.56 (1-3)
Catheterization time (day)	1.25±0.44 (1-2)
VAS score	0.40±1.27 (0-6)

PSA: Prostate-specific antigen; VAS: Visual analog scale.

exhibit any evidence of pain during the procedure (46 of 52 patients had VAS of 0), with mean VAS score of 0.40 ± 1.27 (range: 0–6). However, 38.5% (20/52) of patients described the feeling of urgency and bladder fullness, which were relieved by the continuous low-pressure irrigation technique. In the post-operative 3rd month, PVP resulted in a significant improvement in IPSS (28.6 ± 3.83 vs. 10.73 ± 2.62 , $p<0.0001$) and Qmax (6.88 ± 1.1 vs. 23.87 ± 2.8 , $p<0.0001$). There is not any complication during follow-up.

Discussion

The findings of our study demonstrate that injecting local anesthetic into the periprostatic area and prostate capsule provides sufficient anesthesia for the 180-Watt GreenLight PVP procedure among patients who are unsuitable for general or regional anesthesia. No patient in our study required additional anesthetic interventions, and the majority of the patients reported VAS scores of zero (no pain). The efficacy of the PVP procedure was observed during the 3rd month follow-up when significantly improved IPSS and Qmax values were recorded. None of the patients experienced any post-operative complication during the follow-up period, which confirms the safety of the 180-Watt GreenLight PVP procedure performed under local anesthesia.

To the best of our knowledge, the idea of performing TUR-P under local anesthesia was initially proposed by Moffat, who operated 18 BPH patients under after lidocaine infiltration into the prostate in 1977 [10]. Moffat reported that modest doses of intravenous sedatives were required in a few cases, proving that this method of anesthesia is safe and effective. In 1984, Orandi emphasized the importance of using local anesthesia for urological endoscopic surgeries such as transurethral incision and resection of the prostate, visual urethrotomy, ureteral meatotomy, and resection of primary and recurrent bladder tumors [8]. In a similar study, Issa et al. [13] performed transperineal prostatic block in 43 patients who underwent interstitial laser coagulation of the prostate in either an outpatient or office setting. These authors confirmed that the majority of their patients tolerated the procedure, concluding that perineal

prostatic block is a safe, economical, and effective anesthesia technique for minimally invasive prostate surgeries.

At present, there are three GreenLight laser systems available; 80-Watt, 120-Watt, and 180-Watt. The 180-Watt GreenLight laser systems have greater maximum power output, advanced fiber design, and improved energy-tissue interaction, compared with the previous PVP technologies [5]. Although the feasibility of using local anesthesia during 80-Watt PVP has been previously evaluated [6], there are no such data for 180-Watt PVP. The fibers used in this new system are water cooled, which reduces laser energy in case of overheating [14, 15]. This technology may explain the more favorable outcome of pain recorded for our patients compared with those in previous studies, in which prostatic block was used for transurethral prostate procedures.

This study is not without limitations. First of all, having a comparative group of patients who undergo 180-Watt PVP procedure under general or regional anesthesia would support the reliability of our findings. Similarly, including higher number of patients would significantly improve the quality of our study. Conducting cost-effectiveness analysis to compare the costs of general/regional anesthesia and local anesthesia would confirm the economic benefits of using prostatic block for endoscopic prostate procedures. Prostate volume reduction and PSA reduction have not been evaluated. Finally, conducting the current study in a single center may be considered as another limitation. However, we believe that our results may construct a basis for conducting larger, multicenter, and controlled clinical trials. After all, this anesthesia technique has the potential to reduce the cost, time, operating room resources, and paperwork associated with general and regional anesthesia.

Conclusion

Periprostatic block appears to be a feasible and safe alternative to general or regional anesthesia during PVP using the 180-Watt GreenLight system. This type of anesthesia may be preferred for elderly patients with BPH/LUTS who cannot tolerate general and/or regional anesthesia due to age-related comorbidities.

Peer-review: Externally peer-reviewed.

Authorship Contributions: Concept: Ö.O.Ç.; Design: Ö.O.Ç., A.Y.M.; Data Collection or Processing: Ö.O.Ç.; Analysis or Interpretation: M.G.Ç. H.L.; Literature Search: Ö.O.Ç., M.G.Ç.; Writing: Ö.O.Ç., A.Y.M.

Conflict of Interest: None declared.

Financial Disclosure: The authors declared that this study received no financial support.

References

1. McCarthy JF. Management of prostatic obstructions by endoscopic revision. *New England J Med* 1932;2017:305–12.
2. Yu X, Elliott SP, Wilt TJ, McBean AM. Practice patterns in benign prostatic hyperplasia surgical therapy: the dramatic increase in minimally invasive technologies. *J Urol* 2008;180:241–5.
3. Malek RS, Barrett DM, Kuntzman RS. High-power potassium-titanyl-phosphate (KTP/532) laser vaporization prostatectomy: 24 hours later. *Urology* 1998;51:254–6.
4. Bachmann A, Muir GH, Collins EJ, Choi BB, Tabatabaei S, Reich OM, et al. 180-W XPS GreenLight laser therapy for benign prostate hyperplasia: early safety, efficacy, and perioperative outcome after 201 procedures. *Eur Urol* 2012;61:600–7.
5. Bachmann A, Tubaro A, Barber N, d'Ancona F, Muir G, Witzsch U, et al. A European multicenter randomized noninferiority trial comparing 180 W GreenLight XPS laser vaporization and transurethral resection of the prostate for the treatment of benign prostatic obstruction: 12-month results of the GOLIATH study. *J Urol* 2015;193:570–8.
6. Pedersen JM, Romundstad PR, Mjones JG, Arum CJ. 2-year followup pressure flow studies of prostate photoselective-vaporization using local anesthesia with sedation. *J Urol* 2009;181:1794–9.
7. Thomas JA, Tubaro A, Barber N, d'Ancona F, Muir G, Witzsch U, et al. A Multicenter Randomized Noninferiority Trial Comparing GreenLight-XPS Laser Vaporization of the Prostate and Transurethral Resection of the Prostate for the Treatment of Benign Prostatic Obstruction: Two-yr Outcomes of the GOLIATH Study. *Eur Urol* 2016;69:94–102.
8. Orandi A. Urological endoscopic surgery under local anesthesia: a cost-reducing idea. *J Urol* 1984;132:1146–7.
9. Tabet BG and Levine S. Nerve block in prostate surgery. *J Urol* 1996;156:1659–61.
10. Moffat NA. Transurethral prostatic resections under local anesthesia. *J Urol* 1977;118:607–8.
11. Sinha B, Haikel G, Lange PH, Moon TD, Narayan P. Transurethral resection of the prostate with local anesthesia in 100 patients. *J Urol* 1986;135:719–21.
12. McCormack HM, Horne DJ, Sheather S. Clinical applications of visual analogue scales: a critical review. *Psychol Med* 1988;18:1007–19.
13. Issa MM, Ritenour C, Greenberger M, Hollabaugh R Jr, Steiner M. The prostate anesthetic block for outpatient prostate surgery. *World J Urol* 1998;16:378–83.
14. Brunken C, Munsch M, Tauber S, Schmidt R, Seitz C. The 532-nm 180-W (GreenLight®) laser vaporization of the prostate for the treatment of lower urinary tract symptoms: how durable is the new side-fire fiber with integrated cooling system? *Lasers Med Sci* 2014;29:1307–12.
15. Piotrowicz G, Syryło T, Jedynek R, Zieliński H. Efficacy and Safety of Photoselective Vaporization of the Prostate with 120W 532 nm Laser in Patients with Benign Prostatic Hyperplasia on Anticoagulation or Antiplatelet Therapy: Observations on Long-Term Outcomes. *Photomed Laser Surg* 2018;36:273–83.