

3D Micro-CT Analysis of Void and Gap Formation in Curved Root Canals

Neslihan ŞİMŞEK, Ali KELEŞ, Fuat AHMETOĞLU, Levent AKINCI, Kürşat ER

ABSTRACT

Objective: This study used microcomputed tomography (micro-CT) to compare the volumes of voids and gaps in curved root canals instrumented and filled using various techniques.

Methods: Twenty extracted mandibular first molars with two curved mesial root canals were used. Root canals were instrumented using a self-adjusting file (SAF) or Revo-S file system. For standardization, mesio-buccal canals were instrumented with SAF and mesiolingual canals were instrumented with Revo-S in each root. The canals were divided into four experimental groups (n=10 in each). The canals were then filled via cold lateral compaction (CLC) or a thermoplasticized injectable technique (TT) using gutta-percha and AH Plus root canal sealer. The roots were scanned with a micro-CT, and the volumes of the voids and gaps were calculated using three-dimensional (3D) micro-CT images. Data were analyzed using unpaired t- and Kruskal-Wallis tests. A value of $P < 0.05$ was considered significant.

Results: None of the tested techniques provided void- or gap-free fillings. Nevertheless, the SAF showed more gap formation than the Revo-S, and TT showed higher gap formation in all experimental groups. These differences, however, were not statistically significant ($p > 0.05$).

Conclusion: The SAF and Revo-S rotary file systems yielded comparable results. No statistically significant difference was found between the results of the various instrumentation and filling techniques.

Keywords: Micro-CT, quality of obturation, Revo-S, Self-adjusting file, void, and gap.

HIGHLIGHTS

- A comparative study of root canal filling in extracted teeth using 2 techniques.
- Such fillings with cold lateral compaction (CLC) exhibit less void.
- Sample preparation with Revo-S and then filling CLC shown best results than the others.

INTRODUCTION

The goal of root canal treatment is to eliminate vital or necrotic tissues, bacteria, and toxins, then hermetically seal the root canal (1). However, preparation for this procedure causes superimposed main canals and small anatomical irregularities. Tissue remnants and bacteria can survive especially in side canals, apical regions, and combined areas because the physical properties of the files are insuf-

ficient and there is an inadequate of irrigation solutions in the root canal (2, 3). Even in the main canal, some areas are left untouched (4, 5). Moreover, even a well-shaped root canal may be jeopardized if it is not filled properly (5). Therefore, modifications and techniques have been developed to ensure the proper use of endodontic files. An example of a modified file is the Self-Adjusting File (SAF) (ReDent-Nova, Ra'anana, Israel), which is designed to adapt to the anatomy of the main root canal (6). The SAF is a hollow and flexible file that allows for simultaneous irrigation throughout the shaping process and is used with a reciprocating handpiece. The manufacturer asserts that when an SAF is immersed into a root canal, it adapts to the canal's form longitudinally and in cross-section. The SAF functions with a back-and-forth vibrating motion that, coupled with the abrasive surface of the lattice threads, promotes the uniform removal of dentin (7). The SAF is recommended for use as a single file. Studies have shown that an SAF is better at cleaning, disinfecting, and shaping than traditional files (8). It is unknown whether using an SAF to prepare irregular

Please cite this article as: Şimşek N, Keleş A, Ahmetoğlu F, Akinci L, Er K. 3D Micro-CT analysis of void and gap formation in curved root canals. *Eur Endod J* (2017) 2:22.

From the Department of Endodontics (N.Ş., ✉ dtneslihan@hotmail.com, L.A.), İnönü University School of Dentistry, Malatya, Turkey; Department of Endodontics (A.K.), Ondokuz Mayıs University School of Dentistry, Samsun, Turkey; (F.A.) Private Dental Clinic, Malatya, Turkey; Department of Endodontics (K.E.), Akdeniz University School of Dentistry, Antalya, Turkey.

Received 25 January 2017, revision requested 4 March 2017, last revision received 7 April 2017, accepted 5 May 2017.

Published online: 6 September 2017
DOI 10.5152/eej.2017.17004

or curved root canals allows the filling material to adapt better to irregular canal walls (6, 8-10).

Root canal filling is an essential stage in root canal treatment that aims to seal the root canal to avoid bacterial contamination (7). Epley et al. (5) and Schilder (11) have suggested that the ideal filling material should be adequately adapted to the canal walls and the entire length of the canal fillings should be dense and homogeneous. Over the years, many filling techniques have been introduced to provide better sealing in root canals. The most commonly used filling techniques are cold lateral compaction (CLC) and warm gutta-percha. The CLC technique creates many voids, and the quality of adaptations is poor (12). According to several studies, warm gutta-percha techniques have good penetration and sealing abilities (13, 14). However, a meta-analysis reported no difference in long-term outcomes between the CLC and warm gutta-percha techniques (15).

The volume of voids and gaps in canal fillings should be considered when determining the sufficiency and quality of a filling material or technique. Voids and gaps in canal fillings reduce their ability to be sealed, thus creating conditions for bacterial and fluid microleakage from crown to apex (16, 17). This study used micro-computed tomography (micro-CT) to compare the number of voids and gaps in curved root canals instrumented and filled using different techniques. The null hypothesis was that no difference would be found in the percentage of voids and gaps between canals that were instrumented and filled using different techniques.

METHODS

Sample selection

After approval by the ethics committee (2012/211), 20 freshly extracted human mandibular first molars with curved mesial roots were used in this study. Informed consent was obtained from the patients. Teeth with caries, cracks, or fractures on their root surfaces, internal or external resorption, previous root canal fillings, or cracked or incomplete apices were excluded. The teeth were stored in a 0.1% thymol solution until use.

Distal roots were separated and access cavities were prepared for mesial root canals with a high-speed bur. A composite filling platform was used as a jig to prepare both mesial and buccal faces of the tooth to standardize the radiographs. Pre-operative buccolingual and mesiodistal digital radiographs (Digora; Soredex, Helsinki, Finland) were taken of all samples to verify the canal anatomy. Canal curvatures were measured in both aspects by two calibrated operators using the methods defined by Schneider (18); mean values for each root canal were considered between 17° and 38°. The mean curvature was $26.5^\circ \pm 0.3$ ($P=0.558$).

Root canal length was adjusted with a size 15 K-file (Dentsply Maillefer, Ballaigues, Switzerland) that was presented passively into the canal until its tip was just visible at the major api-

cal foramen. Then the working length (WL) was calculated by subtracting 1 mm from this measurement.

Forty mesial root canals (20 mesiobuccal and 20 mesiolingual) were instrumented with an SAF or Revo-S file system as described below. For standardization, the mesiobuccal canals were instrumented with SAF, and the mesiolingual canals were instrumented with Revo-S.

Root canal instrumentation

SAF instrumentation. Root canals ($n=20$) were instrumented (N.S.) with the SAF system. A size 20 K-file was inserted into the canal's WL following the glide path. The SAF was applied with a back-and-forth manual motion of 5000 vibrations per minute for four minutes. Continuous irrigation with 2.5% sodium hypochlorite (NaOCl) was provided by a VATEA peristaltic pump (ReDent Nova, Israel) at a rate of 4 mL/min. Final irrigation was performed using a syringe filled with 2 mL of 17% ethylenediaminetetraacetic acid (EDTA), followed by 2 mL of 2.5% NaOCl.

Revo-S instrumentation. Root canals ($n=20$) were instrumented (N.S.) with Revo-S nickel titanium rotary files using a torque-controlled motor (VDW Gold; VDW, Munich, Germany) set to 300 rpm and a pecking motion. The torque was adjusted to 2.5 Ncm, and a crown-down approach was adopted. Shaping and cleaning file (SC) number 1 (SC1) was used to instrument the coronal two-thirds of the root canal. SC number 2 (SC2) and universal shaper (SU) files were used in the WL. Instruments were used on only two canals to prevent fractures. Each file was drawn back when resistance was felt and exchanged for a new file. Between each file, 2 mL of 2.5% NaOCl was used for irrigation. The final irrigation was performed with 2 mL of 17% EDTA, followed by 2 mL of 2.5% NaOCl.

Root canal filling

The operator did not know which tooth group was being filled. Before filling, the root canals were dried with paper points and filled with gutta-percha and AH Plus (Dentsply DeTrey, Konstanz, Germany) root canal sealer.

The subgroups were as follows:

SAF system+Cold Lateral Compaction Group (SAF+CLC). Canals ($n=10$) instrumented with an SAF were filled using the CLC technique with a size 25 master cone. The master cone was approved the WL, and when it was withdrawn, a slight "tug back" was felt. Lateral compaction was performed with #25 finger spreaders and #20 accessory gutta-percha cones.

SAF system+Thermoplasticized Injectable Technique Group (SAF+TT). Canals ($n=10$) instrumented with an SAF were filled using the TT technique. About 2 mm of a size 25 master cone were placed on the apical end using a finger plugger (VDW) to prevent overfilling of the apex. A cordless backfill filling system (Dia-Gun; DiaDent, Burnaby, BC, Canada)

was used. The working temperature was adjusted to 180°C. A 23-gauge silver needle was placed within 5 mm of the WL, and the gutta-percha was injected. Gutta-percha was injected until back force was felt, and a finger plugger was used to verify its firmness. The remaining root canal space was backfilled.

Revo-S+Cold Lateral Compaction Group (Revo-S+CLC). Canals (n=10) instrumented with Revo-S were filled as described in the SAF+CLC group.

Revo-S+Thermoplasticized Injectable Technique Group (Revo-S+TT). Canals (n=10) instrumented with Revo-S were filled as described in the SAF+TT group.

Access cavities were filled with a temporary filling material (Cavit G; 3M ESPE, Neuss, Germany) and then stored for seven days at 37°C and 100% humidity to allow the sealer to set fully.

Micro-CT analysis

The filled canals were analyzed (A.K.) using a micro-CT system (SkyScan 1172; Bruker-microCT, Kontich, Belgium). Samples were scanned at 100 kV, 100 µA, and an isotropic pixel size of 13.7 µm with an outcome of 900–1200 transverse cross-sections per sample. Scanning was performed at an 180° rotation with a 2800 ms exposure time, a rotation step of 0.6°, and a frame average of two. X-rays were filtered through an aluminum and copper filter. Cross-sections of the internal structure were reconstructed with NRecon software (v.1.6.3 Bruker-microCT).

An automatic segmentation threshold was used to separate root dentin from the filling and voids using CTA n v.1.12 software (Bruker-microCT). Through this process, an image was obtained from the gray scale for each filling, and the dentin or voids were composed only of black and white pixels. For each slice, regions of interest were chosen to calculate the volume (in mm³) of filling and voids. Polygonal surface representations of dentin, filling, and voids were constructed using CTA n v.1.12 software (Bruker-microCT) and qualitatively assessed using CTVol v.2.2.1 software (Bruker-microCT). It was not possible to partition between voids, gaps, and spreader tracts from the micro-CT images. Thus, after the obturation, all areas within the root canal space that did not contain filling were considered voids. Accessory or lateral canals were not taken into account.

Statistical analysis

Statistical analysis was performed using Statistical Package for Social Sciences software version 17.0 (SPSS Inc.; Chicago, IL, USA). Normality for continuous variables in groups was determined by the Shapiro-Wilk test. Unpaired t- and Kruskal-Wallis tests were used to compare variables between groups. A value of P<0.05 was considered significant.

RESULTS

Means ± standard deviations of the percentage of voids and gaps are summarized in Table 1. Representative 3D recon-

structions of the groups are shown in Figure 1. Images of axial cross-sections in the groups are shown in Figure 2. The results show that all the tested techniques produced voids and gaps. There was no statistically significant difference in the identified void and gap formation after the canals were prepared with SAF (P=0.437) or Revo-S (P=0.186) files. The mean percentages of voids were lower in the Revo-S groups for both

TABLE 1. Mean ±SD of voids and gaps in the root canal-filled teeth.

		CLC	TT	P
		Mean±SD median (min-max)	Mean±SD median (min-max)	
Difference (void)	SAF	3.11±2.06 2.95 (0.63-6.29)	3.81±1.87 3.58 (1.02-6.35)	0.437
	Revo-S	2.78±1.20 2.24 (1.23-4.86)	3.43±0.90 3.45 (2.38-4.90)	
	P	0.663	0.574	

CLC: cold lateral compaction, TT: thermoplasticized injectable technique, SAF: self-adjusting file, SD: standard deviation

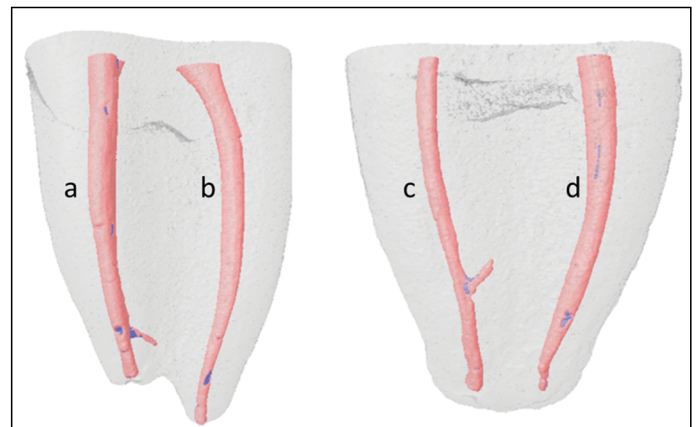


Figure 1. a-d. 3D reconstruction micro-CT scans of the examined root canals. Pink: root canal filling, Blue: voids or gaps. (a) Revo-S+TT technique, (b) SAF+CLC technique, (c) SAF+TT technique and (d) Revo-S+CLC technique

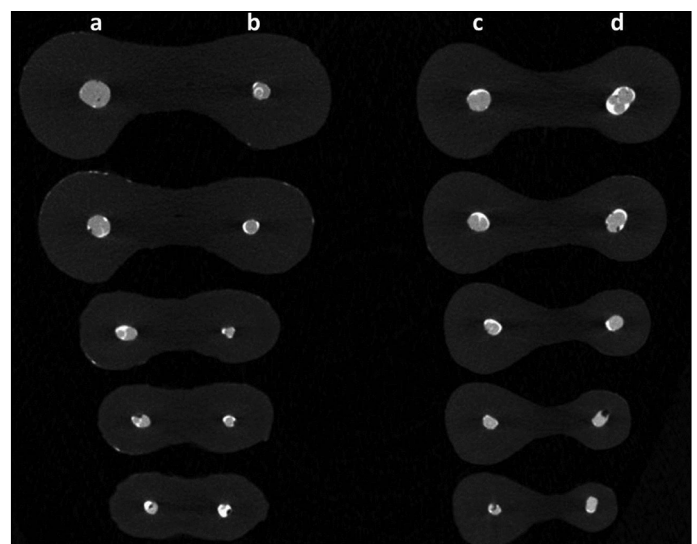


Figure 2. a-d. Images of axial cross-sections in the groups of the examined root canals: (a) Revo-S+TT technique, (b) SAF+CLC technique, (c) SAF+TT technique and (d) Revo-S+CLC technique

filling techniques, but these differences were not significant. When the filling techniques were considered independent of the instrumentation techniques, similar features were found ($P=0.663$ and $P=0.574$). While more voids were found in the TT technique in both instrumentation groups, the differences were not statistically significant.

DISCUSSION

This study aimed to use micro-CT to compare the volume of voids and gaps in curved root canals instrumented using an SAF or Revo-S file system and filled with a CLC or TT technique. Micro-CT's accuracy and reproducibility have been verified previously, and it is accepted as an important research device in various endodontic applications (19). Micro-CT has been used to evaluate root canal anatomy and canal shapes after instrumentation (4, 9, 10, 20). It has also been used to analyze void and gap formation in retreatment studies and root canal fillings, canal sealers, and filling techniques (21-25). Micro-CT imaging is a fast, highly accurate, and nondestructive method for in vitro evaluation of materials (19, 21). Numerous studies have shown the complexity of root canal anatomy. Failures are almost inevitable due to variations among canal sections, in-canal irregularities, and associated curvature diversity (10, 20, 26). Moreover, uninstrumented and unfilled root canal areas can cause complications because they obtain nutrients from the periradicular area or accessory canals (1, 2). Shaping and filling the root canal by preserving curvature is one of the main parameters for analyzing root canal treatment materials or methods. Researchers have indicated that the mesial canals of mandibular molars are complex to work with because most are narrow and curved (10, 27). Therefore, achieving optimal results in terms of antibacterial and shaping ability is difficult. In this study, mesial canals with curvature were selected for their anatomical characteristics to test the file systems and filling techniques.

The results of the tests of normality showed a normal distribution of data that warranted a Shapiro-Wilk test. A significantly low percentage of voids and gaps was found in the samples of all groups. However, none of the tested techniques provided a void-free or gap-free root canal filling. This result is consistent with previous reports (21-24, 26). No significant difference was found between the CLC and TT filling techniques instrumented with the SAF or Revo-S file systems. Therefore, the null hypothesis was accepted.

This study compared two different instrumentation groups. As shown in Figure 1, Revo-S files shaped the root canals wider than the SAF system. Revo-S files are penetrating instruments that are flexible enough to accomplish root canal shaping. According to Celik et al. (28), the Revo-S file system causes minimal canal transportation. The SAF system, however, has a completely different file design and principle of action (i.e., not penetrating or highly flexible), consisting of a metal mesh that can intimately adapt to canal walls and has

a scrubbing effect (6). Metzger et al. (7) showed that SAF files allow better cleaning, shaping, and adaptation of the root canal filling. In this study, the quality of the root canal filling was not affected by differences in taper, curvature, or canal diameter.

The CLC filling technique was used in the present study because it is the most common. Since the development of the warm gutta-percha technique, whether it is superior to CLC has been widely debated (24, 27). Collins et al. (23) showed that both warm vertical and lateral compaction techniques performed better than CLC at replicating defects. This study's results revealed no significant difference in the void and gap formation in canals instrumented with SAF or Revo-S file system. Similarly, the CLC filling technique had an incidence of voids similar to the System B technique in the absence of isthmuses (29). In a recent study, a denser root filling was produced with warm vertical compaction (incremental downpack and incremental backfill) compared to CLC in oval canals (30).

CONCLUSION

This study showed that none of the tested techniques achieved void-free or gap-free fillings. No significant difference in results was found between the selected instrumentation and filling techniques. On the other hand this study focus on only curved root canals so different anatomies such as C-shaped would be different results. Future studies should use micro-CT to focus on void and gap formation in C-shaped root canals. This study's results show that micro-CT 3D imaging can serve as a useful tool to study and compare the quality of root canal fillings.

Ethics Committee Approval: Ethics committee approval was received for this study from Inonu University Malatya Clinical Research Ethics committee (Decision No: 2012/211).

Informed Consent: Written informed consent was obtained from patients who participated in this study.

Peer-review: Externally peer-reviewed.

Author contributions: Concept - N.Ş.; Design - N.Ş., K.E.; Supervision - N.Ş., F.A., L.A.; Resource - N.Ş., L.A.; Materials - N.Ş., F.A., A.K.; Data Collection and/or Processing - N.Ş.; Analysis and/or Interpretation - A.K.; Literature Search - N.Ş.; Writing - N.Ş., K.E., L.A.

Conflict of Interest: No conflict of interest was declared by the authors.

Financial Disclosure: This project was supported by Inonu University, Malatya, Turkey, Scientific Research Projects Unit (201178).

REFERENCES

1. Azim AA, Griggs JA, Huang GT. The Tennessee study: factors affecting treatment outcome and healing time following nonsurgical root canal treatment. *Int Endod J* 2016; 49(1):6-16. [\[CrossRef\]](#)
2. Nair PN, Henry S, Cano V, Vera J. Microbial status of apical root canal system of human mandibular first molars with primary apical periodontitis after "one-visit" endodontic treatment. *Oral Surg Oral Med Oral Pathol Oral Radiol Endod* 2005; 99(2):231-52. [\[CrossRef\]](#)
3. Vera J, Siqueira JF, Ricucci D, Loghin S, Fernandez N, Flores B, et al. One-versus two-visit endodontic treatment of teeth with apical periodontitis: a histobacteriologic study. *J Endod* 2012; 38(8):1040-52. [\[CrossRef\]](#)

4. Peters OA, Schönenberger K, Laib A. Effects of four Ni-Ti preparation techniques on root canal geometry assessed by micro computed tomography. *Int Endod J* 2001; 34(3):221-30. [\[CrossRef\]](#)
5. Epley SR, Fleischman J, Hartwell G, Cicalese C. Completeness of root canal obturations: Epiphany techniques versus gutta-percha techniques. *J Endod* 2006; 32(6):541-4. [\[CrossRef\]](#)
6. Metzger Z, Teperovich E, Zary R, Cohen R, Hof R. The self-adjusting file (SAF). Part 1: respecting the root canal anatomy-a new concept of endodontic files and its implementation. *J Endod* 2010; 36(4):679-90. [\[CrossRef\]](#)
7. Metzger Z, Zary R, Cohen R, Teperovich E, Paqué F. The quality of root canal preparation and root canal obturation in canals treated with rotary versus self-adjusting files: a three-dimensional micro-computed tomographic study. *J Endod* 2010; 36(9):1569-73. [\[CrossRef\]](#)
8. Siqueira JF Jr, Alves FR, Almeida BM, de Oliveira JC, Roças IN. Ability of chemomechanical preparation with either rotary instruments or self-adjusting file to disinfect oval-shaped root canals. *J Endod* 2010; 36(11):1860-5. [\[CrossRef\]](#)
9. De-Deus G, Souza EM, Barino B, Maia J, Zamolyi RQ, Reis C, et al. The self-adjusting file optimizes debridement quality in oval-shaped root canals. *J Endod* 2011; 37(5):701-5. [\[CrossRef\]](#)
10. Siqueira JF, Alves FR, Versiani MA, Roca IN, Almeida BM, Neves MA, et al. Correlative bacteriologic and micro-computed tomographic analysis of mandibular molar mesial canals prepared by self-adjusting file, reciproc, and twisted file systems. *J Endod* 2013; 39(8):1044-50. [\[CrossRef\]](#)
11. Schilder H. Filling root canals in three dimensions. *Dent Clin North Am* 1967: 723-44.
12. Kandemir Demirci G, Çalıřkan MK. A prospective randomized comparative study of cold lateral condensation versus core/gutta-percha in teeth with periapical lesions. *J Endod* 2016; 42(2):206-10. [\[CrossRef\]](#)
13. Wu MK, Wesselink PR. A primary observation on the preparation and obturation of oval canals. *Int Endod J* 2001; 34(2):137-41. [\[CrossRef\]](#)
14. Venturi M, Breschi L. Evaluation of apical filling after warm vertical-gutta-percha compaction using different procedures. *J Endod* 2004; 30(6):436-40. [\[CrossRef\]](#)
15. Peng L, Ye L, Tan H, Zhou X. Outcome of root canal obturation by warm gutta-percha versus cold lateral condensation: a meta-analysis. *J Endod* 2007; 33(2):106-9. [\[CrossRef\]](#)
16. Wu MK, van der Sluis LW, Ardila CN, Wesselink PR. Fluid movement along the coronal two-thirds of root fillings placed by three different gutta-percha techniques. *Int Endod J* 2003; 36(8):533-40. [\[CrossRef\]](#)
17. Gandolfi MG, Parrilli AP, Fini M, Prati C, Dummer PM. 3D micro-CT analysis of the interface voids associated with Thermafil root fillings used with AH Plus or a flowable MTA sealer. *Int Endod J* 2013; 46(3):253-63. [\[CrossRef\]](#)
18. Schneider SW. A comparison of canal preparations in straight and curved root canals. *Oral Surg Oral Med Oral Pathol* 1971; 32(2):271-5. [\[CrossRef\]](#)
19. Jung M, Lommel D, Klimek J. The imaging of root canal obturation using micro-CT. *Int Endod J* 2005; 38(9):617-26. [\[CrossRef\]](#)
20. Liu N, Li X, Liu N, Ye L, An J, Nie X, et al. A micro-computed tomography study of the root canal morphology of the mandibular first premolar in a population from southwestern China. *Clin Oral Investig* 2013; 17(3):999-1007. [\[CrossRef\]](#)
21. Hammad M, Qualtrough A, Silikas N. Evaluation of root canal obturation: a three-dimensional in vitro study. *J Endod* 2009; 35(4):541-4. [\[CrossRef\]](#)
22. El-Ma'a'ita AM, Qualtrough AJ, Watts DC. A micro-computed tomography evaluation of mineral trioxide aggregate root canal fillings. *J Endod* 2012; 38(5):670-2. [\[CrossRef\]](#)
23. Collins J, Walker MP, Kulild J, Lee C. A comparison of three gutta-percha obturation techniques to replicate canal irregularities. *J Endod* 2006; 32(8):762-5. [\[CrossRef\]](#)
24. Herbert J, Bruder M, Braunsteiner J, Altenburger MJ, Wrbas KT. Apical quality and adaptation of Resilon, EndoREZ, and Guttaflow root canal fillings in combination with a noncompaction technique. *J Endod* 2009; 35(2):261-4. [\[CrossRef\]](#)
25. Keles A, Alcin H, Kamalak A, Versiani MA. Oval-shaped canal retreatment with self-adjusting file: a micro-computed tomography study. *Clin Oral Investig* 2014; 18(4):1147-53. [\[CrossRef\]](#)
26. Marciano MA, Ordinola-Zapata R, Cunha TV, Duarte MA, Cavenago BC, Garcia RB, et al. Analysis of four gutta-percha techniques used to fill mesial root canals of mandibular molars. *Int Endod J* 2011; 44(4):321-9. [\[CrossRef\]](#)
27. Harris SP, Bowles WR, Fok A, McClanahan SB. An anatomic investigation of the mandibular first molar using micro-computed tomography. *J Endod* 2013; 39(11):1374-8. [\[CrossRef\]](#)
28. Celik D, Tasdemir T, Er K. Comparative study of 6 rotary nickel-titanium systems and hand instrumentation for root canal preparation in severely curved root canals of extracted teeth. *J Endod* 2013; 39(2):278-82. [\[CrossRef\]](#)
29. Keçeci AD, Unal GC, Sen BH. Comparison of cold lateral compaction and continuous wave of obturation techniques following manual or rotary instrumentation. *Int Endod J* 2005; 38(6):381-8. [\[CrossRef\]](#)
30. Keles A, Alcin H, Kamalak A, Versiani MA. Micro-CT evaluation of root-filling quality in oval-shaped canals. *Int Endod J* 2014; 47(12):1177-84. [\[CrossRef\]](#)