

Research Article

Schematization of the Katilmis Technique for Vocal Cord Lateralization: How Is It Done?

Riza Dundar,¹ Yilmaz Ozkul,² Murat Songu,² Erkan Kulduk,³ Huseyin Katilmis⁴

¹Department of Otorhinolaryngology, Acibadem Mehmet Ali Aydinlar University, Vocational School of Health Sciences Eskisehir Hospital, Istanbul, Turkey

²Department of Otorhinolaryngology, Izmir Training and Research Hospital, Izmir, Turkey

³Department of Otorhinolaryngology, Kiziltepe State Hospital, Mardin, Turkey

⁴Department of Otorhinolaryngology, Efes ENT Hospital, Izmir, Turkey

Abstract

Objectives: The aim of this study was to demonstrate a technique for vocal and ventricular fold lateralization in patients with bilateral vocal fold immobility (BVFI) using crossing sutures with the thyroplasty window technique.

Methods: A total of 76 patients diagnosed with BVFI were operated on using this previously described technique involving vocal and ventricular fold lateralization using crossing sutures with a thyroplasty window between February 2006 and April 2016.

Results: All of the patients displayed marked symptomatic improvement in dyspnea. No patient experienced aspiration postoperatively or during follow-up.

Conclusion: Vocal and ventricular fold lateralization using crossing sutures with the thyroplasty window technique is an effective procedure in the rehabilitation of BVFI.

Keywords: Bilateral vocal fold paralysis, suture laterofixation, vocal fold

Bilateral vocal cord immobility (BVFI) is a serious symptom progressing with dyspnea and inspiratory stridor. BVFI can be seen after neck and mediastinal surgery, and it can also be observed in neurological diseases.^[1, 2] The most important finding of BVFI is dyspnea, which generally does not lead to marked worsening of voice quality.^[3] Surgical procedures have been always prioritized in the treatment of patients with BVFI. In the treatment of BVFI, three surgical procedures have been considered. The first one is tracheostomy via bypassing larynx, the second one is dilatation of the laryngeal lumen (a static procedure), and the third one is restoration of the vocal cord innervation (a dynamic procedure). Although the first two procedures are frequently used, they do not improve voice quality. Dynamic proce-

dures completely preserve laryngeal anatomy and ensure re-innervation, with resultant marked improvement in voice quality; however, these methods are still experimental.^[4]

Firstly, Ejnell and Tissel described laterofixation of vocal cords. This minimally invasive, static procedure is reversible and relatively simple and does not require postoperative tracheotomy.^[5] Although a satisfactory laryngeal opening is achieved after laterofixation, with time as a result of loosening of sutures, rupture of tissues and prolapsus of laryngeal tissues and especially vocal bands into laryngeal lumen restenosis can occur. In our previous study, the technique used was vocal and ventricular fold lateralization using crossing sutures with thyroplasty window in patients with BVFI.

Address for correspondence: Riza Dundar, MD. Kulak Burun Bogaz Bolumu, Acibadem Mehmet Ali Aydinlar Universitesi, Saglik Yuksekoku Meslek Yuksekoku, Eskisehir Hastanesi, Istanbul, Turkey

Phone: +90 530 419 92 25 **E-mail:** dundarkbb2@gmail.com

Submitted Date: December 14, 2017 **Accepted Date:** January 05, 2018 **Available Online Date:** February 05, 2018

©Copyright 2018 by Eurasian Journal of Medicine and Oncology - Available online at www.ejmo.org



Surgical Technique

All operations were performed under general anesthesia, with endotracheal intubation. Key points in the application of the lateralization technique were the excision of a rectangular cartilage from the lamina of the thyroid cartilage (as described in type 1 thyroplasty) and the cross-stitching of the lateralization sutures as previously described. The steps of the technique were as follows. A horizontal skin incision was made, extending 4 cm laterally from the midline on the side of lateralization and 1 cm laterally on the other side (Fig. 1a).

The strap muscles were retracted laterally and the thyrohyoid muscle was incised to expose the oblique line, thyroid notch, and lamina of the thyroid cartilage on the lateralization side. The posterior part of the lamina was held with a hook, while the thyroid cartilage was retracted to the opposite side. The piece of cartilage to be excised from the lamina of the thyroid cartilage was measured and marked (Fig. 1b). The dimensions of the excised piece of cartilage were approximately 0.7 cm in height and 1.5 cm in length in males and 0.6 cm in height and 1.3 cm in length in females. The excision site was adjusted so that it

was equivalent to the level of vocal and ventricular folds. The inferior border was approximately 0.5 cm superior to the inferior margin of the thyroid cartilage, and the anterior border was approximately 0.5 cm posterior to the midline of the thyroid cartilage. The posterior border extended maximally to the oblique line. The piece of cartilage was excised with the aid of a drill and an elevator, sparing the inner perichondrium. Four holes [(1) anteroinferior, (2) posterosuperior, (3) anterosuperior, and (4) posteroinferior] were drilled superior and inferior to the defect (Fig. 2). To maintain the cross-stitching anterior of the vocal process, the anterior holes 1 and 3 were drilled 0.5 cm posterior to the anterior border of the defect, and the posterior holes 2 and 4 were drilled just superior and inferior to the posterior corners of the defect, just anterior to the oblique line. The endolaryngeal projections of the superior and inferior holes were adjusted superior and inferior to the ventricular fold, respectively. After endoscopic exposure of the larynx (Fig. 1d), the first suture (1-0 prolene) was inserted into hole 1 from the outer to inner larynx by the guidance of an 18-G branule, and the suture was pulled out of the mouth (Fig. 1e). Then, a Kirschner wire (0.7 mm diameter) was inserted into hole 2 from the outer to inner larynx and pulled

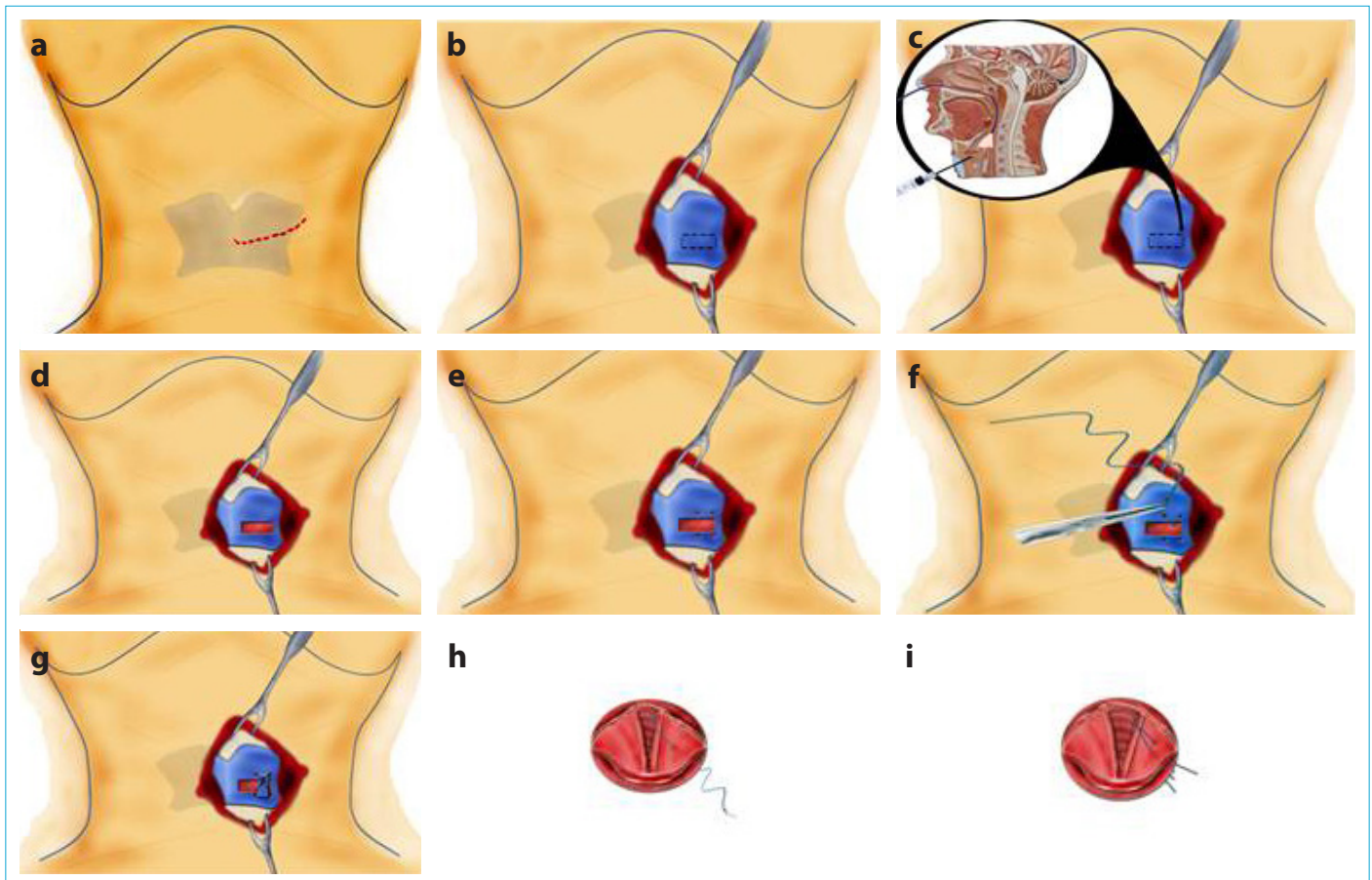


Figure 1. Steps of the surgical technique.

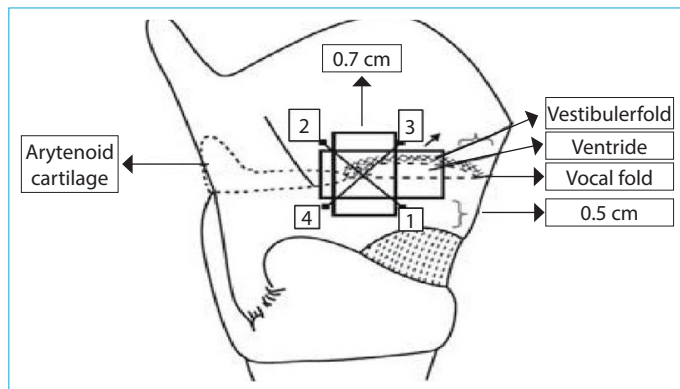


Figure 2. Diagrammatic view of a defect on the lamina of thyroid cartilage in a male larynx, and the cross-stitching of sutures outside the larynx.

out of the mouth. The free end of the Kirschner wire was bent back on itself to form a hoop, which allowed us to tie the suture thread. Then the suture was taken out from the endolarynx and pulled through hole 2 by the guidance of the Kirschner wire (Fig. 1f). The second suture (1-0 prolene) was inserted into hole 3 and pulled through hole 4, as described above. The excised cartilage was placed vertically on the defect, and the sutures were tied diagonally over this cartilage (Fig. 1g). The diagonal sutures were endoscopically controlled to cross each other just anterior to the vocal process (Figs. 1h, i).

Evaluation Parameters:

Medical Research Council (MRC) Dyspnea Scale:

Patients were asked about their perceived breathlessness and were classified into MRC dyspnea grades considering how they perceived their disability pre- and postoperatively. The MRC dyspnea scale is a questionnaire that consists of five statements respecting perceived breathlessness: grade 1, "I only get breathless with strenuous exercise"; grade 2, "I get shortness of breath when hurrying on the level or up a slight hill"; grade 3, "I walk slower than people of the same age on the level due to breathlessness or have to stop for breath when walking at my own pace on the level"; grade 4, "I stop for breath after walking 100 yards or after a few minutes on the level"; grade 5, "I am too breathless to leave the house." Patients selected the grade suitable for them.^[6]

Global Voice Quality:

Each patient was asked to give a rating of his or her voice using a five-point Likert-style scale of global voice quality (1=bad, 2=rather bad, 3=moderate, 4=rather good, 5=good) in the pre- and postoperative periods.^[7]

Secretion Severity Scale:

Patients were evaluated according to Secretion Severity Scale.^[8] The scale score ranged from 0 (normal) to 3 (pooling in laryngeal vestibule consistently). Level 1 indicated secretions evident in the vallecular space or pyriform sinuses. Any change from a level 1 rating to a level 3 rating over the observation period resulted in a classification of level 2 (pooling in laryngeal vestibule transiently).

Cases

Of 76 patients, two were lost to follow-up and one died due to breast cancer. All patients had at least one-year follow-up after surgical intervention. All patients reported marked symptomatic improvement in dyspnea after the procedure with the MRC dyspnea grade.

The voice quality of the patients worsened as expected; however, this difference did not reach a significant level. Although voice therapy was recommended for all patients in our routine postoperative follow-up, all patients were successfully extubated at the end of the procedure.

Transient microaspiration was noted in nine patients, which was resolved in one or two days. Aspiration in the postoperative period was level 1 according to the Secretion Severity Scale in five patients and level 2 in four patients. All patients were graded as level 0 on the second postoperative day. Postoperatively, swallowing on the side of the laterofixation was painful for all patients. However, this ceased after a week. No signs of inflammation or granulation were observed in either the larynx or the neck wound.

Discussion

In the early 1900s, the only treatment option for BVFI was tracheostomy. In 1922, Jackson described the unilateral excision of the true and false vocal folds, which led to improved breathing and the possibility to decannulate some patients.^[9] The drawback of the procedure was the very weak voice. Ten years later, Hoover et al. tried "submucous resection" of the vocal folds, but it led to scarring and vocal stenosis, with severe dyspnea.^[10] The first major breakthrough was in 1939 when King, an orthopedic surgeon, introduced a function-restoring procedure that consisted of suturing the arytenoid cartilage to the omohyoid muscle.^[11] He suggested that the improved breathing was related to a return of function of the vocal fold because of the contraction of the omohyoid muscle during inspiration. However, it was later found that the arytenoid became fixed in the lateral position. Kelly modified King's technique by excising the arytenoid through a window in the thyroid cartilage and by placing a suture to lateralize the vocal fold.^[12] Ejnell et al.^[13] reported a new surgical technique for BVFI

in 1984. Their method used laterofixation of the vocal fold, with a thread looped around the fold. This procedure was simple, less invasive than previous methods, and required no tracheotomy. In addition, it is a reversible method.

In our prior clinical experience with endoscopic suture lateralization and other traditional techniques, we observed that a collapse of endolaryngeal surrounding soft tissues, leading to additional operations, occurred during long-term follow-up. This phenomenon is consistent with Bernoulli's pressure principle. According to Guerrier, one cause of arytenoidectomy failure is aspiration of the opposite fold toward the arytenoidectomized fold during inspiration. Therefore, to widen the glottic space with ventriculoplasty, he aimed to lateralize the ventricular and vocal folds together.^[14] However, because muscle tonus of the ventricular folds is anatomically less than that of the vocal folds, prolapse of the ventricular folds to the endolarynx may occur. We acknowledged the effectiveness and reliability of laterofixation techniques in treating BVFI in our clinic. Furthermore, beginning in 2006, we performed our modified laterofixation technique, which has been a standard choice for our surgical interventions.^[15] In 2012, we reported long-term results of 17 patients treated with this technique.^[16] In this technique, laterofixation of the vocal and ventricular folds could sufficiently relieve airway obstruction, without damaging the laryngeal soft tissues. Another goal of our technique was to accomplish permanent results. The free borders of the defect created on the lamina of thyroid cartilage gain elasticity during inward and outward movements, owing to the partial loss of integrity and consequent firmness of the lamina. The vestibular and vocal folds are fixed to the vertically placed excised cartilage with the intent of absorbing a significant portion of the vacuum effect on lateralized soft tissues with an elastic response, instead of creating a net vectoral force opposite to the negative airflow pressure within the lumen. Our technique avoids the need for a tracheotomy in cases of bilateral abductor vocal fold immobility. In two of our cases, acute lateralization was performed and recovery of fold mobility was monitored without the need for tracheotomy. In cases with recovery of vocal fold movements, the sutures can be removed through a 2-cm incision in the neck. With this new technique, a tracheotomy was not needed in any of our cases during lateralization or after surgery. The patients who had undergone emergency tracheotomy before the procedure were also decannulated successfully in our study. Patients reported marked symptomatic improvement in dyspnea, without significant deterioration of voice quality. Aspiration in the postoperative period was level 1 according to the Secretion Severity Scale in five patients and level 2 in two patients. All patients were graded as level 0 on the

second postoperative day. With respect to its advantages, our technique (1) eliminates the need for tracheotomy, (2) does not require excision of anatomic structures and is reversible, (3) affords a better quality of life, (4) is applicable with or without tracheotomy, (5) enables lateralization of the tissues surrounding the rima as required, (6) avoids repeated operations, (7) allows reasonable phonation and sufficient respiration with a unilateral procedure, and (8) protects from possible tracheotomy complications. However, the technique has certain disadvantages such as the necessity of a 4–5 cm-long skin incision in the neck and the difficulties associated with approaching the vocal folds from outside the larynx.

Conclusion

Based on our long-term results, it can be concluded that vocal and ventricular fold lateralization using crossing sutures with the thyroplasty window technique is an effective and durable procedure in the rehabilitation of BVFI.

Disclosures

Ethics Committee Approval: The study was approved by the Local Ethics Committee.

Peer-review: Externally peer-reviewed.

Conflict of Interest: None declared.

Authorship contributions: Concept – H.K.; Design – R.D.; Supervision – H.K.; Materials – R.D., Y.O.; Data collection &/or processing – R.D., Y.O., E.K.; Analysis and/or interpretation – R.D., M.S.; Literature search – R.D., E.K.; Writing – R.D., M.S.; Critical review – M.S., H.K.

References

1. Shvero J, Koren R, Stern Y, Segal K, Feinmesser R, Hadar T. Laser posterior ventriculocordectomy with partial arytenoidectomy for the treatment of bilateral vocal fold immobility. *J Laryngol Otol* 2003;117:540–3. [\[CrossRef\]](#)
2. Laccourreye O, Paz Escovar MI, Gerhardt J, Hans S, Biacabe B, Brasnu D. CO2 laser endoscopic posterior partial transverse cordotomy for bilateral paralysis of the vocal fold. *Laryngoscope* 1999;109:415–8. [\[CrossRef\]](#)
3. Goding G. Bilateral vocal fold immobility. In: Sulica L, Blitzer A, editors. *Vocal Fold Paralysis*. Heidelberg: Springer; 2006. p. 237–48.
4. Zeale DL, Billante CR, Courey MS, Netterville JL, Paniello RC, Sanders I, et al. Reanimation of the paralyzed human larynx with an implantable electrical stimulation device. *Laryngoscope* 2003;113:1149–56. [\[CrossRef\]](#)
5. Ejnell H, Tisell LE. Acute temporary laterofixation for treatment of bilateral vocal cord paralyses after surgery for advanced thyroid carcinoma. *World J Surg* 1993;17:277–81. [\[CrossRef\]](#)
6. Bestall JC, Paul EA, Garrod R, Garnham R, Jones PW, Wedzicha JA. Usefulness of the Medical Research Council (MRC) dyspnoea scale as a measure of disability in patients with chronic

- obstructive pulmonary disease. *Thorax* 1999;54:581–6. [\[CrossRef\]](#)
7. Kreiman J, Gerratt BR. Validity of rating scale measures of voice quality. *J Acoust Soc Am* 1998;104:1598–608. [\[CrossRef\]](#)
 8. Murray J, Langmore SE, Ginsberg S, Dostie A. The significance of accumulated oropharyngeal secretions and swallowing frequency in predicting aspiration. *Dysphagia* 1996;11:99–103.
 9. Jackson C. Ventriculocordectomy: a new operation for the cure of goitrous paralytic laryngeal stenosis. *Arch Surg* 1922;4:257–74. [\[CrossRef\]](#)
 10. Hoover WB. Bilateral abductor paralysis, operative treatment of submucous resection of the vocal cord. *Arch Otolaryngol* 1932;15:337–55.
 11. King B.T. A new and function-restoring operation for bilateral abductor cord paralysis. *JAMA* 1939;112:814–23. [\[CrossRef\]](#)
 12. Kelly JD. Surgical treatment of bilateral paralysis of the abductor muscles. *Arch Otolaryngol Head Neck Surg* 1941;33:293–304.
 13. Ejnell H, Mansson I, Hallén O, Bake B, Stenborg R, Lindström J. A simple operation for bilateral vocal cord paralysis. *Laryngoscope* 1984;94:954–8. [\[CrossRef\]](#)
 14. Guerrier Y. *Traité de technique chirurgicale orl et cervico-faciale*. Elsevier/Masson; 1986. p. 381.
 15. Katılmış H, Oztürkcan S, Başoğlu S, Aslan H, Ilknur AE, Erdoğan NK, et al. New technique for the treatment of bilateral vocal cord paralysis: Vocal and ventricular fold lateralization using crossing sutures with thyroplasty technique. *Acta Otolaryngol* 2011;131:303–9. [\[CrossRef\]](#)
 16. Songu M, Aslan H, Denizoglu I, Ozkul Y, Basoglu S, Ates D, et al. Vocal and ventricular fold lateralization using crossing sutures with the thyroplasty window technique for bilateral vocal fold immobility: long-term results. *Acta Otolaryngol* 2013;133:1201–6. [\[CrossRef\]](#)